COUNTWAY LIBRARY
HC 6DZ2

BOSTON
MEDICAL LIBRARY
8 THE FENWAY

Digitized by the Internet Archive
in 2026

https://archive.org/details/anatomical-record_april-july-1937_68

THE
ANATOMICAL RECORD

MANAGING EDITOR

EDWARD A. BOYDEN
University of Minnesota

ASSOCIATE EDITORS

CHARLES H. DANFORTH
Stanford University

B. C. H. HARVEY
The University of Chicago

PHILIP E. SMITH
Columbia University

HAROLD L. WEATHERFORD
Harvard University

VOLUME 68 AND SUPPLEMENT

APRIL, MAY, JUNE, JULY, 1937

THE WISTAR INSTITUTE OF ANATOMY AND BIOLOGY
PHILADELPHIA, PA.

28848

BOSTON MEDICAL
JUL 30 1937
LIBRARY

CATALOGUED
JUL 30 1937
E. N. C.

CONTENTS

No. 1 APRIL, 1937

JANE M. OPPENHEIMER. The normal stages of Fundulus heteroclitus. One text figure and three plates (thirty-three figures) 1

R. A. SCHWEGLER, JR. AND E. A. BOYDEN. The development of the pars intestinalis of the common bile duct in the human fetus, with special reference to the origin of the ampulla of Vater and the sphincter of Oddi. II. The early development of the musculus proprius. Five text figures and four plates (twelve figures) 17

LAWRENCE R. WHARTON. Studies on the innervation of the reproductive organs of Macacus rhesus. Seven figures 43

KENDALL B. CORBIN AND ERNEST D. GARDNER. Decrease in number of myelinated fibers in human spinal roots with age. Six figures 63

T. H. BAST. The utriculo-endolymphatic valve and duct and its relation to the endolymphatic and saccular ducts in man and guinea pig. Nine text figures and two plates (seven figures) 75

WARREN O. NELSON. Endometrial and myometrial changes including fibromyomatous nodules, induced in the uterus of the guinea pig by the prolonged administration of oestrogenic hormone. Four figures 99

CORA HESSELBERG AND LEO LOEB. The structure of the secreting and retrogressing mammary gland in the guinea pig 103

A. GIROUD AND C. P. LEBLOND. Histological study of renal elimination of ascorbic acid. Six figures 113

RALPH W. PHILLIPS AND FREDERIC N. ANDREWS. The speed of travel of ram spermatozoa 127

AMERICAN ASSOCIATION OF ANATOMISTS. Fifty-third session: Proceedings, officers and list of members ..... Sup. 1

No. 2 MAY, 1937

CLAY B. FREUDENBERGER AND FRED W. CLAUSEN. The effect of continued theelin injections on the body growth and organ weights of young female rats. One figure 133

ALLAN L. GRAFFLIN. The structure of the nephron in the sculpin, Myoxocephalus octodecimspinosus. Three text figures and two plates (twenty-six figures) 145

J. L. BREMER. Two reconstructions explaining the development of the veins of the liver. Two figures 165

NORMAN D. SCHOFIELD AND RAYMOND F. BLOUNT. Changes in the alimentary canal of urodele larvae associated with an excess or absence of hypophyseal tissue. Eight figures 169

R. A. SCHWEGLER, JR. AND E. A. BOYDEN. The development of the pars intestinalis of the common bile duct in the human fetus, with special reference to the origin of the ampulla of Vater and the sphincter of Oddi. III. The composition of the musculus proprius. Nine text figures and four plates (twelve figures) 193

RICHARD E. SCAMMON. Two simple nomographs for estimating the age and some of the major external dimensions of the human fetus. Two figures 221

A. KIRSCHBAUM AND HAL DOWNEY. A comparison of some of the methods used in studies of hemopoietic tissues. Two plates (six figures) 227

J. M. WOLFE. Comparative action of injections of oestrin and a combination of oestrin and anterior pituitary-like substance on the anterior hypophysis 237

OLIVE L. LEONARD AND SAMUEL L. LEONARD. Failure of thyroidectomy to influence the follicular components of the immature rat ovary 249

H. E. JORDAN. The relation of lymphoid nodules to blood production in the bone marrow of the turkey. One plate (four figures) 253

No. 3 JUNE, 1937

Dr. M. J. Greenman ..... *Frontispiece*

Henry H. Donaldson. *Editorial.* Milton Jay Greenman 263

Alexander Petrunkevitch. On differential staining. Four figures 267

Emelia M. Vicari. Observations on the nature of the parafollicular cells in the thyroid gland of the dog. A preliminary note. One plate (five figures) 281

Allan L. Grafflin. The structure of the nephron in fishes. Representative types of nephron encountered; the problem of homologies among the differentiated portions of the proximal convoluted segment. Six text figures and one plate (four figures) 287

Melvin Crawford Godwin. The development of the parathyroids in the dog with emphasis upon the origin of accessory glands. Three plates (twenty-two figures) ... 305

Reino H. Puumala. Morphologic comparison of the parietal and the visceral peritoneal epithelium in fetus and adult. Five figures 327

W. U. Gardner. Hypertrophy of interstitial cells in the testes of mice receiving estrogenic hormones. One text figure and one plate (four figures) 339

Thomas E. Hunt. The development of gut and its derivatives from the mesectoderm and mesentoderm of early chick blastoderms. Three plates (eleven figures) 349

C. M. Jackson. Recovery of rats upon refeeding after prolonged suppression of growth by underfeeding. One figure 371

George C. Whitney. A note on the definition of Glisson's capsule 383

James C. Wren. A case of retrocaval ureter 389

No. 4 JULY, 1937

A. J. Dalton. The functional differentiation of the hepatic cells of the chick embryo. One text figure and two plates (five figures) 393

Fred A. Mettler and Cecilia C. Mettler. Description of the brain of a human cyclopian monster. One figure 411

C. A. Swinyard. The innervation of the suprarenal glands. One plate (four figures) ... 417

Wayne J. Atwell. Functional transplants of the primordium of the epithelial hypophysis in Amphibia. One text figure and two plates (sixteen figures) 431

Thomas E. Hunt. The origin of entodermal cells from the primitive streak of the chick embryo. One plate (four figures) 449

C. H. Danforth. Pigment cells in heterogenous feathers. Two figures 461

Homer B. Latimer. The weights and linear measurements of the digestive system of the adult cat 469

Samuel R. M. Reynolds and Willard M. Allen. The effect of progestin on the growth response of the uterus to chronic distention. Two figures 481

Arthur W. Pollister and John A. Moore. Tables for the normal development of Rana sylvatica 489

Samuel L. Leonard and James B. Hamilton. Comparison and rate of testicular degeneration in rats after cryptorchidism and hypophysectomy. One figure 497

NEW BOOKS AND PUBLICATIONS

PHYSIOLOGICAL HYGIENE, by Cleveland Pendleton Hickman. 1937. Size, $5\frac{3}{4} \times 8\frac{1}{4}$ inches. Pages xxvi + 493. 90 illustrations. Glossary. Bibliography. Index. Cloth. Price, $3.25. Prentice-Hall, Inc., New York.

In presenting the subject of hygiene, an attempt has been made in this volume to give college students a genuine understanding of human physiology and to stimulate their interest in working out for themselves solutions to new problems. Rules for health behavior are taught in relation to basic factors and underlying principles on which good health rests. The author believes that students are vitally interested in themselves, their life processes, and the proper functioning of their bodies. With this in mind he has written an interesting and readable textbook in a form which is not too technical nor yet too elementary.

A LABORATORY HANDBOOK FOR DIETETICS, by Mary Schwartz Rose. Fourth edition. 1937. Size, $5\frac{3}{4} \times 8\frac{1}{2}$ inches. Pages xi + 322. Bibliography. Index. Fabrikoid. Price, $3.00. The Macmillan Company, New York.

The purpose of this book as set forth in the preface is "to explain the problems involved in the calculation of food values and food requirements, and the construction of dietaries, and to furnish tables which will minimize the labor involved in such work." The fourth edition has been revised to include recent results of research in nutrition. Far more stress is placed on the importance of minerals and vitamins than was the case in earlier editions. The text is divided into three sections. Part I, on food values and food requirements, treats of the composition of food materials, the functions of food, age and occupational differences in food requirements, together with instructions for selection of foods to make up adequate diets. Part II presents a series of problems in dietary calculation which explain in detail each step in the study of food values. Part III is made up of reference tables. It includes height-weight-age charts; nutritive, calorie and vitamin values of foods; conversion tables and many other data. An appendix contains a bibliography and a description of equipment necessary to a dietetics laboratory.

THE NORMAL STAGES OF FUNDULUS HETEROCLITUS

JANE M. OPPENHEIMER [1]
Osborn Zoölogical Laboratory, Yale University

ONE TEXT FIGURE AND THREE PLATES (THIRTY-THREE FIGURES)

The embryologist, while fully aware that development is continuous, finds it convenient to analyze the process in stages in order to describe intelligibly the material with which he is dealing. Accordingly, the normal stages of developing Fundulus heteroclitus have been worked out, to facilitate the work of students who may find Fundulus eggs favorable material for morphological or experimental investigation.

The very nature of the embryogenic processes renders it impossible to choose criteria absolutely valid for subdividing the total course of development. The chronological age of a teleostean embryo, expressed in hours or days, does not represent its actual age, which varies according to conditions of temperature, oxygen supply, etc. The precise state of development of older embryos cannot be expressed in somite numbers, since this varies, when compared with the differentiation of other organ systems, in embryos maintained under different conditions, and probably in embryos differing in genetic constitution. Perhaps the most accurate measuring rod for development might be derived from studying the gradual differentiation of a single organ system in eggs maintained in a rigorously controlled environment. This method, however, would be of little practical advantage to the experimental embryologist, because many of the changes would be difficult to observe by gross examination, and because the nature of the experiments often demands a variance of the environmental factors.

[1] Sarah Berliner Research Fellow of the American Association of University Women.

THE ANATOMICAL RECORD, VOL. 68, NO. 1 AND SUPPLEMENT NO. 1
APRIL, 1937

The most favorable method, for the purpose of the experimental embryologist, seems to be the distinction of stages by criteria easily visible without histological study, varying in their nature at different stages of development; the stages characterized by such specified criteria must be of sufficient duration that minor differences between various embryos of the same stage may be minimized. In the scheme for Fundulus, for instance, the stage during which the cavity appears in the nervous system has been numbered 19; embryos developing the cavity may have between 14 and 20 somites. Nervous system and somites are not the only organ systems to vary in their chronological relationships at this stage; the sense organs do so also. The ectodermal thickenings for lens and olfactory pit may appear early or late in the stage. By the time, however, that the embryo has completed this stage, the lens and olfactory pit will invariably be formed, and the somites will number about nineteen or twenty.

The development of the Fundulus heteroclitus eggs, from before fertilization until the time the yolk has been completely absorbed, has been arbitrarily divided into thirty-four stages.

1. The unfertilized ovum (fig. 1). The micropyle may be seen as an indentation at the uppermost pole of the egg. The ovum is homogeneous, slightly opaque, and its surface is covered with small round 'yolk-platelets.' The ovum includes a mass of highly refractive globules of lipoid material, visible in all subsequent stages, which vary in number and size but are generally characteristic for eggs derived from a single spawning of a particular female.

At fertilization, the horny membrane or chorion is separated from the plasma membrane of the egg itself by the perivitelline space. After the development of this cavity, the shell may be cut away from the egg (Nicholas, '27). All stages subsequent to the unfertilized ovum are shown removed from the shell.

2. One-celled ovum (fig. 2). At fertilization the yolk platelets flow together and the yolk becomes crystal clear. The cytoplasm, probably mingled to some extent with the whole

yolk but concentrated at its surface, flows to one pole of the egg, usually the pole where the micropyle was situated, to form a raised blastodisc which is continuous at its periphery with a plasma membrane confining the yolk.

3. Two-celled ovum (fig. 3). The first cleavage plane, which is meridional, normally divides the blastodisc into two cells of equal size.

4. Four-celled ovum (fig. 4). The second cleavage plane, also meridional, is perpendicular to the first and divides the blastoderm into a rosette of four cells equal in size.

5. Eight-celled ovum (fig. 5). The third cleavage plane, which is double, is parallel to the first, and results in an eight-celled blastoderm made up of two rows of four cells each (see Oppenheimer, '36, for cleavage pattern of Fundulus). The blastoderm at this stage is bilaterally symmetrical, elongated in the axis of the second plane of cleavage. There is a tendency for the long axis of the eight-celled blastoderm to become the long axis of the embryo, though this is by no means invariable.

6. Sixteen-celled ovum (fig. 6). The fourth cleavage plane, double and parallel to the second, divides the blastoderm into four rows of four cells each.

7. Thirty-two-celled ovum (fig. 7). The fifth cleavage plane divides the peripheral ring of cells meridionally and the central cells horizontally.

8. Early high blastula (fig. 8). The blastoderm of this stage is similar in shape to the blastoderm of late cleavage stages but is composed of smaller cells. Nuclei from its marginal cells, which are open peripherally, wander out of the cells to enter the periblast, the part of the plasma membrane which adjoins the blastoderm.

9. Late high blastula (fig. 9). The blastoderm has not changed its shape but is composed of still smaller cells than before.

10. Flat blastula (fig. 10). The blastoderm has flattened down to form a flat lenticular structure capping the yolk. In the figure it is seen obliquely from the animal pole.

11. Expanding blastula (fig. 11). The blastoderm continues to flatten, simultaneously expanding to cover a greater proportion of the yolk surface.

12. Early gastrula (fig. 12). As the blastoderm continues to expand over the yolk, its cells pile up at the periphery at the expense of the center. The central thin area of the blastoderm is the extra-embryonic membrane which will form yolk sac epithelium. The thickened rim is the germ ring. The thickening of the rim is greater at one portion of the blastoderm, forming the embryonic shield. This is the region of the future embryo, and it is here that gastrulation commences.

13. Middle gastrula (fig. 13). As gastrulation continues, the embryonic shield increases in size by the addition of cells anteriorly, laterally and posteriorly. By the time that about half the yolk is covered, a refractive streak of cells is visible in the midline of the shield; this is the solid keel which forms the anlage of the central nervous system.

14. Late gastrula (fig. 14). As the blastoderm continues to expand over the yolk, gastrulation continues, and the shield narrows; the keel of the central nervous system is more clearly marked.

15. Closure of the blastopore (fig. 15). By the time the yolk is covered by the blastoderm, the shield has contracted to form the embryo. Normally at this stage no embryonic differentiation has taken place, except the formation of the central nervous system; occasionally, however, under peculiar environmental conditions, somites are formed and the optic vesicles differentiated by the time the blastopore is closed.

16. Expansion of the forebrain to form the optic vesicles (fig. 16). The first visible differentiation of the embryo consists of the outpouching of the forebrain walls to form the optic vesicles. If the embryo is seen in profile at this stage, the three primary brain vesicles may be recognized.

17. Formation of cavity in optic vesicles (fig. 17). The nervous system and its associated sense organs form as solid structures in the teleosteans, and their cavities by vacuolization. The cavities within the optic vesicles are the first to

develop. Simultaneously with this process mesodermal segmentation begins; embryos of this stage usually have from 1 to 4 somites.

18. Formation of auditory placode (fig. 18). As the auditory placode becomes visible, mesodermal segmentation continues, and embryos of this stage contain between 4 and 14 somites. In addition, anterior to the head of the embryo, the yolk sac epithelium develops a cavity; this is the first indication of the extra-embryonic coelom. This process has always occurred by stage 18; it may take place as early as stage 16 or 17.

19. Cavity in nervous system (fig. 19). The cavity of the nervous system forms when the embryos have from 14 to 20 somites. Early in this stage the ectoderm thickens to form lens and olfactory pit; later, melanophores are visible scattered over the yolk.

20. Expansion of the mid-brain to form the optic lobes (fig. 20). The mid-brain expands to form the optic lobes when the embryo contains from 20 to 25 somites. At this stage, neuromeres are visible in the medulla. The ear has become vesicular, and melanophores are visible on the anterior cord region of the embryo as well as on the yolk. In addition, the pericardium is differentiated. The heart is visible as a short pulsating tube under the mid-brain, and blood islands are forming on the yolk. Cells have gathered to form a faintly visible bud in the region of the pectoral fin.

21. Motility; whole heart beating (fig. 21). The embryos begin to exhibit muscular contractions when they contain about 28 somites. The optic lobes are formed; the heart consists of a pulsating tube reaching as far anterior as the tip of the head.

The first evidence of irritability appears as myogenic contraction of the anterior somites, as in the amphibian (Coghill, '34). Coghill has shown that the development of motility takes much the same course in Fundulus as he has described for Amblystoma: first the localized myogenic contractions, subsequently a unilateral contraction of the axial musculature,

progressively involving a greater number of somites as the conducting fibers of the cord gradually extend caudally. In the fish, as in the amphibian, the movements of gills, fins, etc. first accompany movements of the whole axial musculature, and only later are performed independently. There is one striking difference between the fish and amphibian, not mentioned by Coghill but observed by Hooker, '32 and others: while the first responses of Amblystoma to stimulation take the form of contractions of the musculature contralateral to the stimulus, in the Fundulus embryos it is the ipsilateral musculature that contracts. The contralateral response of the amphibian embryo has been explained by the fact that the first correlation neurones between sensory and motor cells to develop in this form are commissural floor plate cells; the nature of the teleostean response suggests that here the principal correlation neurones pass between sensory and motor cells of the same side of the cord.

22. Circulation (fig. 22). Circulation commences when the embryo has about 35 somites. The walls of the forebrain begin to widen and separate to form the cerebral hemispheres.

23. Otoliths in ear (fig. 23). When the calcareous concretions in the ear, formerly small and scattered, have aggregated to form the otoliths, some of the melanophores take their places along the edge of the pericardium, and the blood is coursing through many small channels on the surface of the yolk.

24. Prominent finbud (fig. 24). A gathering of cells has been visible in the region of the pectoral fin since stage 20; at this stage they first form a discrete solid mass.

25. Formation of urinary vesicle (fig. 25). The bladder, which develops as a bilobed outgrowth of the hindgut, is now first seen as a pair of hollow vesicles.

26. Formation of liver and peritoneal cavity (fig. 26). The liver first appears as an intestinal diverticulum located immediately posterior to the left finbud. Shortly after this structure has made its appearance, the walls of the peritoneal cavity may be seen lateral to the trunk of the embryo.

27. Round fin (fig. 27). The fin has changed in shape from a pointed bud to a flattened round structure.

28. Pigmentation of peritoneal walls (fig. 28). At this stage, the walls of the peritoneal cavity become pigmented by the deposition of granules of melanin and guanin.

29. Circulation in pectoral fin (fig. 29). The fins become motile at approximately the same stage when circulation commences in the border vessels of the fin.

30. Finrays in caudal fin (fig. 30). By the time the rays are visible in the caudal fin, the lower jaw of the embryo is formed, though it does not yet move.

31. Formation of swim bladder (fig. 31). At this stage the Swim bladder is first visible as a diverticulum of the gut. Eyes and mouth now move.



Fig. A Photomicrograph of fixed Fundulus embryo, stained with borax carmine. Stage 34. Yolk completely absorbed.

32. Hatching (fig. 32). The yolk has visibly decreased in amount at the time the embryo hatches; the proportion of yolk absorbed varies in different embryos.

33. Pigmentation of swim bladder (fig. 33). The swim bladder grows considerably and becomes pigmented before the yolk is completely absorbed.

34. Yolk absorbed completely (text fig. A). The designation of the stage where the yolk is absorbed as the final step of the series is purely arbitrary; it must not be thought that at this stage the fry are miniature adults. Many more changes must ensue before adult proportions are attained: skin and scales must be differentiated, much of the skull and axial skeleton remains to be elaborated, the definitive pigment

pattern is yet to be laid down, and the dorsal and anal fins are still to be formed, to mention only a few of these changes. In addition the body as a whole is to undergo considerable change of proportion, and its parts varying degrees of heterogonic growth. Since all these processes are gradual and a continuation of the earlier processes we have described, there can be chosen no exact moment when the embryo metamorphoses into an adult. The stage of yolk absorption is a convenient stopping place because the primitive organ systems are all represented at this stage; for the morphologist, the following stages are as interesting as the earlier, and it is hoped that these will be studied in the near future.

LITERATURE CITED

Coghill, G. E. 1934 Somatic myogenic action in embryos of Fundulus heteroclitus. Proc. Soc. Exp. Biol. and Med., vol. 31, pp. 62–64.

Hooker, D. 1932 Spinal cord regeneration in the young rainbow fish Lebistes reticulatus. J. Comp. Neur., vol. 56, pp. 277–295.

Nicholas, J. S. 1927 Application of experimental methods to the study of developing Fundulus embryos. Proc. Nat. Acad. Sci., vol. 13, pp. 695–698.

Oppenheimer, J. M. 1936 Processes of localization in developing Fundulus. J. Exp. Zool., vol. 73, pp. 405–444.

PLATES

PLATE 1

EXPLANATION OF FIGURES

Photomicrographs of living Fundulus embryos

1 Stage 1, unfertilized ovum.
2 Stage 2, one-celled ovum.
3 Stage 3, two-celled ovum.
4 Stage 4, four-celled ovum.
5 Stage 5, eight-celled ovum.
6 Stage 6, sixteen-celled ovum.
7 Stage 7, thirty-two-celled ovum.
8 Stage 8, early high blastula.
9 Stage 9, late high blastula.
10 Stage 10, flat blastula.
11 Stage 11, expanding blastula.
12 Stage 12, early gastrula.
13 Stage 13, middle gastrula.

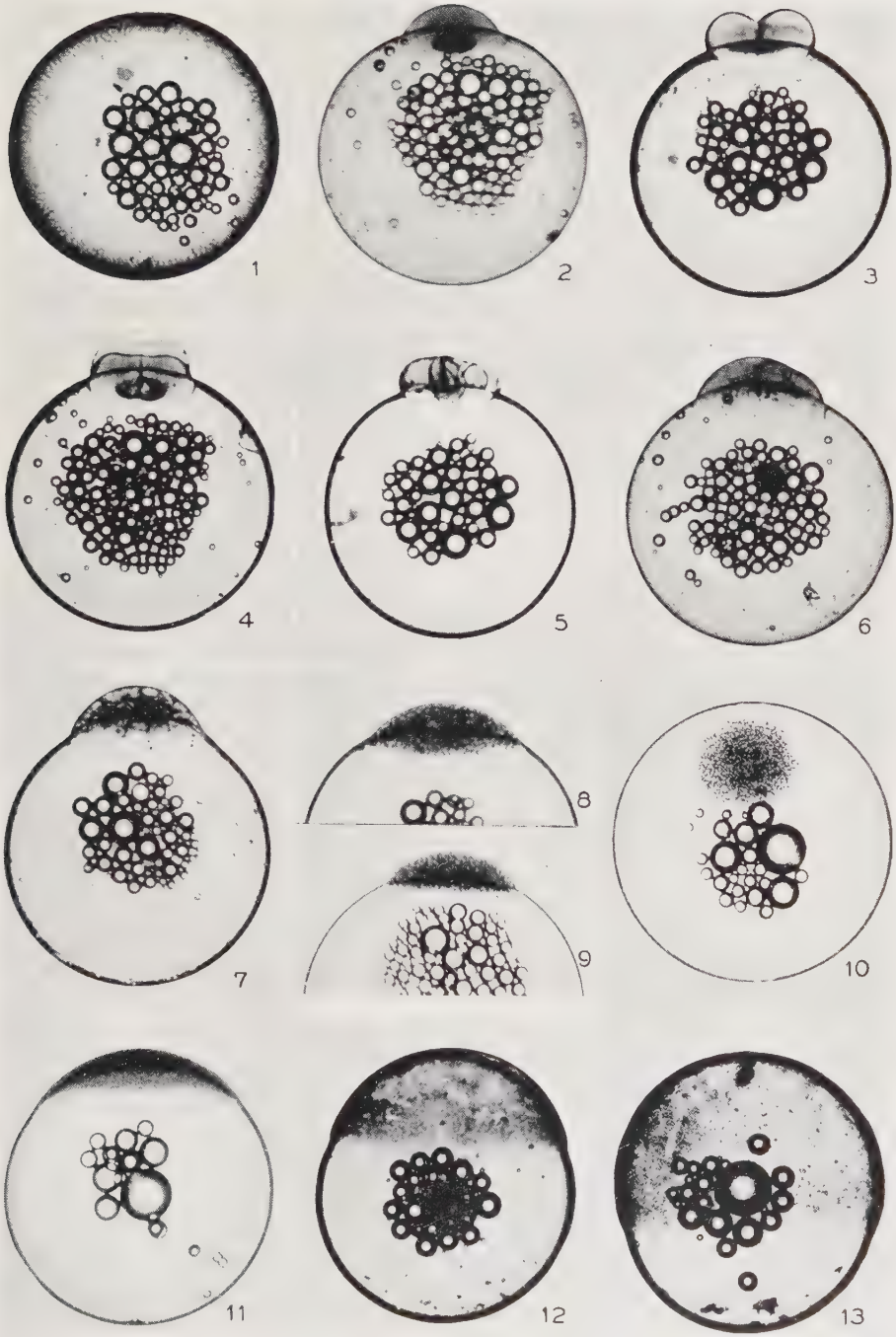
1
2
3
4
5
6
7
8
9
10
11
12
13

PLATE 2

EXPLANATION OF FIGURES

Photomicrographs of living Fundulus embryos

14 Stage 14, late gastrula.
15 Stage 15, closure of the blastopore.
16 Stage 16, expansion of the forebrain to form the optic vesicles.
17 Stage 17, formation of cavity in optic vesicles.
18 Stage 18, formation of auditory placode.
19 Stage 19, formation of cavity in nervous system.
20 Stage 20, expansion of the mid-brain to form the optic lobes.
21 Stage 21, motility; whole heart beating.
22 Stage 22, circulation.
23 Stage 23, formation of otoliths.
24 Stage 24, prominent finbud.
25 Stage 25, formation of urinary vesicle.

14
15
16
17
18
19
20
21
22
23
24
25

PLATE 3

EXPLANATION OF FIGURES

Photomicrographs of living Fundulus embryos

26 Stage 26, formation of liver and peritoneal cavity.
27 Stage 27, round fin.
28 Stage 28, pigmentation of peritoneal walls.
29 Stage 29, circulation in pectoral fins.
30 Stage 30, finrays in caudal fin.
31 Stage 31, formation of swim bladder.
32 Stage 32, hatching.
33 Stage 33, pigmentation of swim bladder.

26

27



28

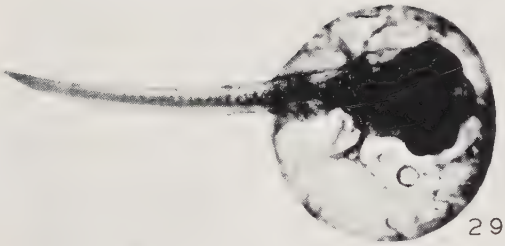

29

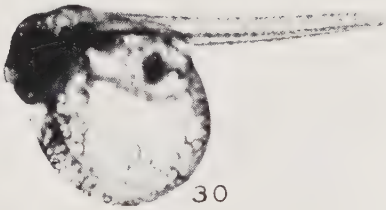

30

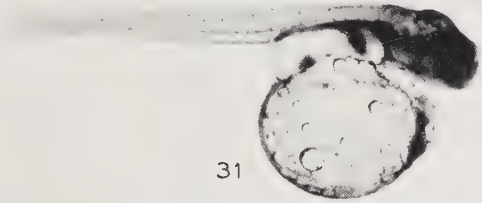

31

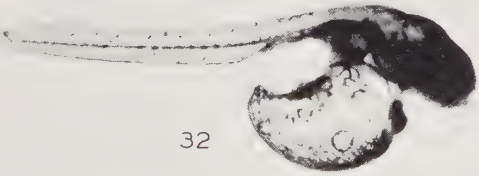

32



33

THE DEVELOPMENT OF THE PARS INTESTINALIS OF THE COMMON BILE DUCT IN THE HUMAN FETUS, WITH SPECIAL REFERENCE TO THE ORIGIN OF THE AMPULLA OF VATER AND THE SPHINCTER OF ODDI

II. THE EARLY DEVELOPMENT OF THE MUSCULUS PROPRIUS

R. A. SCHWEGLER, Jr. AND E. A. BOYDEN

Departments of Obstetrics and Anatomy, University of Minnesota

FIVE TEXT FIGURES AND FOUR PLATES (TWELVE FIGURES)

In the preceding number of this journal attention was called to the involution of the ampulla of Vater—a process by which the hepato-pancreatic duct is reduced from a segment extending the whole length of the oblique passage in the intestinal wall, to a small terminal chamber the primary function of which would seem to be the production of valvules. It is now appropriate to discuss the relation of this process to the differentiation of fibers that constitute the sphincter of Oddi.[1]

PREVIOUS VIEWS OF THE ORIGIN OF THE SPHINCTER

Apparently the first embryological study of this muscle must be attributed to Helly ('00) whose name is associated with the discovery of a sphincter around the outlet of the accessory pancreatic duct. His account, however, is more or less

[1] The term that Oddi, himself, employed to designate the "special musculature of the opening of the choledochal canal, which acts like a sphincter," was sphincter du cholédoque.' But as one of us has pointed out (Boyden, '37), the species differences in this region are so great as to preclude the use of any common term more specific than 'musculus proprius.' Accordingly, we have reserved the name sphincter choledochus for the special circular fibers that ensheath the preampullary portion of the common bile duct—those, indeed, which subserve the functions attributed by Oddi to the musculature of the whole tract.

incidental to a description of the development of the pancreas, so that the sphincter of Oddi is displayed in only two drawings, representing sections of human embryos 28.5 and 80 mm. in length. Discussion of the critical point as to when the intrinsic musculature of the ducts first appears is limited to this brief comment: "The following embryos [i.e., those comprising the 28.5 mm., 39 and 45 mm. stages, etc.] already possess both papillae, as well as clearly recognizable musculi sphinct. in the same. . . . . The intestinal musculature [in the 28.5 mm. stage] stretches itself further in ring-shaped arrangement upon all three ducts (fig. 45), whereby there is given the Anlage of the Musculi sphinct." But F. T. Lewis ('12) in commenting on this sentence in Keibel and Mall's Manual of Human Embryology (p. 436) presents contrary evidence: "In specimens of 44 mm., in the Harvard Collection, the ducts are surrounded only by concentric mesenchyma and by the duodenal muscle through which they pass." Our observations confirm the view that what Helly saw was concentrically arranged mesenchyma.

The next embryologist to study the sphincter seems to have been Broman ('13). While examining the numerous valves of the hepato-pancreatic duct in a full term fetus of an antartic seal, he noted a strong sheath of muscle encircling the hepato-pancreatic duct and observed that on one side it was characteristically combined with the circular muscle of the duodenum. In the same article he figured a cross section of the human ampulla of a 30 cm. fetus (same level as in fig. 17) and noted that it was without intimate connection with the tunica muscularis. Apparently he did not see the sphincter muscle around the bile duct. His conjecture that the musculus proprius of the ampulla originates from the t. muscularis mucosae cannot be confirmed.

A few years later one of Broman's students (Rietz, '17) added to these observations while making a general survey of the development of the extra-hepatic biliary tract. He agreed with Lewis in placing the origin of the sphincter later than the 28.5 mm. stage, but mentioned that "one sees in a 45 mm. fetus that there is not only a slit in the muscle layer for the passage of the ducts but even that individual fibres turn aside at that point. In a 63-mm. fetus the ducts are beautifully surrounded, at the place of entrance, by fibres of the circular muscle layer and in a fetus 75 mm. long there exists here a distinct sphincter which continues upwards onto the choledochus and pancreaticus and which lower down is distinctly

separated from the circular muscle layer of the gut." He concludes from his preparations that "the principal origin is from the circular-muscle layer of the duodenum" and that there is a "secondary shifting of fibres in a downward direction."

The fourth and apparently the only attempt to work out the development of the human sphincter in detail was that made in 1933 by Porsio, an anatomist at Palermo. His material consisted of preparations of the duodenum of fetuses ranging from 8 to 50 cm. in total length (crown-heel measurement). Sections of these, cut at 10 to 20 μ, were stained by the Van Gieson method. The article is illustrated by seven dark and somewhat blurred photomicrographs: four from the 8 cm. (12 weeks?)[2] stage—only two of which show the intrinsic muscle—two from the 30 cm. stage (24 weeks?), and one from the 39-cm. stage (31 weeks?). The author explains that stages younger than 80 mm. (60? mm., C.R.)[2] were not examined as they were not considered pertinent to the problem; indeed, Porsio states that "the sphincter of Oddi [perhaps he means the sphincter ampullae] does not begin to form until the 13–15 cm. stage" (15 weeks?), at which time the ampulla of Vater is also said to appear. Apparently unaware of Rietz's publication, Porsio likewise concludes that the sphincter is formed by successive increments from the intestinal musculature—instead of by developing in situ through the progressive differentiation of mesenchyma. Thus we are told that the sphincter "grows at the expense of the intestinal musculature" and is "an emanation from it." With this interpretation—which obviously arises from the author's diagrammatic conception of the adult sphincter ('29) and from the omission of younger stages from his series of embryos—we are obliged to disagree. But it should be remembered that until methods of visualizing all three dimensions are employed it is difficult to analyze the origin of so deceptive a structure as the sphincter of Oddi.

OBSERVATIONS

The pre-muscle or mesenchymal stage of the sphincter. The first step in the formation of the musculus proprius is a rearrangement of the mesenchyma at the point where the bile and pancreatic ducts enter the transverse slit in the circular muscle

[2] Our estimate of menstrual age, based on table 9 (p. 50) and graph 1 (p. 344) of Scammon and Calkins ('29).

layer of the duodenum. At this level, and slightly lower, the mesenchymal cells elongate and take up a concentric position around the common bile duct and around the zone of junction of the bile and pancreatic ducts. (See plate 4 of preceding

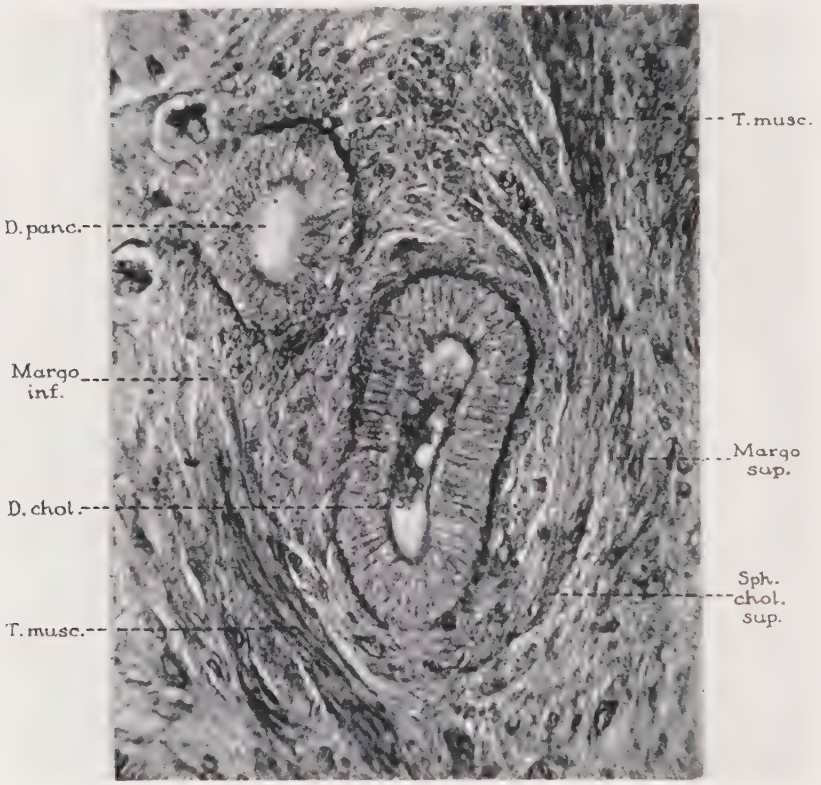

Fig. 1 Photomicrograph (× 350) of section 2818 of a 45-mm. human embryo (H.E.C., no. 2128), showing the first stage in the development of the musculus proprius (Sph. chol. sup.). Compare its appearance with that of adjacent portions of the tunica muscularis forming the upper and lower margins of the intestinal window (Margo sup. and inf.). (This specimen was cut at 10 μ and stained in alum cochineal and orange-G, a dye that is very hard to photograph.) For orientation, see low power drawing of same section in figure 2.

article.) This rearrangement of cells may be noted as early as the 26-mm. stage (H-29 of the Minn. Coll.). It is not visible, however, in a 25-mm. embryo (H-326). Helly ('00)

has published a drawing of it in a 28.5 mm. embryo but he has labelled the mesenchyma 'musculus sphincter'—an error of interpretation to which F. T. Lewis called attention in 1911–1912.

The initial appearance of intrinsic muscle fibers. This step in development takes place when the cytoplasm of the con-

Fig. 2 Tracings of selected sections of the pars intestinalis of a 45-mm. human embryo (no. 2128, of the Harvard Embryological Collection). × 80. Section 2816: Transverse section through the top of the fenestra (Fen. chol.). Note that the bile duct (D. chol.) still lies outside duodenum. X, offshoots of circular layer of intestine (see text); Sph. chol. sup., sphincter fibers within tunica propria (dash line) of bile duct (compare fig. 4, an older stage of the same level); Alv., pancreatic alveoli. Section 2818: About six sections below 2816 (three or four sections missing, in this series), showing entrance of pancreatic duct into fenestra; note origin of sphincter from mesenchyma and its independence of the tunica muscularis (Margo sup.). For photograph, see figure 1; also compare figure 7. Section 2824: Six sections below 2818, lowest level at which fibers of musculus proprius have differentiated; X^2, fibers leaving inner surface of Margo superior (compare fig. 4).

centric layer of mesenchymal cells is sufficiently well developed to take an acid stain. The exact time at which this occurs is not easy to determine since it is only in embryos which have been cut in a favorable plane and well stained that these incipient fibers can be clearly seen. However, through the

courtesy of Profs. G. L. Streeter, B. F. Kingsbury and F. T. Lewis it has been the privilege of one of us (E.A.B.) to examine the embryos in the Carnegie, Cornell and Harvard Collections and therefore to have arrived at a better understanding of this critical stage than would have been otherwise possible.

The period of early differentiation falls within the ninth to eleventh week of intrauterine life and is distinguishable in the following embryos:

No.		*mm.*	*μ*	
H-12	(Minnesota)	41	15	Slides 152-3
4985	(Carnegie)	41	20	Slide 189
3419	(Carnegie)	43	50	Slide 84
2128	(Harvard)	45	10	Sections 2816–29
4475	(Carnegie)	48	20	Slides 215–16
73	(Cornell)	50	25	Slide 161
3990	(Carnegie)	54	20	Slide 250
4229	(Carnegie)	58	20	Slides 207–208

Before describing this stage, however, it is necessary to understand the topography of the intestinal window since the intrinsic fibers first appear at this level and are in somewhat intimate contact with its margins. To display this relation we have chosen an older stage—as illustrated by the model of a 115-mm. embryo.

The choledochal fenestra. Figure 9 illustrates the entrance of the bile and pancreatic ducts into the intestinal wall at 16 weeks of intrauterine life. At the place of entrance the longitudinal muscle of the duodenum falls away leaving a longitudinally placed hiatus (H^2). This is caused not only by the antecedent presence of the ducts but by the subsequent crowding in of pancreatic alveoli (fig. 13)—to such an extent that growth of the longitudinal muscle, in this region, appears to be inhibited. Laterally, however, it remains, flaring out as if to engulf the alveoli that have gotten in its way. These facts alone would seem to be sufficient to eliminate the theory

that in man the longitudinal muscle participates in the development of the musculus proprius of the ducts.[3]

In contrast to the hiatus in the longitudinal coat of the duodenum, the window in the circular muscle is transversely placed (fig. 9). In the beginning it is roundly oval, but by the 33-mm. stage it has narrowed to a slit (compare plates 1 and 3 of preceding article). This configuration is retained throughout fetal life. Oddi compares its mammalian counterpart to a small 'eye' and French authors to a 'button hole.' In accordance with our term 'fenestra,' it can be likened to the 'ox-eye windows' of old Saxony. As shown in figure 9, its upper margin has been pressed in by the bile duct while the lower margin bulges to accommodate the junction of the bile and pancreatic duct. Within this transverse window lies the musculus proprius of the ducts, situated like an iris within the slit of the eyelids. Much confusion has arisen in the literature because of the difficulty of visualizing this relationship in sections.

The initial relation of the musculus proprius to the choledochal fenestra. Returning, now to younger stages, the first mesenchymal cells to differentiate into a smooth muscle sheath are those represented at position 1 in figures 5A and B. Their exact disposition seems to depend upon the size of the fenestra and the angle at which the bile and pancreatic ducts enter

[3] A contrary view is presented by Porsio ('33). In connection with his description of a slightly younger (13 cm., C.H.) fetus, he writes (loc. cit., p. 621): "In the human embryo, up to a certain period of intrauterine life, one can see thin muscle fibers of the longitudinal muscle of the intestine detach themselves and follow the two ducts in a parallel way along their course through the intestinal wall until they reach the submucosa of the intestine. Such fibers are the longitudinal fibers of Oddi's sphincter." But in his conclusion (p. 624) he states that in fetuses of 15 cm. and older "the longitudinal fibers of the sphincter lose their connection with the longitudinal muscles of the intestine." In our specimens they disappear from this region before the 65-mm. stage. Nuboer, however, goes even further, affirming in his description of the adult ('31) that the whole mucosal side of the sphincter of Oddi—circular as well as longitudinal fibers—represents an extension along the ducts, of the longitudinal coat of the intestine. But the maceration specimens of Hendrickson show that this is not true and we will present additional evidence against this point of view in our next article.

the window. If the fenestra is compressed and the ducts enter obliquely, then the first fibers will occupy the position indicated in figures 1 and 2 and will be limited to the mucosal side of the bile duct. If, however, the window is less compressed and the two ducts enter at right angles to the duodenal wall, as in figures 3 and 7, then the first fibers will envelop the bile duct completely, forming a ring which we have named the sphincter choledochus superior.

In the eight embryos between 41 and 58 mm., listed above, these two types are about equally divided. Curiously enough, Rietz and Porsio seem to have seen only the first type. The peculiarity of this pattern—based on the rotation of the duct—is that the muscle which develops on its mucosal side seems to pass from one margin of the window to the other (figs. 1 and 2). It is wholly natural, therefore, that these authors should have concluded that the intrinsic muscle of the ducts is derived from the circular muscle of the duodenum. Thus Rietz observes, "one sees in a fetus of 45 mm. length (C.R.) that there is not only a slit present in the muscle layer for the passage of the ducts, but even that individual fibers turn aside at that point." Porsio labels a similar band, in a 12-week fetus (80 mm., C.H.), "the left head of the interrupted intestinal muscle" and says further, in the same article (loc. cit., p. 622), "In my preceding research [the 1929 article, describing the sphincter of the adult] I became aware of such facts, since from the first stage of intrauterine life one notes that this circular muscle of the intestine divides itself into two layers the outer of which resolves itself around the bile duct completely embracing it." That these fibers are not offshoots of the tunica muscularis, however, seems probable from the following considerations.

First, it is possible to demonstrate, in as perfectly a preserved and stained embryo as that shown in figure 1—for the use of which we are greatly indebted to the Harvard Laboratory—that the fibers surrounding the bile duct are differentiating from mesenchyma. Not only do they stain lighter and have less elongated nuclei, but the fibers subtend a lesser arc

than the margins of the intestinal window; in other words the two are not continuous when first formed.

Second, there is the evidence supplied by the alternate pattern found in these young embryos—namely, that when there is room in the window the fibers completely encircle the bile duct, some distance from the margins of the window (figs. 3 and 7).

Fig. 3 Tracings of successive sections of the pars intestinalis of a 65-mm. (C.R.) fetus (H-55), illustrating early appearance of complete rings about bile duct. × 40. For photomicrograph of sections 375 and 376 see figures 7 and 6, respectively. Alv., pancreatic alveoli crowding up against muscle of intestine; dotted lines, longitudinal muscle of duodenum; solid black areas, circular muscle; Fen. ch., fenestra choledocha; T. muc., musc. and submuc., three tunics of duodenum. Other legends, as before.

Third, the musculus proprius appears some 4 weeks later than the duodenal muscle, the latter originating about the sixth week of age (between the 10- and 14-mm. stages, Rietz, '17) and the former between the ninth and tenth weeks (41- to 45-mm. stage); nor is it without significance that the later date is just the time when the smooth muscle coats of other ducts, the ureters, are beginning to differentiate from mesenchyma (Felix, '12; in Keibel and Mall's Manual of Embryology, p. 866). Indeed, the two processes would seem to

be comparable, even to the extent of each duct's having a gradient in the development of its muscular coat.[4]

Fourth, even if the ring of developing muscle is in contact with the upper and lower margins of the window it is completely separated from the duodenal musculature above and below these levels (figs. 12 and 16; also sections of 8-month fetus in next article). Yet if one accepts the criteria of Rietz and Porsio it is necessary to believe that the entire musculus proprius—from upper margin of window to orifice of duct—is an emanation from the tunica muscularis. This is especially hard to reconcile with pictures like figures 7 and 8, or 16 and 17—in which one can see successive stages in the differentiation of the mesenchyma—or with the testimony of Comparative Anatomy; for in fishes (Higgins, '28) and in the opossum (DuBois and Hunt, '32) the musculus proprius of the bile passage is everywhere separated from the intestinal muscle by an intervening layer of connective tissue; and in the opossum, the sheath that encloses both ducts lies outside the intestine. On a priori grounds therefore, it seems improbable that having started with an intrinsic muscle coat for the bile passages the higher vertebrates should have substituted a tunic of entirely different origin.

Finally, if the two margins of the tunica muscularis produce the musculus proprius one would expect the muscle sheath around the ducts to have the shape of a slit, in cross section, as is true of the upper portion of the pars intestinalis in the dog. (See Halpert's figures, '32).[5] But such is not

[4] Felix states that the circular musculature of the ureters appears in embryos of 70 mm. head-foot length, i.e., about 53 mm. crown-rump length. It forms first at the bladder end of the ureter and then gradually extends toward the kidney; in embryos of 150 mm. (16 weeks), it is present throughout the entire length of the ureter. But because the muscle coats of the ureters start at the bladder we do not say that they are an 'emanation of the bladder musculature.

[5] The dog is especially instructive, in this connection, because in addition to the flattened funnel of intestinal muscle which encloses the proximal part of the bile duct, there is a layer of intrinsic muscle immediately ensheathing the duct. (Fig. 1, Boyden, '37.) These fibers are also visible in Halpert's figures but are either unacknowledged (in the upper sections) or wrongly identified with the muscularis mucosae (in the lower sections). However, a comparison of

the case in the human embryo. The intrinsic muscle is disposed like the iris within the slit of the eyelids (fig. 9). One can see, however, a vestige of the condition that prevails in the dog.

To understand this, it is necessary to observe that portion of the bile duct that lies outside the window (fig. 12). Here, the duct is surrounded by an independent ring of muscle (Sph. chol.). As the duct descends, however, that ring fuses, on the intestinal side, with the circular muscle of the duodenum. This contact seems to stimulate the intestinal muscle to throw off concentric rings which lie outside the tunica propria of the bile duct and occupy the corners of the eye-shaped windows (see X^1, fig. 4; also fig. 2, section 2816). In man some of these offshoots attempt to encircle the bile duct; others descend as longitudinal fibers along the course of the duct (X^1, fig. 13). In animals like the dog these fibers are well developed and constitute the triangular space in the corners of the eye described by Oddi. Similarly the inner sides of the Margo superior contribute scattered offshoots of the intestinal muscle which descend into the window alongside the bile duct (X^2, figs. 4 and 13).

These fibers, which seem to correspond to the 'X' fibers of Hendrickson contribute to the longitudinal coat of the musculus proprius. They are obviously accessory to the main sheath of fibers that encircles the bile passages and their presence in no way alters the concept that the musculus proprius develops in situ from mesenchyma. The significance of these 'X' fibers which various authors have described as being 'borrowed' from the intestinal musculature, will be discussed in the next article.

It is now appropriate to summarize the mechanism of growth that is recasting the structure of the pars intestinalis during the months of fetal life.

---

the two species would indicate that the two bile tracts represent opposite extremes of development. In the human duodenum, downgrowth of the superior margin of the fenestra choledocha is suppressed and the musculus proprius of the ducts becomes highly developed. In the dog the superior margin of the window descends in such force as to overshadow the intrinsic muscle around the ducts. (Unpublished data, E. A. Boyden).

Gradients in the development of the musculus proprius. In the 16-week fetus shown in plate 2, the musculus proprius extends from just outside the fenestra to the upper end of the ampulla (fig. 10). Below this point, the muscle is still in the mesenchymal stage of development (fig. 17) but sometime before the seventh month (see plate 5 of preceding article) it will have differentiated nearly as far as the distal end of

Fig. 4 Tracings of two sections of the 115-mm. embryo shown in figure 9. × 80. These just precede the section shown in figure 13. They illustrate the tendency of the circular muscle to throw off strands (X^1), in the corner of the eye-shaped window, which simulate the fibers of the sphincter choledochus superior. Some of them descend along the sides of the sphincter as longitudinal fibers; X^2, fibers given off from the inner side of the Margo superior. (Note that the lateral portion of the margin is formed by a partially detached column of intestinal muscle. Compare fig. 9.)

the ampulla. The principal gradient of growth, therefore, would seem to be in the direction of the lumen of the intestine, i.e., from fenestra to ostium (a to f, fig. 5 D).

This slow moving gradient, however, does not account for the shift in position of the junction of the bile and pancreatic ducts (fig. 5 A to D). As pointed out in the preceding article, the upper end of the ampulla retreats early from the fenestra toward the lumen of the intestine until by the seventh or eighth month its lies halfway between the two. Should this movement be due solely to the more rapid growth of the intestinal wall, so that the junction of the ducts is gradually pulled away from the window—as if one took hold of the papilla and pulled—then one would expect that the first rings to appear around the bile duct would be the inferior fibers of the sphincter choledochus (1, as hypothetically diagrammed in fig. 5 E) and that the last to be formed would be the superior fibers (5, fig. 5 E). But just the opposite is true. The superior fibers of the sphincter choledochus are the first to be formed (1, fig. 5 B). By the 115-mm. stage, they are still in the window (fig. 5 C), even though the ampulla has retreated some distance from the wall.

When we look at the space between the bile and pancreatic ducts in the region below the fenestra, where the important sphincter choledochus inferior will appear, there are only a few scattered fibers at this stage (fig. 10); also those on the mucosal side of the duct are thinned out—more so than appear in the model—as if this were an active region of interstitial growth. Moreover, the space between the two ducts is so narrow as to leave little room at first for developing fibers.

It is this delayed completion of the lower sphincter that has suggested to one of us (E.A.B.) that there is superimposed upon the primary gradient mentioned above, a more active secondary center of interstitial growth which is located in the preampullary segment of the pars intestinalis. The probable way in which it operates is shown in figure 5 D. The letters *a* to *f* indicate the principal gradient for the whole pars intestinalis. Within segment *a*, there is a reversal of order;

O, represents a zone of rapid interstitial growth; 1, the sphincter fibers that were first differentiated (sphincter choledochus superior)—those which once lay next to *O* but which have remained at the fenestra as the successive zones 2, 3, 4 and 5 (sphincter choledochus inferior) have been formed. As zone *O* proliferates it continues to push the junction of the ducts further and further away from the window, thereby

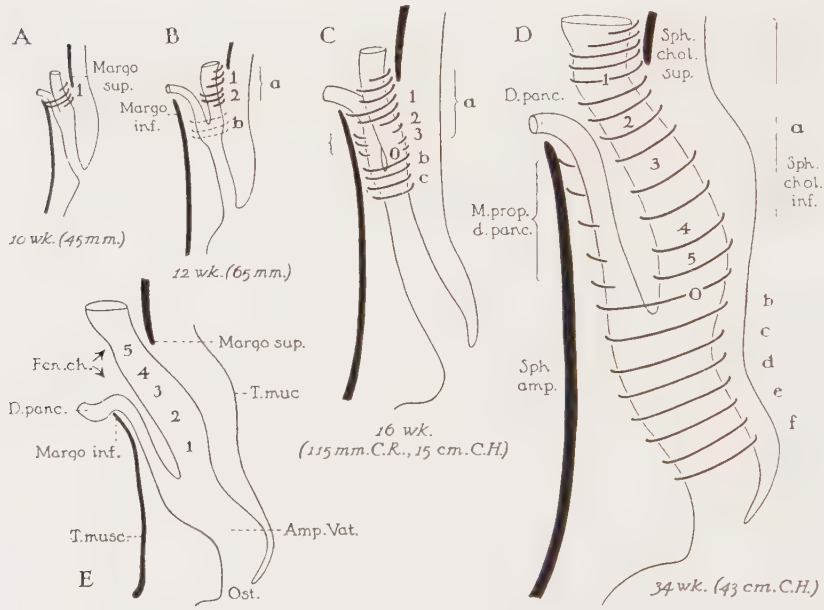

Fig. 5 Diagrams illustrating 1) the order of differentiation of circular fibers of the musculus proprius; 2) opposing theories regarding the mechanism of involution of the ampulla of Vater.

A and C illustrate specimens in which the bile and pancreatic ducts enter the duodenum obliquely, as a result of which the fibers appearing on the mucosal side of the bile duct seem to extend between the two margins of the window.

B and D illustrate specimens in which the two ducts enter the duodenum at right angles to its wall. Here the first fibers enclose the bile duct. The numbers 1, 2, 3, 4, 5 indicate the presumed order of appearance of fibers of the sphincter choledochus; O, presumed site of secondary zone of growth, the interstitial proliferation of which pushes the junction of bile and pancreatic ducts away from the choledochal window.

E. This is a diagram illustrating an alternate theory of growth based upon the assumption that the more rapid growth of the intestinal wall drags the zone of junction of ducts away from the choledochal window. The numbers 5, 4, 3, 2, 1, indicate the hypothetical order of formation of the sphincter choledochus under such a scheme.

reducing the length of the ampulla relative to the whole pars intestinalis. The growth in absolute length of the ampulla, as noted in the preceding article, may be explained by its own slow growth and by the more rapid (?) growth of the mucosa, the buckling of which produces the plica longitudinalis.

Finally, the physiological consequences of this process are profound, for its effect is to carry the sphincter choledochus inferior away from the intestinal muscle and set it up as an independent agent. This sequence of events is, therefore, quite different from that found in animals like the guinea pig and rabbit, in which species the musculus proprius not only develops at the level of the window, but remains there, its action to be obscured by the activity of the duodenal musculature.

SUMMARY

Evidence is presented in support of the view that the musculus proprius of the pars intestinalis differentiates in situ from mesenchyma. This is opposed to the continental view that the sphincter of Oddi is an emanation from, or grows at the expense of, the tunica muscularis of the duodenum.

The first sign of a musculus proprius is a concentric arrangement of the mesenchyma about the bile and pancreatic ducts in a 26-mm. embryo. This encircles the preampullary portion of the ducts just beyond the point where they have pierced the tunica muscularis.

Between the 41- and 45-mm. stages—4 weeks after the intestinal muscle has formed—this concentric mesenchyma differentiates into the preampullary zone of intrinsic muscle. It appears about the same time as the first rings of smooth muscle that encircle the ureter. Similarly it has a characteristic gradient whereby the muscle fibers differentiate successively in the direction of the papilla.

Superimposed upon this gradient is a secondary center of interstitial growth located in the preampullary segment of the ducts. As this zone of growth moves caudad it leaves behind it a sphincter choledochus superior located in the intestinal window and a sphincter choledochus inferior strung

out along the intramural portion of the bile duct. Also as it moves it pushes the junction of the bile and pancreatic ducts further into the submucosa, thereby reducing the relative length of the ampulla. This movement is aided by the rapid growth of the intestinal mucosa, the buckling of which produces the plica longitudinalis. This sequence of growth derives its chief significance from the fact that it carries the main sphincter of the bile duct away from the intestinal muscle and sets it up as an independent mechanism for regulating the flow of bile.

The final article in this series will deal with the anatomy of the musculus proprius.

LITERATURE CITED

Boyden, Edward A. 1937 The sphincter of Oddi in man and certain representative mammals. Surgery, vol. 1, pp. 25–37.

Broman, Ivar 1913 Ueber die Existenz und Bedeutung einer kombinierten Ringmuskel- und Klappenvorrichtung im Ductus Hepato-pancreaticus bei gewissen Säugern (einschliesslich beim Menschen). Verh. d. Anat. Ges., Bd. 27, S. 20–25.

DuBois, Franklin S. and Eleanor A. Hunt 1932 Peristalsis of the common bile duct in the opossum. Anat. Rec., vol. 53, pp. 387–398.

Halpert, Béla 1932 The choledocho-duodenal junction. A morphologic study in the dog. Anat. Rec., vol. 53, pp. 83–102.

Helly, Konrad K. 1900 Zur Entwickelungsgeschichte der Pankreasanlagen und Duodenalpapillen des Menschen. Arch. f. Mikr. Anat., Bd. 56, S. 291–308.

Hendrickson, William F. 1898 A study of the musculature of the entire extra-hepatic biliary system, including that of the duodenal portion of the common bile-duct and of the sphincter. Bull. Johns Hopkins Hosp., vol. 9, pp. 221–232.

Higgins, George M. 1928 Contraction of the gall bladder in the common bullhead (Ameiurus nebulosus). Arch. Surg., vol. 16, pp. 1021–1038.

Nuboer, J. F. 1931 Studien über das extrahepatischen Gallenwegs-system. II. Der Bau der Muskeln und des elastischen Gewebes in den normalen extrahepatischen Gallenwegen. Frankf. Zeitschr. f. Path., Bd. 41, S. 198–249.

Oddi, Rugero 1887 D'une disposition a sphincter spécial de l'ouverture du canal cholédoque. Arch. Ital d. Biol., T. VIII, pp. 317–322.

Porsio, Agostino 1929 Contributo alla struttura della porzione intraparietale del dotto coledoco e del dotto pancreatico, con speciale riguardo allo sfintere di Oddi. Monit. Zool. Ital., vol. 40, pp. 265–268 of No. 11–12, i.e., 557–560 of vol. 40.

PORSIO, AGOSTINO 1933 Studio sullo sviluppo dello sfintere di Oddi dell'Uomo. Arch. Ital. d. Anat. e. d. Embriol., vol. 30, pp. 603–625.

RIETZ, TORSTEN 1917 Ueber die normale und abnorme Entwicklung der extrahepatischen Gallenwege. Nord. Med. Arkiv, Bd. 50, S. 1–74.

SCAMMON, RICHARD E. AND LEROY A. CALKINS 1929 The development and growth of the external dimensions of the human body in the fetal period. Univ. of Minn. Press, Minneapolis.

SCHWEGLER, R. A. JR. AND E. A. BOYDEN 1937 The development of the pars intestinalis of the common bile duct in the human fetus, with special reference to the origin of the ampulla of Vater and the sphincter of Oddi. I. The origin and involution of the ampulla. Anat. Rec., vol. 67, pp. 441–467.

——— 1937 III. The composition of the musculus proprius. Ibid., vol. 68, no. 2. (In press.)

PLATE 1

EXPLANATION OF FIGURES

6 Low power view (× 10) of the abdominal cavity of a 65-mm. (C.R.) fetus (H. 55), to show relation of bile duct (D. chol.) to pancreas (Panc.) and wall of duodenum (pars desc.). Ao, aorta; Chor. d., notochord; Col. tr., transverse colon; Hep., liver; Med. sp., spinal cord; Pars inf. (of duodenum); Ren. dex. and sin., right and left kidneys; Ves. fel., gall bladder (note encircling muscle). For high power tracing of bile duct in this same section, see figure 3, section 376.

7 High power view (× 80) of section 375, the one next above that shown in figure 6; illustrating early appearance of the sphincter choledochus superior. For relation to other layers of gut, see outline of this section in figure 3 (section 375). D. ch., common bile duct; D. panc., pancreatic duct entering window; Gl., glands of tunica mucosa; Panc., pancreatic alveoli pushing into window; T. submuc., submucosal layer of duodenum.

8 High power view of section 380 (× 80) showing mesenchyma (mes.) arranged about the upper end of the ampulla of Vater, just prior to differentiation into fibers of musculus proprius. This is four (50 μ) sections below that shown in figure 6. Vill., villus of tunica mucosa. Other legends as before.

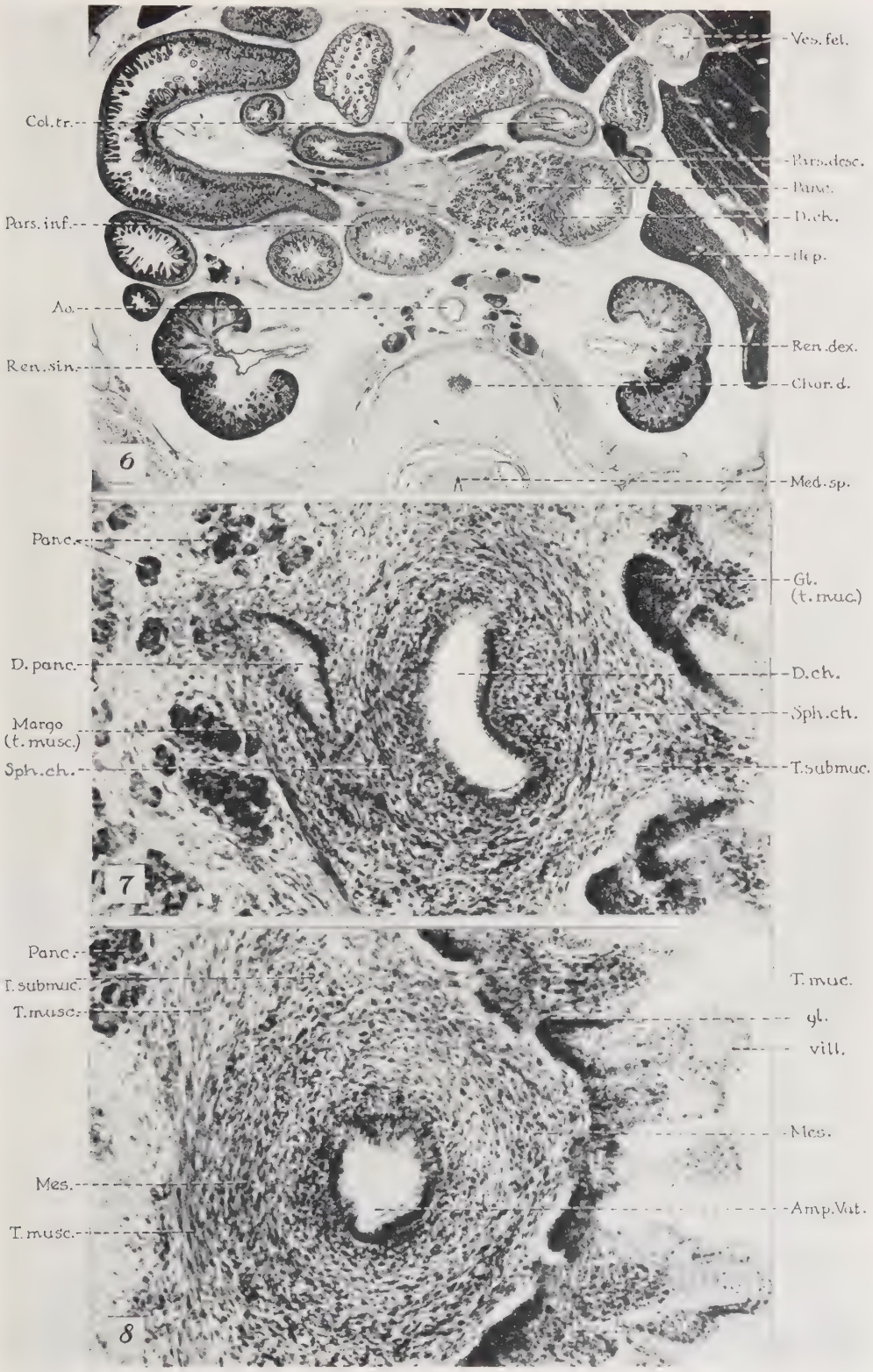
Ves. fel.
Col. tr.
Pars. desc.
Panc.
Pars. inf.
D. ch.
Hep.
Ao.
Ren. dex.
Ren. sin.
Chor. d.
6
Med. sp.
Panc.
Gl. (t. muc.)
D. panc.
D. ch.
Sph. ch.
Margo (t. musc.)
Sph. ch.
T. submuc.
7
Panc.
T. submuc.
T. muc.
T. musc.
gl.
vill.
Mes.
Mes.
Amp. Vat.
T. musc.
8

PLATE 2

EXPLANATION OF FIGURES

9 Drawing of wax reconstruction of left surface of pars descendens duodeni of a 16-week fetus (115 mm., C.R.; 15 cm. C. H.). × 40. Ducts and mucosa modelled in white wax, muscle in brown wax. For orientation in body, compare with figures 6 and 11. The purpose of this drawing is to show the relation of the musculus proprius of the ducts to the gaps in the intestinal muscle. H^1, hiatus in longitudinal muscle (T. musc., long.) for passage of accessory pancreatic duct (D. acc.); H^2, hiatus for passage of ductus pancreaticus (D. panc.) and choledochus (D. ch.). Note that this hiatus is a lengthwise slit and that above, it blends with H^1. It is filled with pancreatic alveoli (see fig. 13) which the longitudinal muscle partially encloses (see 'F' fib., fig. 13).

By contrast, the fissure in the circular muscle (T. musc., circ.) is transversely placed—note its upper and lower margins (Margo sup. and inf.). Within this window (fen. ch.) lies the musculus proprius of the ducts, placed like the iris within the slit of the eye. The 'corners of the eye' contain blood vessels, nerves and pancreatic alveoli and certain offshoots of the intestinal muscle (compare fig. 4). At other places, blood vessels enter through special foramina (For.). The asterisk indicates the longitudinal 'X' and 'K' fibers of Hendrickson (see asterisk, fig. 14).

10 Drawing of longitudinal section of model shown in figure 9, seen from posterior side. × 40. The section is made parallel to the ducts, therefore oblique to the intestinal wall. For orientation in body, compare with figure 6. Locate first, the margins of the window in the tunica muscularis (Margo inf. and sup.). Then observe the musculus proprius, the most conspicuous parts of which are the circular fibers on the mucosal side of the bile duct, extending from above the margo superior down to the point where the ducts unite to form the ampulla of Vater. On the muscle side of the pancreatic duct note the cut ends of its musculus proprius. Between the two ducts are located fibers of the sphincter choledochus; the upper ones represent the definitive sphincter choledochus superior; the lower ones, scattered components of the future sphincter choledochus inferior. Valv., folds that will form valvules to guard orifice of ampulla; T. muc., base of mucosa, somewhat diagrammatically rendered, after cutting off projecting villi; A, B, C, D, E and F, levels of sections shown in plates 3 and 4.

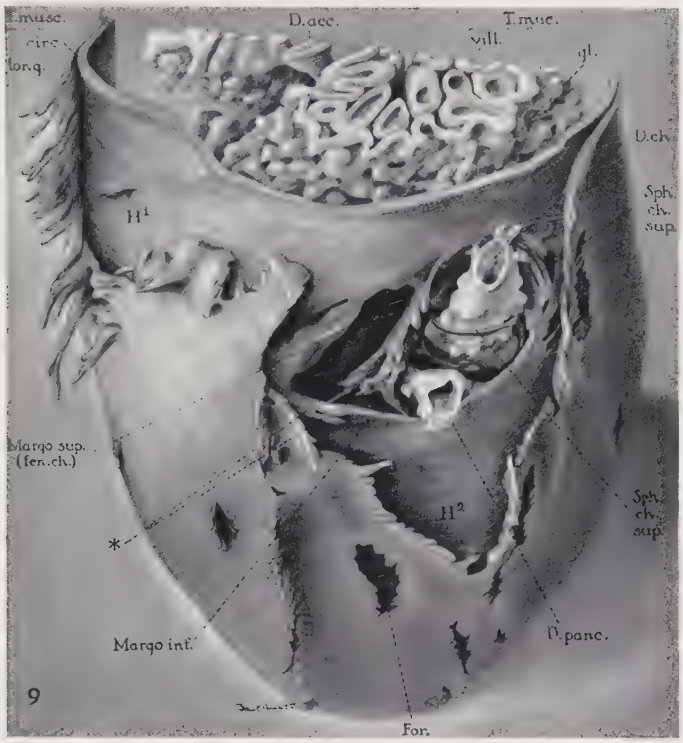
T.musc.
circ.
long.
D.acc.
T.muc.
vill.
gl.
D.ch.
Sph.
ch.
sup.
H1
Margo sup.
(fen.ch.)
*
H2
Sph.
ch.
sup.
Margo inf.
D.panc.
9
For.

Sph.ch.sup.
D.ch.
Margo sup.
D.panc.
Margo inf.(fen.ch.)
←A
←B
Musc. propr.
junct.
←C
D →
Musc. propr.
Tun. musc.
circ.
long.
←E
F →
Amp.Vat.
Valv.
T.muc. (base of villi)
Gl.
Ost.pap.
10
Gl.

PLATE 3

EXPLANATION OF FIGURES

11 Transverse section through pars descendens of the 115-mm. fetus that is figured in plate 2. Low power view of level A (fig. 10). × 12. For orientation in body, compare with figure 6. A higher power of the same section is shown in figure 12.

12 Higher power view of level A (fig. 10). Section 657. × 80. Both bile and pancreatic ducts lie outside the duodenum, but in the next section they will begin to descend into the submucosa (T. submuc.) through a gap in the circular muscle (T. musc. circ.). This is therefore the lowest section through the margo superior of the choledochal fenestra (compare fig. 9). Note that while the muscle fibers around the bile duct (D. ch.) are in contact with the intestinal muscle, they constitute an independent ring, the sphincter choledochus superior (Sph. ch.). Also observe that laterally the longitudinal muscle of the gut (the so-called 'F' fibers of Hendrickson) tries to envelop the pancreatic alveoli (Panc.) and the bile duct, instead of adhering to the circular muscle throughout. 'K' fib., longitudinal strands of sphincter choledochus; Gl., glands of mucous membrane of duodenum.

13 Transverse section at level B (fig. 10). Section 667. × 80. This passes through the choledochal fenestra at nearly its widest extent. Margo lat., the two corners of the eye-shaped window in the intestinal muscle. The section just skims the top of the thin inferior margin of the window (Margo inf.). Note penetration of window by pancreatic alveoli and blood vessels. 'K' fib., longitudinal offshoots of musculus proprius; 'X' fib., isolated strands of smooth muscle leaving margin of window to insert, lower down, into sheath that invests the ducts; musc. propr., the portion of the investing sheath which Porsio calls "the left head of the interrupted intestinal muscle." For earlier stage in its differentiation from mesenchyma, see figure 1. Note deeply staining muscle band between bile and pancreatic ducts, also younger fibers, around bile duct, in process of differentiation.

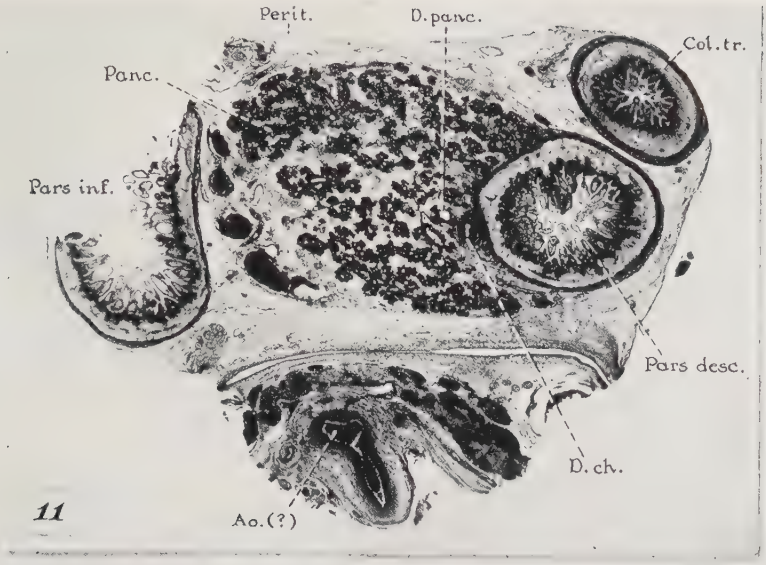
Perit.
D. panc.
Col. tr.
Panc.
Pars inf.
Pars desc.
D. ch.
Ao. (?)
11

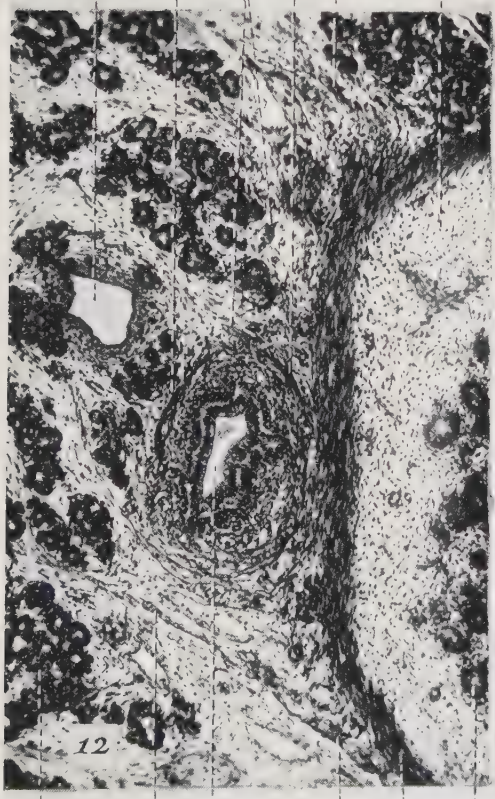
Sph. ch.
X^2
Sph. ch.
D. panc.
"K" fib.
"F" fib.
T. submuc.
12
"F" fib.
long.
circ.
Panc.
D. ch.
T. musc.
Gl.

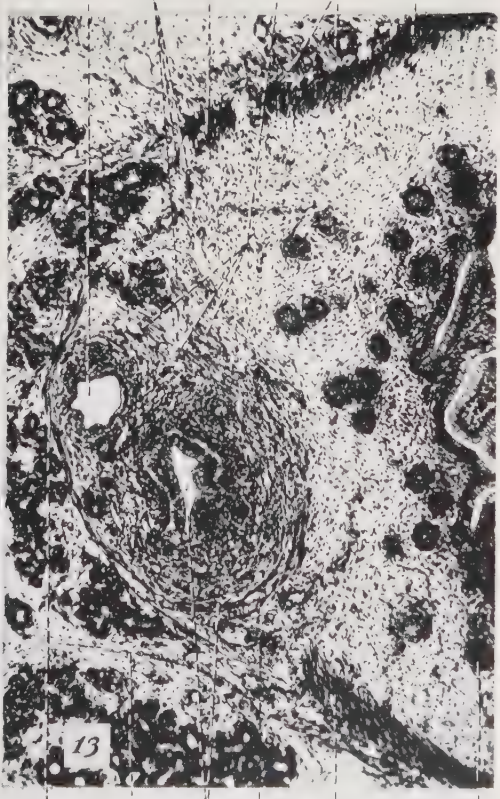
D. panc.
Margo lat.
T. musc.
X^2 fib.
"K" fib.
long.
circ.
13
Margo inf.
D. ch. e musc. prop.
Gl.
"F" fib.
X^1
Margo lat.

PLATE 4

EXPLANATION OF FIGURES

14 Section at level C, figure 10. Section 683. × 80. Asterisk designates those offshoots of musculus proprius ('X' and 'K' fibers of Hendrickson) that are indicated by an asterisk in figure 9. Note that the bile and pancreatic ducts now lie in the submucosa and that the mesenchyma between the pancreatic duct and the margo inferior is differentiating into muscle. Note denseness of mesenchyma between bile and pancreatic ducts. This is the site of formation of the future sphincter choledochus inferior.

15 Section at level D, figure 10. Section 703, × 80, i.e., through junction of bile and pancreatic ducts and upper end of plica longitudinalis. Note that the musculus proprius of the pancreatic duct is beginning to lose contact with the tunica muscularis.

16 Section at level E, figure 10. Section 722. × 80, i.e., through the upper end of the ampulla. Differentiation of the musculus proprius has extended only a short distance beyond this level.

17 Section at level F, figure 10. Section 743, × 80, i.e., through the middle of ampulla which is now wholly within the plica longitudinalis. Note that the ampulla is surrounded by undifferentiated mesenchyma and that the hiatus in the longitudinal muscle of the intestine is now closed.

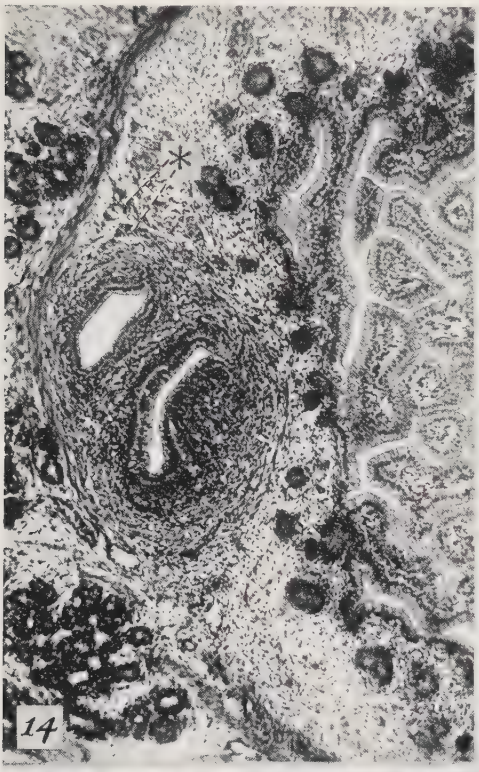
14

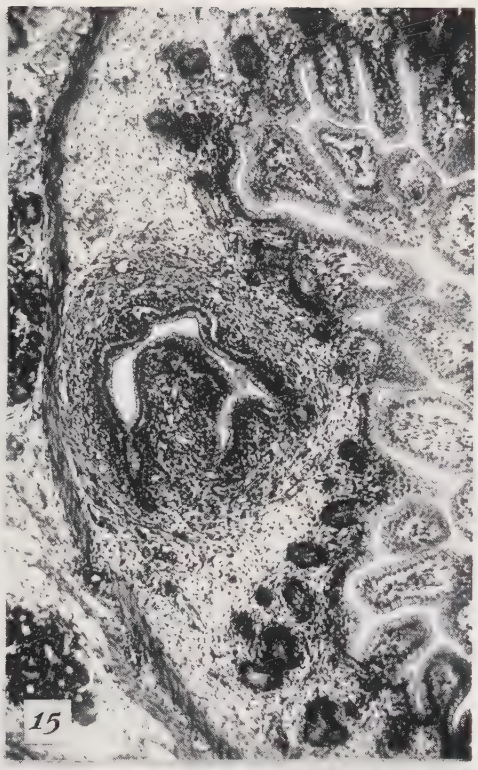
15

16

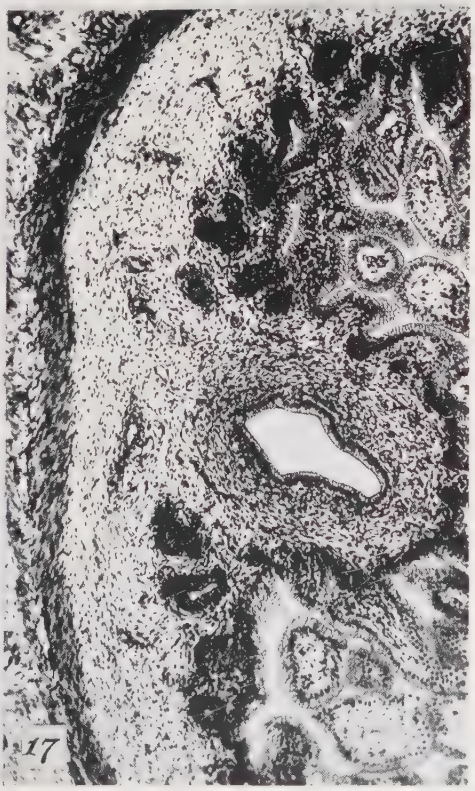
17

STUDIES ON THE INNERVATION OF THE REPRODUCTIVE ORGANS OF MACACUS RHESUS

LAWRENCE R. WHARTON

Department of Gynecology, Johns Hopkins University and Hospital, and Department of Embryology, Carnegie Institution of Washington

SEVEN FIGURES

During the past 4 or 5 years, while studying the innervation of the human ureter, the writer has frequently had glimpses of the rich plexus of ganglia and nerves in the pelvis and has wondered to what extent the function of the female reproductive organs might be subserved by the nervous system.

This is not entirely a new problem, for it was discussed 35 years ago by Sherrington. Since then, however, the hormones have more or less monopolized investigative efforts and very little sustained work has been expended on this phase of the subject. Indeed two recent articles have taken the position that the functions of the reproductive apparatus are independent of the nervous system. For instance, Kaminister and Reynolds ('35) reported that in the transplanted, denervated uterus of the rabbit, the "myometrical effects of these two hormones (estrin and progestin) are essentially myogenic, the extrinsic and intrinsic innervation being non-essential."

The work of Bard ('34) on the cat is also pertinent. He demonstrated that after the spinal cord had been cut or excised or even after the animal had been decorticated, estrus followed and the animal had orgasm on intercourse. From this, it would appear that such reactions of the reproductive organs may occur independently of the spinal cord and the cerebral cortex.

THE ANATOMICAL RECORD, VOL. 68, NO. 1 AND SUPPLEMENT NO. 1

On the other side of the proposition, we find very little affirmative evidence. It is common knowledge, of course, that stimulation of the hypogastric nerve causes uterine contractions; hence the neuromuscular mechanism must be present. The work of Van Wagenen ('33) is suggestive. At different times in the first half of the menstrual cycle, she transected the spinal cords of seven monkeys (two mangebeys, five Macacus rhesus) in the thoracic region. This operation was followed in all cases by uterine bleeding, after an interval of from 2 to 9 days. The interval between the operation and the bleeding seemed to vary with the location of the transection—the lower the transection the sooner the bleeding appeared. After this period of induced uterine bleeding, the menstrual cycle again became established normally. Transection of the cord did not induce bleeding in a castrated monkey. She found that the uterus and ovaries undergo atrophic changes after cutting the thoracic cord.

Van Wagenen also refers to the work of Buchheim and Zaleskie, who transplanted fragments of uterine horn into the rabbit's ear, and found that cervical sympathectomy intensified the reaction of the transplanted uterine tissue. Contradictory results were obtained by Markee in 1932, who found that the rhythmic changes of endometrium transplanted to the cornea were unaffected by cutting or stimulating the cervical sympathetic chain.

Then, finally, as we shall show, the fact remains that the female reproductive organs receive a very rich innervation from several sources, and we wonder whether this division of the nervous system is functionless. It is apparent, however, that the evidence thus far available is not only very meager, but also tends to be contradictory. On the basis of what we now know, one could not even guess what the answer will be.

With these ideas in view, we began, a year ago, to study the innervation of the reproductive organs of the macaque. We chose the macaque because it is a menstruating mammal, with a menstrual cycle remarkably resembling that of women,

the usual cycle being 27 or 28 days, the duration of menses being 4 to 6 days. Also the macaque has been thoroughly studied with regard to sexual habits and a great deal of experimental work has been done concerning the interrelationships of the endocrine apparatus. Furthermore, in the Carnegie Institute in Baltimore there is a colony of macaques in which the reproductive functions have been recorded for several years. This information gives us a foundation on which to start.

The chief disadvantage offered by the macaque appears to be the configuration of the cervical canal. Instead of being straight, the canal is very tortuous, due to an asymmetrical, localized growth of tissue in the body cervix. This causes a curve in the cervix and makes cervical approach to the uterine cavity very difficult. This fact has been observed by Hartman, and Corner and Engle have recently studied it in detail. We trust that we shall find a way to overcome this handicap.

GENERAL ANATOMICAL OBSERVATIONS

The uterus, uterine tubes and ovaries of the adult macaque closely resemble those of the newborn female infant in general configuration and size. In the macaque, however, the long, caudal flexor muscle is tremendously developed, as it partly controls the function of the tail; in the human, this muscle is not present. The presence of this large muscle in each half of the sacral hollow alters the surgical anatomy of this region. Also the macaque has seven lumbar vertebrae; this affects the numbering of the spinal nerves and the establsihing of anatomical landmarks. Further, it is noteworthy that the prevertebral sympathetic chain sends only five branches to the aortic plexus, there being none below the fifth lumbar verebra. The first sacral vertebra can be distinguished by its broad articulation with the ilium and by the position of the seventh lumbar nerve. The seventh lumbar is the most prominent of the vertebrae in this region.

Gross dissection reveals the general distribution of nerves to the pelvic viscera to be essentially that shown in figures 1 and 2. The former displays the gross relationships of the abdominal sympathetic, parasympathetic and spinal nerves. The posterior peritoneum has been lifted up and reflected toward the right, elevating and showing the posterior surface of the left kidney and ureter, the left ovarian vein and the aortic plexus of nerves. In the pelvis, one sees the uterus, the right tube and ovary and the bladder.

The aortic plexus (g) is connected with the central nervous system by the semilunar ganglia (b) and other ganglia in the celiac plexus, the splanchnic nerves (c), the communicating branches that connect it with the prevertebral ganglia in the sympathetic chain on each side (e). Below the fifth lumbar, there are no communicating rami between the aortic plexus and the prevertebral ganglionated chain. The aortic plexus continues in the pelvis as the hypogastric nerves (presacral), terminating in the ganglia of the pelvic plexus (o).

The chain of sympathetic ganglia (e) also sends branches to the spinal nerves.

The sacral autonomic nerves (m) lie deep in the pelvis, below the superior gluteal artery. There are five sacral nerves on each side. The long, caudal flexor muscles cover the sacral foramina and the sacral nerves pass laterally after leaving the sacral foramina to emerge from the lateral margins of these muscles.

There is considerable variation in the arrangement and distribution of the sacral nerves; in the same individual we have observed differences between the right and left sides. We shall describe the arrangement which we have found most frequently.

The sacral nerves and sympathetic chain. The upper four sacral nerves have direct connections with the ganglia of the sympathetic chain. The first sacral receives a particularly large branch from the sympathetic chain, and this connecting branch becomes progressively smaller with the second, third and fourth sacral nerves. The connecting branch between

the fifth sacral and this chain is variable, very fine and not always present. Because of these connections, the parasympathetic sacral nerves probably contain sympathetic elements.

The superior gluteal artery and vein (figs. 1 and 7). One very constant and important anatomical landmark is the superior gluteal artery. This arises from the lower border of the internal iliac, shortly after the bifurcation of the common iliac. The superior gluteal artery and vein pass medially and downward, hugging the pelvic wall. They pass over the sixth and seventh lumbar nerves at the pelvic brim. They then pass under and behind the sacral nerves, thus cleanly separating the lumbar from the parasympathetic nerve trunks. This is an important guide in this region.

First sacral nerve (fig. 1). This is a large structure, about one-third as thick as the seventh lumbar nerve. In figure 1, we have shown in detail the usual course of this nerve. Just after emerging from the first sacral foramen, it receives one or two branches from the large proximal ganglia of the sympathetic chain. About 3 or 4 mm. from the foramen, it divides into two main branches. The upper and larger branch continues along the pelvic wall for about 1.5 cm., when it joins the large trunk composed of the sixth and seventh lumbar nerves, to form the lumbo-sacral nerve trunk. There are variations in the number of connections between the seventh lumbar and the first sacral. The superior gluteal artery and vein pass between the seventh lumbar and the first sacral nerves.

The lower division of the first sacral has the following branches:

A, to muscles of pelvic floor (pubococcygeus).

B, to pelvic plexus.

C, to upper division of first sacral.

D, to second sacral nerve.

E, to upper division of first sacral.

F, large terminal branch which unites with a branch of second sacral, to form the pudic nerve.

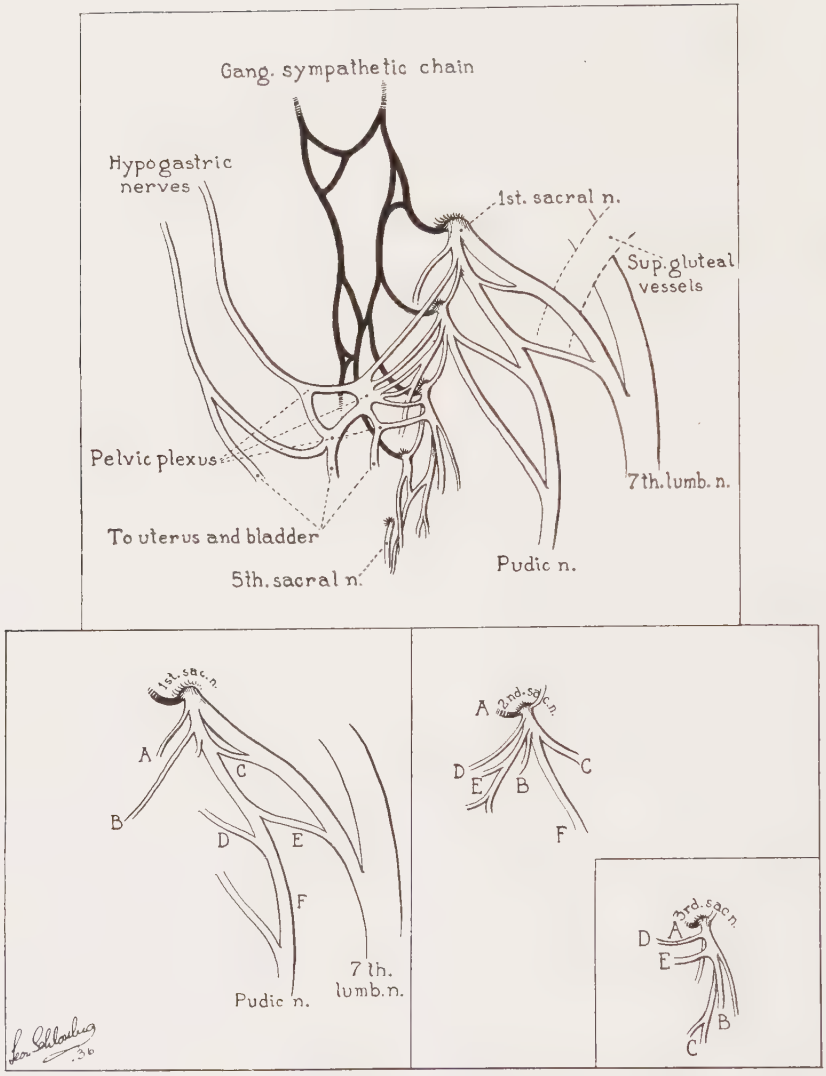

Fig. 1 Detailed dissection of sacral nerves. In the top drawing, one sees the sacral nerves in relation to the ganglionated sympathetic chain, the pelvic plexus, and the seventh lumbar nerve. Branches from the first and second sacral nerves usually form the pudic nerve. The superior gluteal artery passes over the seventh lumbar nerve and under the first sacral and is an important surgical landmark. The first, second and third sacral nerves are illustrated separately.

Second sacral nerve. This is not quite as large as the first sacral. It has the following branches and connections:

A, to the second ganglion of sympathetic.
B, to the root of third sacral chain.
C, to the second division of first sacral, forming pudic nerve.
D, to pelvic plexus.
E, to pelvic plexus.
F, terminal branch uniting with second division of first sacral, to form pudic nerve.

Branch E may be double, or divide after leaving the main nerve. It usually gives off branches to the muscles of pelvic floor before reaching the pelvic plexus. They enter the pelvic plexus lower and median to the nerve from the first sacral.

Third sacral nerve. This is also a large nerve, nine-tenths of which goes to the muscles of the tail the rest to the pelvic plexus. It has the following branches:

A, to the sympathetic ganglionated chain, which is very fine here. The lowest ganglion visible to the naked eye is usually opposite the second sacral foramen. Branches of the third sacral are as follows:

A, receives a small, very fine branch from the chain of sympathetic ganglia. The ganglionated chain is very fine here.

B, a large branch, more than three-quarters of the nerve accompanied by a fine branch.

C, which passes down toward the tail. On their way, they supply some fibers to the long, caudal flexor muscle. Branches B and C run toward the dorsum of the tail.

D and E, these are nerves of medium size which pass to the pelvic plexus. They may unite with the lowest branch of the second sacral (E) before entering plexus.

Fourth sacral nerve. This is a fairly large nerve almost all of which goes directly to the tail and the long, caudal flexor muscle. It may receive a fine branch from the prevertebral sympathetic chain, and has a connecting branch with the third sacral. A very fine and inconstant branch from the fourth sacral may unite with a similar branch from the third sacral, passing together to the long, caudal flexor muscle and tail. If the fourth sacral nerve sends any branches to the pelvic plexus, they are very fine and inconstant.

Fifth sacral nerve. This nerve passes directly to the tail. We have found no connection between the fifth sacral and the

pelvic plexus. Also, if it receives any contribution from the sympathetic chain, it is inconstant and very small. The fifth sacral nerve emerges just at the edge of the dense fascial band which envelops the coccyx and which forms the fascial attachment of muscles in that region.

The pudic nerve (fig. 2). This nerve receives separate consideration because of its distinct course. The pudic is composed of branches from the first and second sacral nerves, and at times the seventh lumbar. It runs below the trunk made up of the sixth and seventh lumbar nerves, and branches from the first and second sacral contribute to this lumbar trunk. In most of our specimens, the seventh lumbar sent no branch to

---

Fig. 2 Gross dissection, Macacus rhesus. Posterior abdominal wall and pelvis; left half of posterior peritoneum lifted up, exposing retroperitoneal structures as labelled. Left kidney and ureter have been mobilized and lifted up with peritoneum. One can trace the left ureter into the bladder. The right half of the uterus, right fallopian tube and right ovary seen.

a, adrenal gland
b, semilunar ganglion
c, superior splanchnic n.
d, middle splanchnic n.
e, sympathetic ganglionated chain
f, first lumbar n.
g, aortic plexus
h, genito-crural n.
i, ureter
j, external cutaneous n.
k, hypogastric (presacral) nerves
l, seventh lumbar n.
m, first sacral n.
n, anterior crural n.
o, pelvic plexus
p, pudic n.

The dissection shows the gross features and relationships of the abdominal sympathetic nervous system and the sacral autonomic (parasympathetic) system. In the upper part of the picture, one sees the splanchnic nerves, entering the semilunar ganglion, and sending nerves to the adrenal gland and kidney. From this and other ganglia in the coeliac plexus (not shown in the drawing), the aortic plexus arises, shown as fine white lines, under the peritoneum, running down into the pelvis to enter the pelvic plexus. Beginning below D, one traces the sympathetic ganglionated chain, running along the vertebral column into the pelvis. From the upper five ganglia in this chain, branches pass to the aortic plexus. In the pelvis, these ganglia send branches to the roots of the sacral parasympathetic nerves.

The sacral nerves are seen, commencing at M, sending branches to the pelvic plexus medially. From the first and second sacral nerves and the seventh lumbar at times, branches unite to form the pudic nerve which can be traced to the base of bladder, urethra, vagina and rectum. Numerous branches pass from the sacral nerves to the muscles of the pelvic floor. Figure 1 illustrates the sacral nerves in detail.

BOSTON MEDICAL
OCT 31
LIBRARY

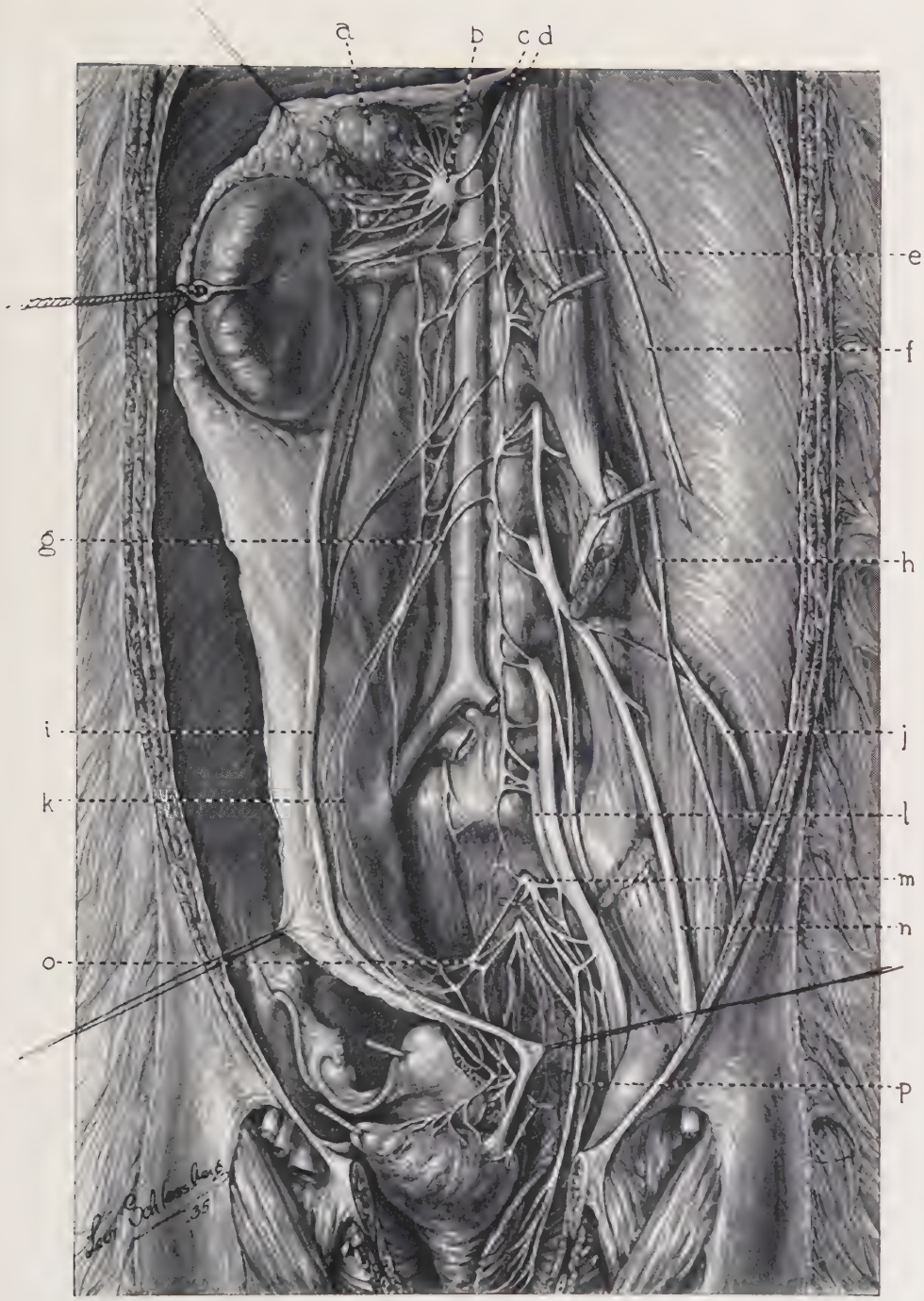

Figure 2

the pudic. In one specimen, on the contrary, the pudic was made exclusively of the first sacral and the seventh lumbar, having no connection with the second sacral. In this case, the pudic accompanied the sixth and seventh lumbar nerves and almost became incorporated in them, leaving them deep in the pelvis and, finally, accompanied by the pudic artery and vein, reached the usual termination. We have seen no instance in which the pudic received any contribution from the third sacral.

The pudic sweeps around the pelvis, a rather large nerve trunk. It divides as soon as it reaches the lateral wall of the rectum, sending branches to the rectum, vagina, urethra and base of the bladder, terminating in these structures.

In the macaque, it is thus evident that the pudic innervation of the rectum, urethra, lower vagina and base of the bladder seems to be entirely independent of the pelvic plexus which will be described in detail in the following pages. It is also clear that one can cut the sacral and sympathetic connections of the pelvic plexus without injuring the pudic nerve. This may be of value in experimental analysis of the function of these nerves.

The lumbar nerves and the pelvic plexus. As a rule, the seventh lumbar sends no branch to the pelvic plexus. Occasionally, a fine filament passes directly from the seventh lumbar to the pelvic plexus. We present a photomicrograph of this connection (fig. 6).

FINER DISTRIBUTION OF NERVES AS OBSERVED BY SPECIAL MICRO-DISSECTION METHODS

Having ascertained the gross relationships, the same situation arose as in the writer's earlier study of the innervation of the ureter; smaller nerves could not be identified unless they were stained. Accordingly, the gross anatomical study was supplemented, using the technique that proved satisfactory before and which is described in the preceding issue of this journal.

The gross specimen (fig. 3). The legend and labels explain this dissection. The finer anatomical relations are best brought out, of course, by actual study of the specimen under a dissecting microscope. We have tried to show some of these points by reproducing parts of this dissection at higher magnification.

The aortic plexus is the center of this neural mechanism, for the genito-urinary organs receive their sympathetic innervation largely through this nerve plexus. From it the kidneys receive a rich innervation (fig. 4, block A); in ganglia which I have chosen to call ovarian ganglia (fig. 4, blocks B and C) a group of fairly large nerves arise, passing to each ovary and accompanying the ovarian pedicle. Before reaching the pelvis, the aortic plexus divides into the two hypogastric (presacral) nerve trunks (fig. 4, block D), at the same time giving off the plexus which accompanies the inferior mesenteric artery to the terminal portion of the large intestine. From the hypogastric nerves, branches pass directly to the ureters. Small ganglia are found on these branches to the ureters. The hypogastric nerves continue into the pelvic plexus (fig. 4, block F). Most of these features are shown in higher magnification in figure 5. Ganglia and nerve cells are found all along the course of the hypogastric nerves.

The sacral autonomic nerves. The sacral autonomic nerves look far more complicated than they did in the gross dissection shown in figure 2. In figure 4, we show only the branches of the sacral nerves which go to the pelvic plexus. Like the hypogastric nerves, the sacral branches plunge into the intricate network of nerves and ganglia of the pelvic plexus. From this plexus, innumerable fibers spread out over the wall of the vagina and cervix (fig. 4, block F), thence passing to the body of the uterus.

Kuntz has just completed an analysis of the pelvic plexus by degeneration methods. After cutting the hypogastric and sacral nerves in the cat, he traced the subsequent degenerative changes, reaching the conclusion that there are three types of ganglia in the pelvic plexus—sympathetic, parasympathetic

and mixed. This would seem to be a reasonable conclusion, on the basis of our dissections.

THE OVARIAN INNERVATION

It would be extremely difficult to dissect the ovarian innervation guided only by the naked eye. Under slight magnification, and using a stained specimen, however, one can analyze the situation very clearly.

The ovarian nerves arise in one or more ganglia (fig. 4, blocks B and C, fig. 5, blocks B and C) which lie in the aortic plexus, near the point of origin of the ovarian artery. From these ganglia four or five fairly large nerves unite with the artery and vein to form the ovarian pedicle. Just before entering the substance of the ovary, they divide into many smaller filaments (fig. 4, block E; fig. 5, block E). The dissections show one pedicle intact, including the artery and vein. The other nerve pedicle has been stripped leaving only an occasional vessel in the upper part, and no vessels at all near the ovary (fig. 5, block E). A lymph gland is shown among the nerves just above this ovary.

The author is continuing to study the innervation of the ovary, especially in human beings, and expects to give a more detailed report on this later.

Fig. 3 Untouched photograph of dissection of genito-urinary apparatus of female macacus rhesus. The dissection was made by technique we describe in accompanying article. The bladder (bl.), vagina (vag.) and uterus (ut.) have been divided in the middle, to enable one to see the underlying pelvic plexus and the sacral parasympathetic nerves. The round ligament orients one. Observe that the innervation of the uterus is derived from the pelvic plexus, and that this innervation reaches the vagina and cervix first, and from these organs passes to the uterus. This intrinsic neuromuscular arrangement has not yet been worked out.

Note the rich innervation of the ovaries, derived directly from ganglia in the aortic plexus, situated near the origin of the ovarian arteries. The innervation of the ureters and bladder has been sacrificed in this dissection, to make the innervation of the reproductive organs clearer.

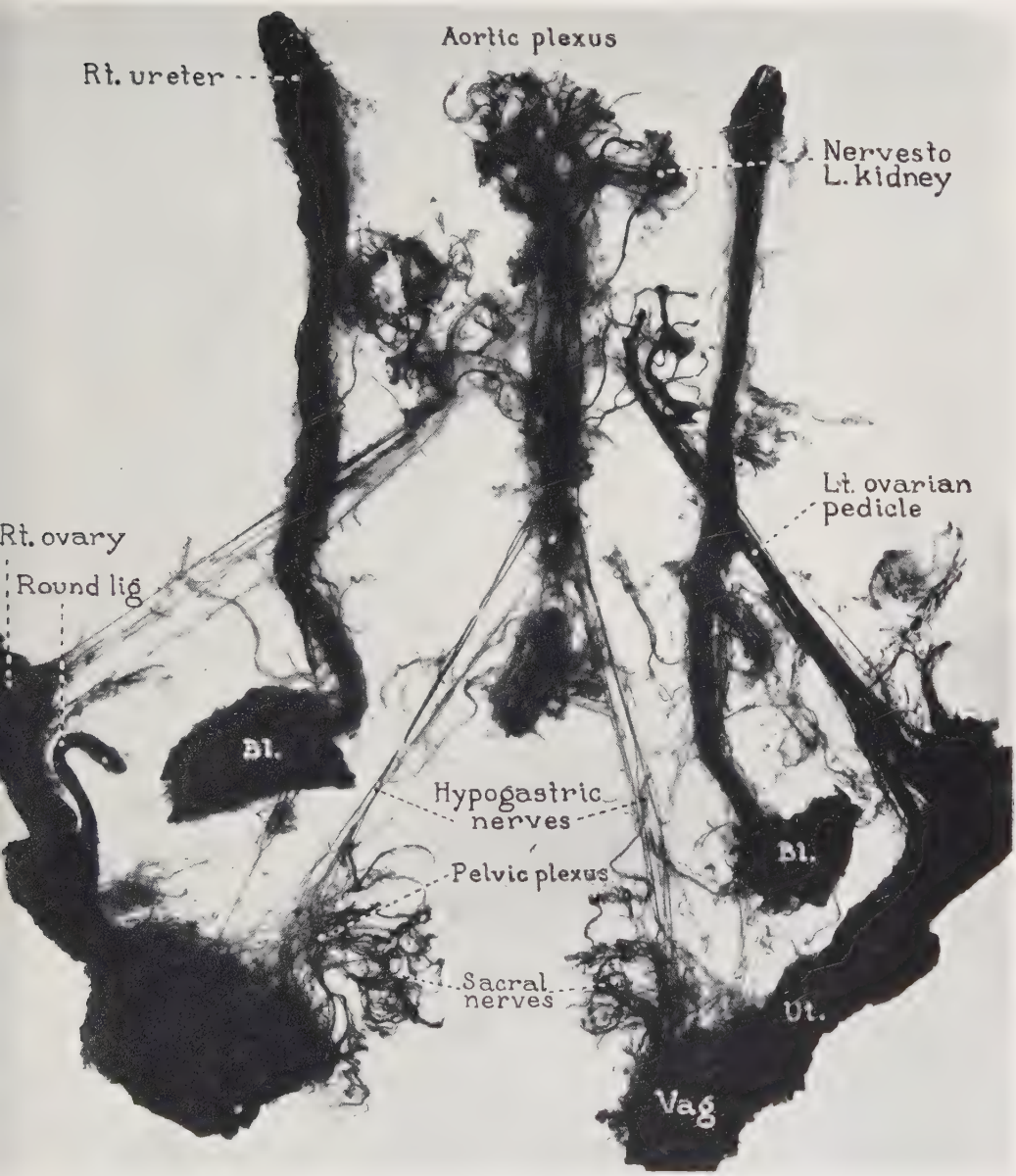
Aortic plexus
Rt. ureter
Nerves to
L. kidney
Lt. ovarian
pedicle
Rt. ovary
Round lig
Bl.
Hypogastric
nerves
Pelvic plexus
Bl.
Sacral
nerves
Ut.
Vag

Figure 3

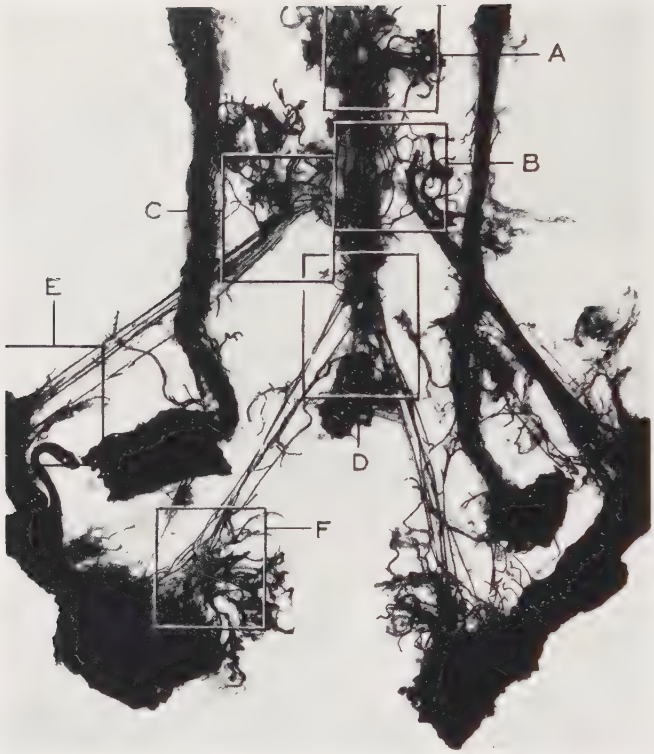

Fig. 4 The same dissection as figure 3, blocked off as a guide for study of subsequent photographs. Figure 5 shows these blocks in higher magnification.

Fig. 5 Parts of the dissection shown in figures 3 and 4, slightly magnified. Block A, the innervation of the left renal pedicle; block A shows a hole in the right extreme end of the pedicle left by a pin, used to hold the tissue for dissection. Block B, shows on the left margin, the dense aortic plexus. Near the center of the picture, a large and a small ganglion, the ovarian ganglia, sending branches to the ovarian pedicle. Along the right margin, the large sympathetic ganglionated chain (prevertebral chain), with communications to the aortic plexus. Block C, the right ovarian pedicle, with most of the blood vessels dissected out, leaving chiefly nerves. The origin of these nerves in the ovarian ganglia and the aortic plexus is shown. Block D, the lower end of the aortic plexus, where it divides into the hypogastric (presacral) nerves. Between these, are seen the nerves that pass with the inferior mesenteric artery. One sees that there are several large nerve trunks in each presacral group. Block E, the ovarian nerves just as they enter the ovary. The round ligament is seen curled up near the ovary. Block F, the pelvic plexus, the meeting place of the sympathetic (hypogastric, presacral) and parasympathetic nerves (sacral). Many large and small ganglia are found in the plexus. Ganglia are also situated along the sympathetic nerve trunks, particularly at points of division or union. Branches from the plexus pass directly to the bladder, the vagina and cervix, and thus reach the body of the uterus.

Figure 5

The innervation of the urinary organs

I have made no attempt to preserve this innervation in these dissections; I have already described elsewhere the innervation of the human ureter. As a landmark in this dissection, however, one can see the innervation of the left renal pedicle (fig. 4, block A; fig. 5, block A). Also one can see a few nerves passing to the left ureter (fig. 4, below block D) and from the pelvic plexus on each side, several nerves pass to the base of the bladder (fig. 4).

SURGICAL APPROACH TO THE PELVIC NERVES

For experimental purposes, the surgical approach must be simple and should not compromise any other structure. Fortunately, I am sure that the pelvic nerves of the macaque can be isolated with a directness which makes experimental surgery quite easy. In figure 7, I illustrate the operative technique.

Fig. 6 A high power photograph of a nerve, the existence of which was not definitely known before. It passes directly from the seventh lumbar nerve to the pelvic plexus. It is very fine and was entirely missed in the dissection shown in figure 1. Doctor Bard asked whether there was such a connection in the macaque, and more careful dissections revealed its presence. Methylene blue stain.

Fig. 7 The surgical approach to the sacral autonomic nerves in Macacus rhesus. A midline suprapubic incision is made. This dissection shows the left sacral nerves. For experimental purposes, one must be able to expose the sacral nerves without injuring any other significant nerves or blood vessels or any important structures.

The large intestine is rolled medially, exposing the posterior peritoneum. A clear space is found, laterally to the ureter and the ovarian pedicle. The peritoneum is incised at this point, over the white tendon of the psoas muscle, and the peritoneum mobilized, carrying the ureter and ovarian vessels with the peritoneum. These structures are seen adherent to the under surface of the reflected peritoneum in the illustration.

This dissection exposes the internal iliac vessels. The superior gluteal artery is then found. It crosses the seventh lumbar nerve, and passes under the first sacral. Medially to the first sacral, one can see the edge of the long, caudal flexor muscle. The sacral nerves come out from under the lateral edge of this large muscle. The reflected peritoneum will probably carry with it the hypogastric nerves and pelvic plexus. Branches from the sacral nerves can be easily isolated and traced to the pelvic plexus and the sacral nerves and hypogastric nerves dissected at will.

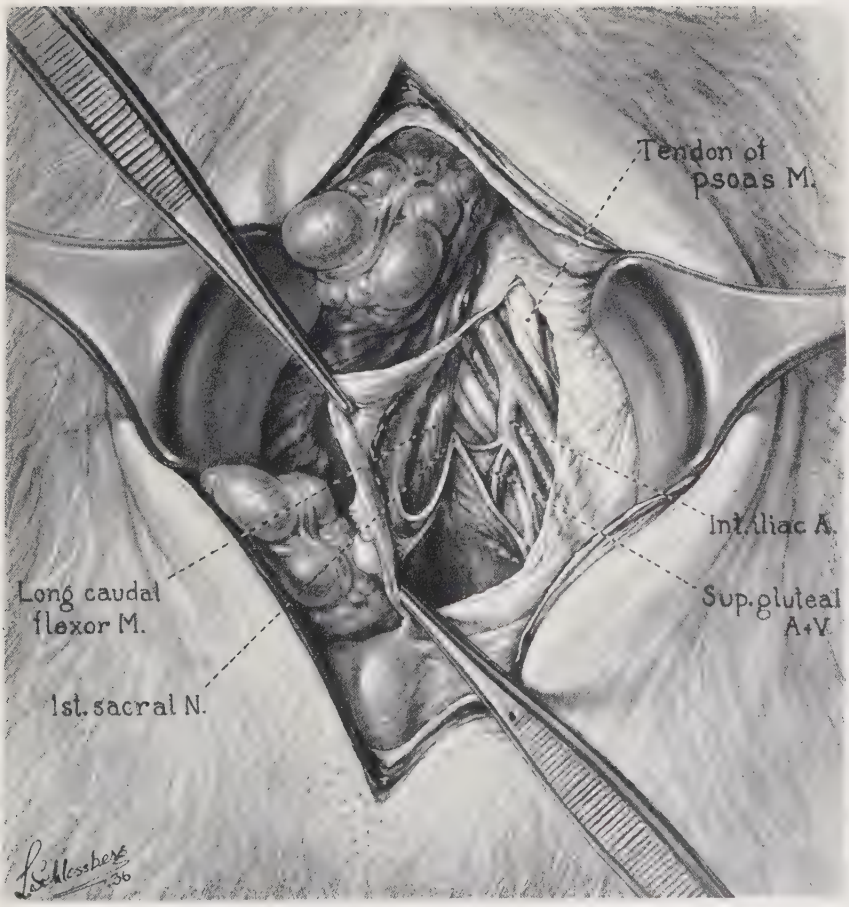

Figures 6 and 7

It is apparent from these dissections, that one can easily separate the pelvic nerves in the female macacus rhesus, and deprive the uterus, tubes and vagina of their sacral or sympathetic nerve supply. Apparently this can be done without interfering with the pudic nerve, which is said to control the sphincters of the urethra and rectum.

The writer is suggesting this approach to the pelvic nerves and this method of analyzing their function purely on the basis of the anatomical studies he has done. The operation itself would be very simple and quick, not comparing in gravity with spinal transection, cordotomy, excision of spinal cord, decortication, denervation and transplantation of uterus, which are the operative procedures usually employed in studying the effect of denervation on the reproductive organs. Also, the procedure I suggest would not interfere with the function of the bladder and rectum and would cause no muscular paralysis of the extremities. It should not interfere with the health and general function of the animal.

The author is not offering this short anatomical study as a finished piece of work. He realizes that he has outlined only the gross features and that the finer histological details of this neural apparatus should be investigated.

CONCLUSIONS

The writer has presented the results of his anatomical study of the innervation of the reproductive organs of the female Macacus rhesus. These dissections were made, first, in the usual manner using fresh tissue, and then supplemented by special micro-analytical methods which enable one to study finer structures in tissue that had been permanently preserved and stained. This technique is described in the preceding issue of this journal.

On the basis of these dissections, it would seem that the innervation of the female macaque can be exposed and readily divided into its sacral and sympathetic elements and that these elements can be reached surgically by a direct and simple approach. It also seems that the innervation of the uterus,

tubes and vagina can be severed without affecting the innervation of the rectum or bladder. The ovarian innervation is described. To the writer it would seem difficult to predicate the functions of the various components of the innervation of the reproductive organs, until physiological analysis of this sort has been done. This also opens up the opportunity for various pharmacological studies of these same nerve pathways.

LITERATURE CITED

Bard, Philip 1934 Emotion. The neuro-humoral basis of emotional reactions. A Handbook of General Experimental Psychology, Chapter 6. Worcester, Mass. Clark University Press.

Clark, O. H. and George W. Corner 1935 The cervix uteri of the rhesus monkey. Anat. Rec., vol.63, p. 247.

Engle, E. 1932 Method of obtaining curettings from uterine mucosa of Macacus monkeys. Proc. Soc. Exp. Biol. and Med., vol. 29, p. 447.

Hartman, Carl G. and William L. Straus, Jr. 1933 The anatomy of the rhesus monkey (Macaca mulatta). The Williams and Wilkins Co. 383 pp.

Kaminister, Sanford and S. R. M. Reynolds 1935 Motility in the transplanted, denervated uterus. Am. J. Obst. and Gyn., vol. 30, p. 395.

Van Wagenen, G. 1933 Uterine bleeding of monkeys in relation to neural and vascular processes. Am. J. Phys., vol. 105, p. 2.

Wharton, Lawrence R. 1932 The innervation of the ureter, with respect to denervation. J. Urol., vol. 28, pp. 639–673.

DECREASE IN NUMBER OF MYELINATED FIBERS IN HUMAN SPINAL ROOTS WITH AGE

KENDALL B. CORBIN AND ERNEST D. GARDNER
Department of Anatomy, Stanford University

SIX FIGURES

Pearson ('28) reported a slight decrease in vibratory sensibility in persons over 30 years of age, which, as he said, becomes particularly striking after the age of 50. Pearson believed that "the most probable location for the pathologic changes underlying this decrease is the posterior columns of the spinal cord." He stated that the lesion was probably vascular. Using what they believe to be a more exact and more objective method of determining vibratory acuity, Newman and Corbin ('36) found a similar diminution in this sensibility with age.

Duncan ('30) reported the presence of less than 1% of degenerating fibers in normal nerves of the rat, rabbit, cat and man. He recently ('34) determined the number of fibers in the ventral roots of the rat at different ages. He found a decrease in the number of ventral root fibers in the old rats, up to one-tenth of the total number at 800 days. He concluded that the degenerating fibers, observed in normal nerves at all ages, are not replaced as claimed by Agduhr ('20).

We have made this study to determine the source of the decreased peripheral sensibility, with age. We realize that our series is not large but believe the results are significant enough to warrant this report.

MATERIALS AND METHODS

In most cases the nerve roots were removed from human bodies used for dissection. These bodies had been embalmed

with a mixture of formalin, phenol, glycerine, alcohol and water, but the 1-day-old infant with 10% formalin alone. The 19-year-old suicide case was autopsied soon after death and the 8th and 9th thoracic roots placed in 10% formalin. In no case was there evidence of gross pathology of the meninges, spinal cord, or nerve roots. The recorded causes of death are listed in table 1.

The 8th and 9th thoracic dorsal and ventral roots were selected for this study because they contain fewer myelinated fibers than other spinal roots, and their fiber content is less apt to vary through pre- and post-fixation of the plexuses which occur in the cervical and lumbosacral regions (Sherrington, 1894). A 1 cm. long segment of each root was removed on the right side. They were washed in running water for 24 hours, then placed in Müller's fluid for 4 days. The 8th thoracic dorsal roots were dehydrated in alcohol and embedded in celloidin, but the remaining roots were dehydrated in dioxan and embedded in paraffin. Osmic acid and Weigert's stain were tried without success. We found Mallory's mixture of anilin blue and orange G the best. The endoneurium stains blue, and the myelin, when present, a light orange. Each myelinated fiber is clearly delineated by its collagenous endoneural sheath. Figures 1 and 2 illustrate the microscopic appearance of sections 10 μ thick. Figure 1 is a low power ($\times$ 165) photomicrograph of the 8th thoracic ventral root from case 770, a 69-year-old female. Figure 2 is a photomicrograph under higher magnification ($\times$ 1130) of the 9th thoracic dorsal root of case 769, a 26-year-old man.

Counting was done with a micrometer (100 squares, 5 $\times$ 5 sq.mm.) under one ocular of a binocular microscope, equipped with 10 x oculars, and a 4-mm. dry objective. A hand tabulator served to record the count. Adjacent fields were counted, care being taken to avoid counting the same fibers twice or to miss some. Recounts made on seven roots gave a percentage difference of 2.4, 2.6, 3.1, 3.3, 3.4, 3.8 and 3.9, or an average percentage difference of 3.2. Two very poor preparations which gave considerable difficulty originally, were recounted

TABLE 1

SERIES NO.	BODY NO.	AGE	CAUSE OF DEATH	8T DR	8T VR	8T DR / 8T VR	9T DR	9T VR	9T DR / 9T VR
1		1 day	Newborn 'blue baby'	4,178	1777	2.35	4,365	1881	2.32
2		♀ 13	Rheumatic fever?	10,031	4620	2.17	12,151	4858	2.50
3		19	Suicide	11,225	7317	1.53	12,451	7304	1.70
4	769	26	Tbc.; epilepsy	11,615	6131	1.89	11,547	6289	1.84
5	773	27	Pulmonary tbc.	10,502	6280	1.67	11,062	6118	1.81
6	776	43	Depressive exhaustion	8,552	5685	1.50	13,840	6258	2.21
7	762	44	Pneumonia; chorea	8,901	5582	1.59	8,951	5069	1.77
8	764	44	Pulmonary tbc.	7,165	5127	1.40	11,014	5134	2.15
9	763	49	Pulmonary tbc.	9,535	5126	1.86	6,825	6025	1.13
10	757	♀ 49	Brain tumor		4310				
11	755	50	Cerebral hemorrhage	7,801	5421	1.44	8,917	5755	1.55
12	771	50	Pulmonary tbc.	*9,057*[1]	5667	1.60	7,328	5305	1.38
13	775	53	Pulmonary tbc.	9,789	5810	1.68	10,697	5670	1.89
14	756	♀ 53	Cerebral hemorrhage	6,048	5051	1.20	8,147	4901	1.66
15	766	55	Pneumonia	6,706	4539	1.45	9,855	5542	1.78
16	768	57	Ca. of oesophagus	5,615					
17	772	57	Ca. of prostate	9,580	6305	1.52	12,674	5936	2.14
18	750	59	Cerebral hemorrhage	7,429	5228	1.42	9,029	5118	1.76
19	784	61	Aortic insufficiency	6,449	3402	1.90	7,116	4647	1.53
20	753	61	Lobar pneumonia	7,679	4494	1.71	5,185	3390	1.52
21	765	63	Buerger's disease	8,492	5399	1.57	8,343	5401	1.54
22	785	64	Unknown	7,306	5255	1.39	6,676	3927	1.70
23	767	65	Pneumonia	7,201	4398	1.64	9,198	4840	1.90
24	748	68	Prostatic obstruction	7,796	5449	1.43	9,710	5537	1.75
25	751	68	Paresis	8,185	4566	1.79	7,822	5579	1.40
26	770	♀ 69	Coronary disease	7,113	4970	1.43	8,831	4388	2.01
27	760	71	Pulmonary tbc.	8,182	*5114*[1]	1.60	8,317	4468	1.86
28	759	71	Unknown	8,309	5158	1.61	9,059	4807	1.88
29	758	72	Cerebral hemorrhage	*6,256*[1]	3910	1.60	8,095	4727	1.71
30	752	75	Portal cirrhosis	5,835	4783	1.21	7,310	4812	1.52
31	749	76	Bronchial pneumonia	*5,475*[1]	3422	1.60	7,050	3571	1.97
32	754	77	Bronchial pneumonia	8,201	4946	1.66	10,543	5836	1.81
33	782	79	Heart failure	6,573	5088	1.29	9,386	5345	1.76
34	781	89	Interstitial nephritis	7,004	3887	1.80	8,971	3960	2.27

[1] Estimated from average of $\frac{8T\ DR}{8T\ VR}$ ratio of 1.6.

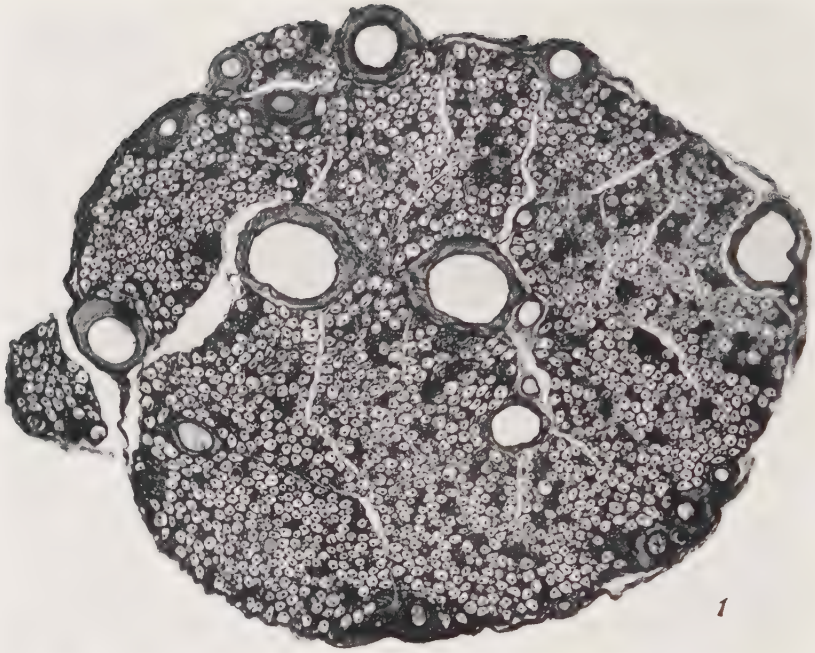

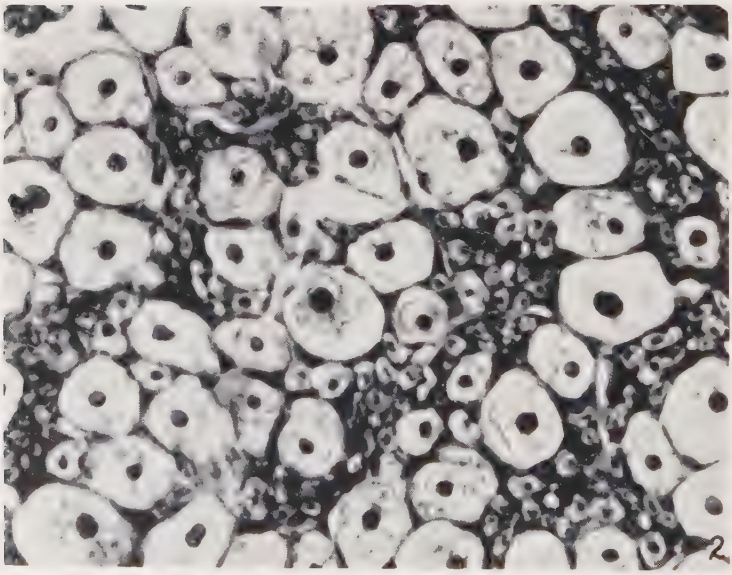

Fig. 1 Case 770. Eighth thoracic ventral root of 69-year-old female. × 165.
Fig. 2 Case 769. Ninth thoracic dorsal root of 26-year-old male. × 1130.

and the new counts showed a percentage decrease of 8.8 and 12.6. These two preparations (case 784, 12.6%; case 782, 8.8%), however, stood alone in being extremely difficult to count because of poor fixation and a marked increase in the amount of connective tissue, which suggests replacement. If the percentage differences of these two cases are averaged with the other seven cases, we obtain an average percentage difference of 4.8.

We have counted the roots of five fetuses but have included only the results obtained from the 1-day-old infant. The fetuses were poorly preserved and the counts were very low. We believe the values recorded for the 1-day-old are accurate and represent a true determination of the number of myelinated fibers found at this time of life.

RESULTS

The roots from individuals over 50 years of age usually contain more connective tissue than those from younger persons. One occasionally sees alterations in the cross sectional appearance of the nerves of the older individuals. The fibers appear shrunken and lose their circular appearance, becoming irregular and distorted.

There is considerable variation in the number of dorsal and ventral root fibers within each decade, as shown in table 1. However, if the counts are represented graphically, as shown in figures 3, 4, 5 and 6, and the decade average is computed, a gradual decline is revealed in the average number of myelinated fibers in the spinal roots after the second or third decade. Table 2 shows the general average for all roots counted in each body for each decade, with the percentage of decrease for each 10-year group. The highest decade average, based on the 13- and the 19-year-old counts, is 8744. This represents an increase of 187% over the 1-day-old infant. It is essentially the same as the 8693 average obtained for the two cases in the third decade. It is unfortunate that we have not yet been able to obtain any specimens in the fourth decade. The 6997 average obtained from the four cases in

the fifth decade is 20% lower than the figure for the 10- to 19-year-old group. There is a further decrease of 1% in the sixth decade (eight cases), another of 11% in the seventh (eight cases), and no change in the eighth (seven cases). The 89-year-old individual showed a 4% decrease as compared with the 60- to 69-year group, and a 32% decrease in the number of myelinated fibers compared with the average for the second decade.

Because of the small number of female bodies, no attempt was made to compare male and female counts. Nor has any

TABLE 2

Average for all roots per decade

	NEW-BORN	10 TO 19	20 TO 29	30 TO 39	40 TO 49	50 TO 59	60 TO 69	70 TO 79	80 TO 89
8T DR	4178	10,628	11,059		8,538	7753	7527	6976	7004
8T VR	1777	5,969	6,206		5,380	5204	4741	4631	3887
9T DR	4365	12,301	11,305		11,235	9164	7860	8537	8971
9T VR	1881	6,081	6,204		5,622	5461	4719	4795	3960
Average for four roots	3050	8,744	8,693		6,997	6947	6213	6235	5955
Per cent of decrease from 10 to 19 age group					20%		29%		32%
Per cent of increase over 1-day-old		187%							

comparison between the number of myelinated fibers and the body weight been made. The weight of the unembalmed cadaver often differs markedly from the actual weight of the individual prior to the onset of his last illness. The plotting of frequency distribution for dorsal root/ventral root ratio in its relation to age or weight has demonstrated no correlation between these attributes.

DISCUSSION

The number of dorsal root fibers in the 13-year-old female closely approximates that in the 19-year-old male. However, the well-developed and muscular male had one and one-half

times as many ventral root fibers as the rather slight female. Assuming that myelination was complete in both individuals, it appears that there is much greater agreement between the number of dorsal than ventral root fibers in these two bodies. This may be due to a close relationship between the number of ventral root fibers and muscular development, Agduhr ('17) reported an increase in the number of dorsal and ventral root fibers in kittens subjected to regulated exercise. But, counts including the unmyelinated fibers might alter this conclusion.

Determinations of the number of myelinated fibers in the dorsal human spinal roots were made by Ingbert ('03). Arnell ('33) and Davenport and Bothe ('34) counted unmyelinated as well as myelinated fibers in dorsal and ventral roots, but these workers did not correlate their results with age. Our findings agree very well with those of the above workers as regards the number of myelinated fibers in the nerves studied.

Numerous investigators have reported alterations in various parts of the nervous system with age. Hodge (1894) described senile changes in the spinal ganglion cells of a 92-year-old man and also a decrease in the number of cells in the brains of old bees. Dunn ('12) observed a decrease in the size of both the axis cylinders and the myelin sheaths in rats over 640 days of age. Ellis ('20) found a gradual loss of Purkinje cells in the human cerebellum, beginning normally at the stage of 30 to 40, and amounting to a 24% decrease between the ages of 22 and 81. Inukai ('28) reported similar changes in the rat cerebellum and Maleci ('34) found a 14% decrease in the number of cells in the facial nucleus of man between the ages of 22 and 86. Arey, Tremaine and Monzingo ('36) found somewhat of a decline in the number of taste buds in man between maturity and the seventieth year but a striking decline thereafter.

Our observations indicate a definite decrease in the number of myelinated fibers in the spinal roots of man with age. This is in accord with the observations of Duncan ('30, '34),

who regarded the presence of fibers exhibiting wallerian degeneration in normal nerves as evidence of a gradual loss of nerve cells throughout life. On the basis of his observations of degenerating fibers in normal nerves, Duncan calculated a 13 to 41% reduction in the total number of nerve fibers during the lifetime of a rat. This agrees quite well with our finding of a 32% decrease from the third to ninth decade in man.

These facts are of particular significance in relation to the findings of Newman and Corbin ('36), who found an increased vibratory sensibility threshold in persons suffering from hypertrophic arthritis as compared with normal individuals of approximately the same age. Corbin ('36) reported a deforming joint alteration in deafferented cat limbs which was regarded as having resulted from malposition of the joint due to loss of the proprioceptive sensibility by deafferentation. This suggests that a loss of the myelinated fibers mediating muscle and tendon position sense may be a factor in the etiology of the so-called senile type of hypertrophic arthritis.

Our results appear to indicate a marked increase in the number of myelinated fibers during the first decade of life. This increase may occur principally through progressive myelination of existing unmyelinated fibers, or there may also be an actual increase in the absolute number of axis cylinders. Duncan ('34) believed that any increase in the total number of axis cylinders present in the spinal roots of the rat after the twentieth day of age, is due to an increase in growth of already existing, but unidentifiable, fibers. This accords with the observation of Allen ('12), who found no mitoses in the central nervous system of the rat after 30 days. Hatai ('02) found a steady increase in the number of myelinated dorsal root fibers from the 10 gm. to the 167 gm. white rat, but no change in the total number of ganglion cells during this period. Agduhr ('20) believed there is a steady increase in the total number of fibers in the spinal roots at all ages, but our results certainly do not support this conclusion.

The lines connecting the decade averages in the graphs of figures 3 to 6, naturally do not represent the actual condition. This applies particularly to that portion of the graph between

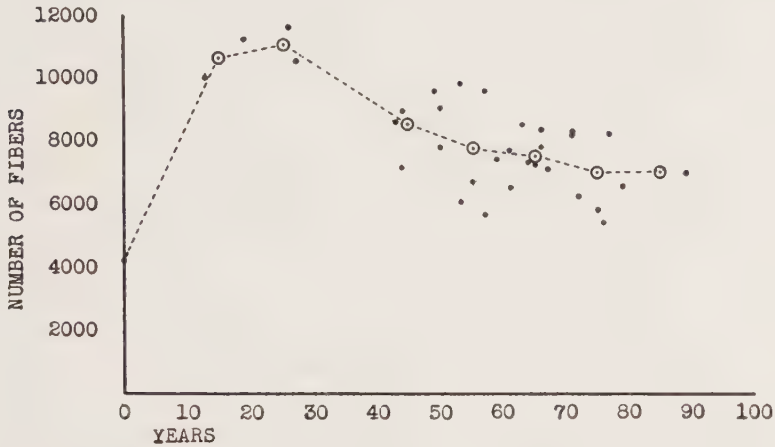

Fig. 3 Field graph of myelinated fibers in 8th thoracic dorsal root up to 85 years. •, indicates individual cases; ⊙, decade averages.

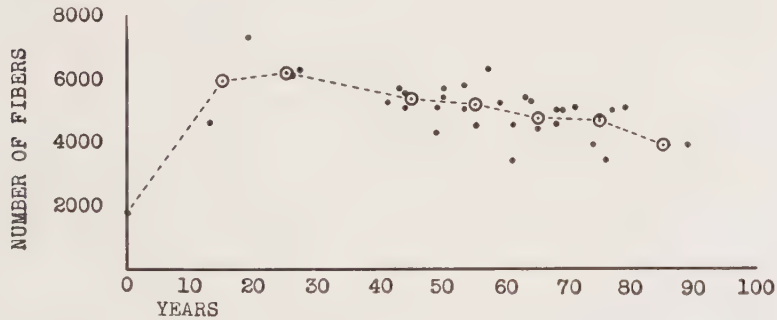

Fig. 4 Field graph of myelinated fibers in 8th thoracic ventral root up to 85 years.

the 1-day-old infant and the average for the second decade. It is not known when myelinization is complete in the human spinal roots, but it undoubtedly is earlier than is indicated in these graphs.

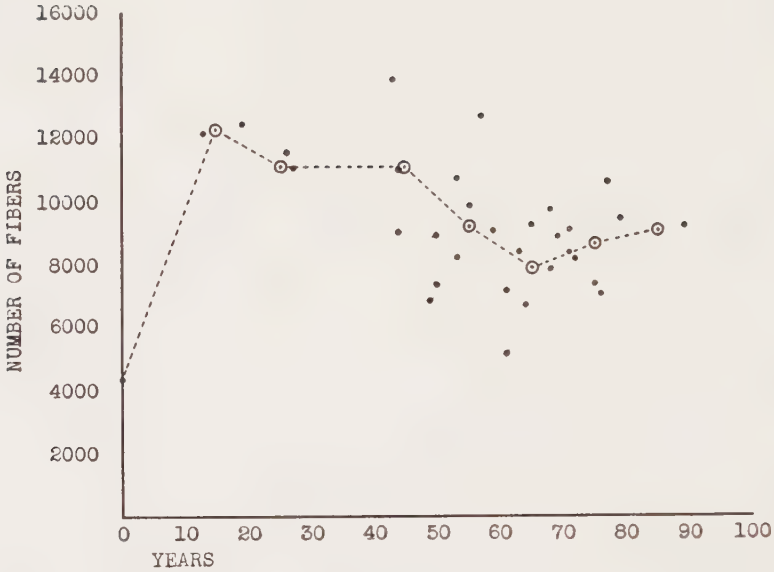

Fig. 5 Field graph of myelinated fibers in 9th thoracic dorsal root up to 85 years.

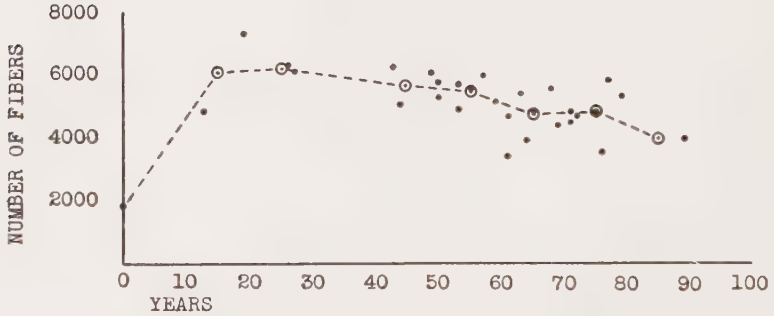

Fig. 6 Field graph of myelinated fibers in 9th thoracic ventral root up to 85 years.

A determination of the number of spinal ganglion cells at different ages would probably show a decrease comparable to our results. The presence of a decrease in the number of neurones in the central nervous system in old age seems to be an established fact. Degeneration of the peripheral processes from dying neurones situated in the spinal ganglia seems to offer a more logical explanation for a loss in vibratory sensibility, than posterior column lesions secondary to vascular changes, as suggested by Pearson. It is not likely that lesions of the nervous system due to vascular changes appear so constantly in the fourth decade of life as indicated by the decrease in vibratory acuity observed by us.

Our results would be of more value if unmyelinated fibers also could have been counted, but it seems likely that subsequent work will show a corresponding decrease in the number of unmyelinated as well as myelinated fibers. It is possible that an increased peripheral division of existing fibers during life, compensates for loss of ganglial neurones, although the presence of a decrease in vibratory sensibility would appear to negate this possibility.

SUMMARY

The number of myelinated fibers in the 8th and 9th thoracic dorsal and ventral roots were determined in thirty-four human cadavers, varying in age from 1 day to 84 years. The highest number, obtained for the second and third decades, was 187% larger than that obtained for a 1-day-old infant. A gradual loss of fibers after the third decade, amounting to 32% for the individual 89 years of age, was revealed. We believe this loss of myelinated fibers with age is the result of death of spinal ganglion cells, and well may account for the decrease in vibratory sensibility found after the third decade of life. A possible relationship between loss of peripheral nerve fibers with age and the senile form of hypertrophic arthritis is suggested.

LITERATURE CITED

AGDUHR, E. 1917 Der Einfluss des Trainieren auf das morphologische Bild des motorischen Nervensystems. Hygiea, Bd. 79, S. 801–828.

——— 1920 Studien über die postembryonale Entwicklung der Neuronen und die Verteilung der Neuriten in den Wurzeln der Spinalnerven. J. f. Psychol. u. Neurol., Bd. 25, S. 463–630.

ALLEN, E. 1912 The cessation of mitosis in the central nervous system of the albino rat. J. Comp. Neur., vol. 22, pp. 547–568.

AREY, L. B., M. J. TREMAINE AND F. L. MONZINGO 1935 The numerical and topographical relations of taste buds to human circumvallate papillae throughout the life span. Anat. Rec., vol. 64, pp. 9–25.

ARNELL, N. 1933 Zur Kenntnis der Anzahl der Nervenfasern in den Wurzeln der Spinalnerven des Menschen. Upsala Läkarefor. Förhandl., Bd. 39, S. 97–117.

CORBIN, K. B. 1937 Alterations in the hip joint following deafferentation. Arch. of Surg. (In press.)

DAVENPORT, H. A. AND R. T. BOTHE 1934 Cells and fibers in spinal nerves. II. A study of C2, C6, T4, T9, L3, S2 and S5 in man. J. Comp. Neur., vol. 59, pp. 167–174.

DUNCAN, D. 1930 The incidence of secondary (wallerian) degeneration in normal mammals compared to that in certain experimental and diseased conditions. J. Comp. Neur., vol. 51, pp. 197–228.

——— 1934 A determination of the number of nerve fibers in the eighth thoracic and the largest lumbar ventral roots of the albino rat. J. Comp. Neur., vol. 59, pp. 47–60.

DUNN, E. H. 1912 The influence of age, sex, weight and relationship upon the number of medullated nerve fibers and on the size of the largest fibers in the ventral root of the second cervical nerve of the albino rat. J. Comp. Neur., vol. 22, pp. 131–157.

ELLIS, R. S. 1920 Norms for some structural changes in the human cerebellum from birth to old age. J. Comp. Neur., vol. 32, pp. 1–33.

HATAI, S. 1902 Number and size of the spinal ganglion cells and dorsal root fibers in the white rat at different ages. J. Comp. Neur., vol. 12, pp. 107–124.

HODGE, C. F. 1894 Changes in ganglion cells from birth to senile death. Observations on man and honey-bee. J. Physiol., vol. 17, pp. 129–134.

INGBERT, C. 1903 An enumeration of the medullated nerve fibers in the dorsal roots of the spinal nerves of man. J. Comp. Neur., vol. 13, pp. 53–120.

INUKAI, T. 1928 On the loss of Purkinje cells, with advancing age, from the cerebellar cortex of the albino rat. J. Comp. Neur., vol. 45, pp. 1–31.

MALECI, O. 1934 Contributo alla conoscenza delle variazioni quantitative delle cellule nervose nella senescenza. Arch. ital. di anat. e. di embriol., vol. 33, pp. 883–901.

NEWMAN, H. AND K. B. CORBIN 1936 The quantitative determination of vibratory sensibility. Proc. Soc. Exp. Biol. and Med., vol. 35, pp. 273–276.

PEARSON, G. H. J. 1928 Effect of age on vibratory sensibility. Arch. Neur. and Psychiat., vol. 20, p. 482–496.

SHERRINGTON, C. S. 1894 On the anatomical constitution of nerves of skeletal muscles; with remarks on recurrent fibers in the ventral spinal nerve-root. J. Physiol., vol. 17, pp. 211–258.

THE UTRICULO-ENDOLYMPHATIC VALVE AND DUCT AND ITS RELATION TO THE ENDOLYMPHATIC AND SACCULAR DUCTS IN MAN AND GUINEA PIG

T. H. BAST

Department of Anatomy, University of Wisconsin

NINE TEXT FIGURES AND TWO PLATES (SEVEN FIGURES)

In recent years considerable interest has been manifested in the structure of the endolymphatic duct and its relation to the sacculus and utriculus. The studies of Guild ('27 a, b) on the guinea pig ear and Anson and Wilson ('36) on the human ear, which showed so clearly the histological structure of the different regions of the endolymphatic duct system, were undertaken with the hope that a thorough knowledge of structure might throw light on the question of function.

Guild's studies were concerned primarily with the structure of the sacculus, endolymphatic duct and endolymphatic sac in the guinea pig, with only a reference to the utriculo-endolymphatic (utriculo-saccular) duct. Anson and Wilson's work on the human ear dealt with all of these ducts and also the utriculo-endolymphatic valve ('utricular fold'). This paper will be chiefly concerned with the direction of the utriculo-endolymphatic duct, its angle of junction with the rest of the endolymphatic duct system, its opening into the utriculus and its relation to the utriculo-endolymphatic valve.

INTRODUCTION

The older literature on the duct system carrying endolymph is well reviewed by Guild ('27 a, b), therefore only the more recent papers will be referred to here. The question as to

THE ANATOMICAL RECORD, VOL. 68, NO. 1 AND SUPPLEMENT NO. 1

terminology and the relationship of the so-called utriculo-saccular duct to the sacculus and endolymphatic duct has not been definitely agreed upon as may be gathered from the articles by Alexander ('24), Wittmaack ('24 a, b), Guild ('27 a, b), Bast ('28, '33, '34), Wilson and Anson ('29), Hoffman and Bast ('30), Roberts ('32), Anson ('34), Anson and Wilson ('36), Perlman and Lindsay ('36) and Anson and Nesselrod ('36).

The questions at issue are:

1. Where is the vestibular end of the endolymphatic duct?

2. Does the utriculo-saccular duct open into the sacculus as its name indicates, or does it open at the junction of the sacculus and endolymphatic duct, or does it open directly into the endolymphatic duct?

3. What is the angle of opening of the utriculo-saccular (utricular duct) into the rest of the endolymphatic duct system?

According to conventional accounts the endolymphatic duct is a tubular extension from the sacculus which passes through the vestibular aqueduct and ends intradurally in the endolymphatic sac. The utriculo-saccular duct has been described as a duct which connects the utriculus and sacculus. If one looks at some of the conventional textbook figures (figs. 1 to 3) one sees at a glance that the various authors have different ideas as to the opening of the utriculo-saccular duct. Alexander ('24) diagrams it (fig. 5) as a short wide duct opening directly between the utriculus and sacculus. Gegenbauer (1892) accepts Retzius' idea (fig. 6) which shows it to open into what is usually regarded as the endolymphatic duct but at such an angle that the opening of the duct points toward the sacculus. Spalteholz ('14) (fig. 7) presents a condition similar to that of Retzius but the direction of the duct is such that its opening points toward the distal end of the endolymphatic duct. If Alexander's diagram were correct then the term utriculo-saccular duct would be a proper descriptive term. On the other hand, if the general idea of Gegenbauer's and Spalteholz's diagrams is correct, namely, that the so-called utriculo-saccular duct extends between the utriculus and

endolymphatic duct, then it should be called the utriculo-endolymphatic duct.

Gegenbauer (1892) states that the utriculo-saccular duct opens into the constricted end of the sacculus. Alexander ('24) emphatically states that the utriculo-saccular duct connects the utriculus and sacculus. Wittmaack ('24 b) in reviewing Alexander's text accepts the terminology but severely criticizes his diagram and suggests that Spalteholz's diagram is correct. Although he accepts the term utriculo-saccular duct he feels that it opens at the junction of the endolymphatic duct and the duct from the sacculus.

Guild ('27 a), whose conclusions are based on his careful studies of the histology of the endolymphatic duct and sacculus in the guinea pig, writes, "In other words, the ductus endolymphaticus arises from the sacculus, and not from the junction of the duct from the sacculus and utriculus, and the utriculo-saccular connection, while somewhat longer and narrower than in some forms, opens really into the sacculus near the orifice of the endolymphatic duct." He considers the duct from the sacculus not as a duct but as a constricted part of the sacculus. The widening of this channel at the point where the duct from the utriculus meets it he calls the 'sinus posterior sacculi.'

Bast ('28, '33, '34), Wilson and Anson ('29), Hoffman and Bast ('30) and Roberts ('32) use the terms utriculo-endolymphatic duct and sacculo-endolymphatic duct to designate the ducts from the utriculus and sacculus respectively which converge to meet the endolymphatic duct.

Anson and Wilson ('36), whose conclusions are based on the human ear, consider the endolymphatic duct as extending from the sacculus to the endolymphatic sac. The sinus-like enlargement of the duct system mentioned by Guild as sinus posterior sacculi they, Anson and Wilson, consider as sinus I of the endolymphatic duct. Let me quote Anson and Wilson ('36). "The utriculo-saccular (or utricular) duct leaves the anteromedial aspect of the utricle to join the sinus-like enlargement of the endolymphatic duct." They, however, accept

Boettcher's interpretation that the duct between the sacculus and the sinus I of the endolymphatic duct is a distinct structure and therefore call it the saccular duct.

In recent articles by Perlman and Lindsay ('36) and Anson and Nesselrod ('36) the terms utricular duct and saccular duct are used in their descriptions.

To clearly understand the interpretation of Anson and Wilson one should turn to the account of Anson ('34) on the early development of the membranous labyrinth. He writes, page 18,

> Thus the widely communicating utricle, saccule and endolymphatic duct of the 22.8-mm. embryo (fig. 1) are brought, at the 40-mm. stage (fig. 4) into the definitive and permanent relationship obtained in the adult ear—one in which the utricle does not communicate directly with the saccule, but with the latter through two intermediaries, the divergent utriculo-endolymphatic (or utricular) and the ultriculo-saccular (or saccular) duct; both of which appear as limbs of the endolymphatic duct and with it assume the form conventionally described as Y-shaped.

A glance at Anson's figures shown here in figures 1 to 4 show that in the early embryo the endolymphatic duct develops from the postero-medial wall of the utriculo-saccular duct. On the anterolateral surface of the utriculo-saccular duct a fold or crease develops which grows in the general direction of the outgrowing endolymphatic duct. In Anson's figure 4 this fold marked III has grown deep enough so that the utriculo-saccular duct has become a V-shaped duct with the endolymphatic duct emerging from the angle of this V, thus producing a system of ducts whose combined shape resembles more or less the shape of the letter Y. The stem of the Y represents developmentally the endolymphatic duct, and the two limbs, the bent utriculo-saccular duct. In the fully developed human ear, then, the utricular portion of the utriculo-saccular duct is not directed toward the sacculus and the saccular portion is not directed toward the utriculus but both ducts are directed toward the endolymphatic duct. Thus it seems, at least for descriptive purposes, that these three

ducts, all converging toward one point, should have separate names. Therefore the limb from the sacculus should be called sacculo-endolymphatic duct or for short 'saccular duct' (Anson and Wilson) and the limb from the utriculus as utriculo-endolymphatic duct or 'utricular duct.' The question

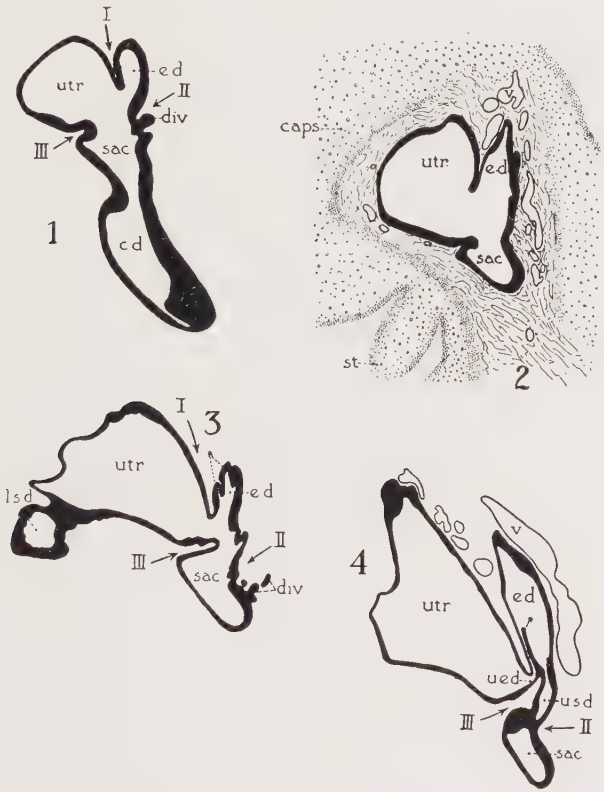

Figs. 1 to 4 Photographic reproduction of Anson's ('34) drawings to show especially folds I and III and the role they play in the formation of the utricular and saccular ducts and the utriculo-endolymphatic valve.

as to whether the utricular duct opens into the endolymphatic duct or saccular duct may still be open to debate, but from an embryological point of view it would seem that the converging saccular and utricular ducts give rise to the common endolymphatic duct.

The third controversial question is that of the angle of entrance of the utricular duct into the endolymphatic duct system. Alexander (fig. 5) pictures it as going directly into the sacculus. According to Gegenbauer (fig. 6) the opening of the duct is directed toward the sacculus, while in Spalteholz's diagram (fig. 7) it is directed away from the sacculus. In the study of mammalian ears the more recent investigators have agreed with Spalteholz as to the general arrangement of the duct system. In my earlier papers (Bast, '28, '33, '34, and Hoffman and Bast, '30) it was shown that the shape of the endolymphatic duct system in man, monkey, cow, sheep, pig and most laboratory animals was usually that of the letter Y, although in some cases the V portion was U-shaped. The duct from the utriculus was called the utriculo-endolymphatic duct and the one from the sacculus the sacculo-endolymphatic duct. In agreement with this finding are the observations of Wilson and Anson ('29) and Anson and Wilson ('29, '36) on the human ear; Roberts ('32) on the rat; Anson ('34) on mammalian embryos, and Perlman and Lindsay ('36) on human ears.

The purpose of this paper is to present statistical facts relative to the third question raised. What is the angle of opening of the utricular duct into the endolymphatic duct system, and what bearing may this have on the functional significance of the utriculo-endolymphatic valve? In this paper, for the convenience of description, the stem of the Y-shaped duct system will be called endolymphatic duct, the limb coming from the sacculus, the saccular duct, and the limb from the utriculus, the utricular duct.

Figures 5 to 7 Classical diagrams of the otic labyrinth.

Fig. 5 Alexander's ('23) diagram. The utriculo-saccular duct (cus) is shown here as a direct communication between the sacculus and utriculus.

Fig. 6 Gegenbauer's (1892) diagram (according to Retzius). The utriculo-saccular duct is shown to open into the endolymphatic duct but is directed toward the sacculus.

Fig. 7 Spalteholz's ('14) diagram of the otic labyrinth. The utriculo-saccular duct meets the endolymphatic duct and the duct from the sacculus so that the combined ducts occur in the form of the letter Y.

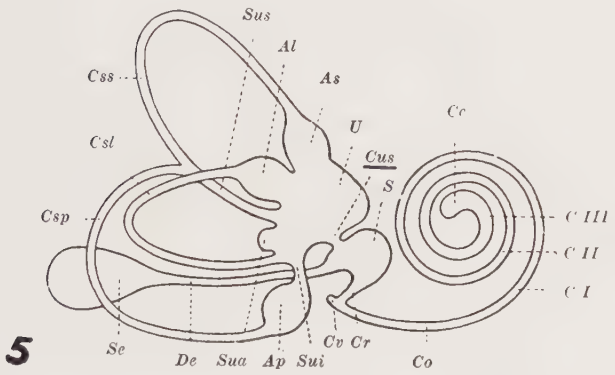
Sus
Al
As
Cc
Css
U
Csl
Cus
S
Csp
C III
C II
C I
Se
De
Sua
Ap
Sui
Cv
Cr
Co

5

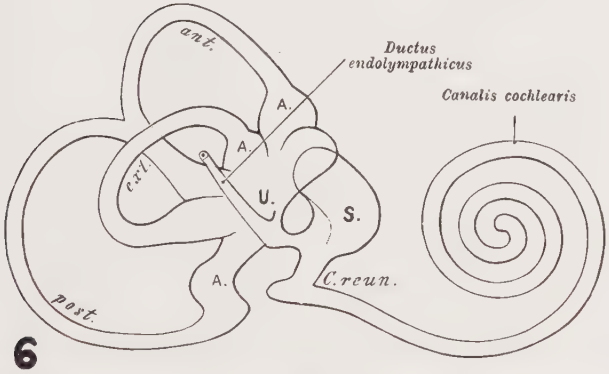
ant.
Ductus endolympathicus
Canalis cochlearis
A.
A.
ext.
U.
S.
A.
C. reun.
post.

6

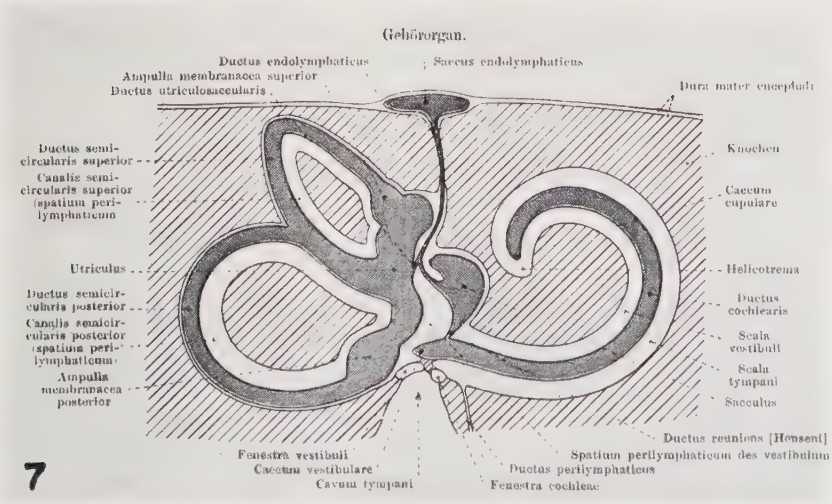
Gehörorgan.
Ductus endolymphaticus
Saccus endolymphaticus
Ampulla membranacea superior
Ductus utriculosaccularis
Dura mater encephali
Ductus semicircularis superior
Knochen
Canalis semicircularis superior (spatium perilymphaticum
Caecum cupulare
Utriculus
Helicotrema
Ductus semicircularis posterior
Ductus cochlearis
Canalis semicircularis posterior (spatium perilymphaticum)
Scala vestibuli
Scala tympani
Ampulla membranacea posterior
Sacculus
Ductus reunions [Hensen]
Fenestra vestibuli
Spatium perilymphaticum des vestibulum
Caecum vestibulare
Ductus perilymphaticus
Cavum tympani
Fenestra cochleae

7

MATERIALS AND METHODS

This study is based on my collection of serial sections through sixty-one human fetal ears, twenty-seven children ears and ninety-three guinea pig ears. Since a study of individual sections does not present the actual relationship of the various endolymph channels it was necessary to reconstruct many of them from the serial sections. In some of the ears which were sectioned at a suitable plane the relation of the utricular duct to the saccular duct and endolymphatic duct could be presented by a composite drawing made by superimposing sketches of the serial sections. This was a much less time consuming procedure than the reconstruction method and in most cases gave a clear idea of the relationship of the duct system. The method of superimposition of drawings of serial sections on cellophane sheets was also employed and gave a transparent three dimensional view.

OBSERVATIONS ON THE HUMAN EAR

In the human ear the relationship of the utricular duct to the utriculus and the rest of the endolymphatic duct system is not always the same. In describing these variations we have to consider the mode of entrance of the utricular duct into the utriculus and the angle of junction with the rest of the duct system. Figure 8 is a diagram drawn from a model of the ear of a 4-day-old child showing the relationship of the sacculus, utriculus, utricular duct, saccular duct and endolymphatic duct as it exists in the majority of human ears. Special attention should be drawn to the two angles (fig. 8, angles 1 and 2) formed by the utricular duct and the rest of the duct system. Angle 1 is the angle formed between the utricular duct and the endolymphatic duct. It is usually an obtuse angle as seen in figure 8. In other words, the opening of the utricular duct is directed toward the distal end of the endolymphatic duct. Angle 2 is an acute angle and is formed between the utricular duct and the saccular duct. This arrangement of the duct system is Y-shaped with the stem of the Y representing the endolymphatic duct and the two arms

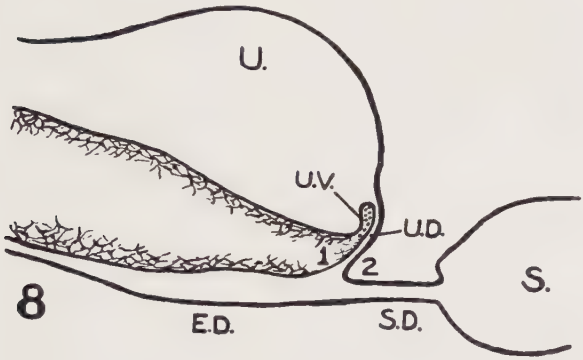

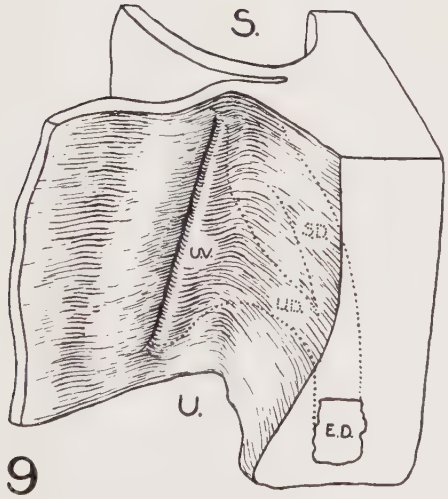

Fig. 8 Diagram of endolymphatic ducts in the region of the sacculus and utriculus of a human fetus. 1, the obtuse angle formed between the utricular duct and endolymphatic duct. 2, the acute angle formed between the utricular duct and the saccular duct. U, utriculus; S, sacculus; S.D., saccular duct; U.D., utricular duct; E.D., endolymphatic duct; U.V., utriculo-endolymphatic valve.

Fig. 9 Drawing from a model of the duct system of a 4-day-old child to show the slit-like opening of the utricular duct into the utriculus. S, sacculus; U, utriculus; U.V., utriculo-endolymphatic valve; E.D., endolymphatic duct; S.D., saccular duct; U.D., utricular duct.

the utricular and saccular ducts. A careful analysis of forty-seven fetal ears, five full term ears, and nineteen children ears showed that variations from this general pattern do occur. Three types of duct relationships have been noted.

Type I is the usual form as shown in figure 8 where the angle formed by the utricular and saccular ducts is an acute angle and the angle of utricular and endolymphatic ducts is an obtuse angle. This condition is the most common and occurs in 83.1% of the cases. (Table 1 and figs. 10, 11, 12 and 13.)

Type II includes those cases in which the utricular duct is very short and forms either a right angle or an acute angle with the endolymphatic duct and an obtuse angle with the saccular duct. This condition was found in 14.1% of the cases (table 1 and fig. 14). The sections of a number of these ears showed shrinkage and distortion which may have exaggerated this condition.

Type III includes those in which there is almost no utricular duct. In this type the tip of the utriculo-endolymphatic valve points toward a fold of tissue which separates the saccular duct from the saccular end of the utriculus. The slit between the tip of the valve and the fold of tissue is the only indication of the utricular duct. This short duct forms a right angle with both the saccular duct and endolymphatic duct. This condition was found in only two cases or 2.8% (table 1 and fig. 15).

Table 1 shows the relative occurrence of these types in fetuses and children. From this it is apparent that type I is the predominant type and is the one described by Wilson and Anson, Anson and Wilson, and Perlman and Lindsay for the adult human ear.

The condition found in types II and III may be explained on the basis of incomplete development of the folds I and III described by Anson ('34) (fig. 4). Fold I according to Anson gives rise to the utriculo-endolymphatic valve and fold III so bends the utriculo-saccular duct as to give rise to the saccular duct and the utricular duct. If fold III, or folds I and III

TABLE 1

The types of utricular ducts and the number of ears and age groups for each type

TYPES	HUMAN FETUSES				INFANTS			TOTALS	
	Catalog no.[1]	Crown-rump length	Approximate age in weeks	Sex	Catalog no.	Age	Sex	Number of ears	Per cent
		mm.							
Type I	3	100	14	Male	79	3 days	Female		
	22	100	15	Female	124	4 days	.....		
	53	112—	15+	Male	75	4 weeks	Female		
	54	115—	15+	Female	83	10 weeks	Male		
	56	120—	16	Female	106	5 months, 6 days	Female		
	11	126	16 3/7	Female	101	4 months, 26 days	Female		
	5	135	17	Male	98	6 months	Male		
	12	135	17	Male	121	6 months	Female		
	37	140	17 3/7	Male	120	7 months, 13 days	Male		
	30	146	18	Female	78	7½ months	Male		
	41	160	19 3/7	Male	97	10 months	Male		
	13	161	19 4/7	Male	93R	14 months	Male		
	33	163	19 6/7	Female	93L	14 months	Male		
	29B	180	21 5/7	Female	103	1 yr., 10 mo., 20 days	Male		
	45B	180	29—(?)	Male	88	2½ years	.....		
	21	183	21	Male	96L	3 years	Male		
	29A	190	21+	Female	82	3 years	Female		
	70	202	23	Female	118	5 years	.....		
	51	210	24	Male					
	62	215	24+	Female					
	46	222	25	Female					
	2	230	26	.....					
	64	230	26	Female					
	114	230	26—	Male					
	42	240	27—	Female					
	30	246	27½—	Female					
	45A	260	29	Male					
	69	265	29+	Female					
	4	275	30+	.....					
	109	280	31	Male					
	59	290	32	Female					
	110	290	32	Male					
	60	305	33+	Female					
	74	315	34+	Male					
	122	350	38	Male					
	16	365	40	Female					
	67	Term	..	Male					
	123	Term	..	Male					
	95	Term	..	Male					
	102	Term	..	Male					
	115	Term	..	Female				59	83.1
Type II	57	112	15+	Male	119	4 months, 8 days	Female		
	55	117	15+	Male					
	36	135	17	Male					
	38	147	18	Male					
	39	150	18	Male					
	40	155	19	Male					
	116A	280	31	Female					
	66	290	32	Male					
	68	310	34	Female				10	14.1
Type III	50	111	15—	Female					
	116B	280	31	Female				2	2.8

[1] The letters A and B after catalog numbers indicate twins.

are poorly developed then type II would result, but if they are well developed the result is type I.

Type III apparently is a case in which fold I is very poorly developed and does not reach beyond the end of fold III and thus fails to develop a true utricular duct. The length of the utricular duct and the length of the valve depend on the extent of the development of fold I. In long ducts and valves fold I is well developed while in short ducts and valves the fold I is poorly developed. In considering these cases one must also bear in mind that these ears come from fetuses and children which died prematurely and it is therefore possible that concomitant with the abnormal conditions which caused the premature death there may have existed abnormal pressures which caused a distortion of the duct system.

The utricular duct and its opening into the utriculus in the human ear. The utricular duct in its course from the endolymphatic duct to the utriculus arches around the antero-medial wall of the utriculus and opens obliquely through the anterior wall of the utriculus in a slit-like opening. This slit-like opening lies in a vertical plane and measures about 1200 μ in length (fig. 9). The slit is very narrow and in most histological sections the opposing epithelia seem to touch each other (figs. 12 and 13). In some ears a slit is present and the opposing epithelia are separated by a few micra. The opening into the utricle is therefore extremely slit-like. As the utricular duct leaves the slit-like opening its lumen may become oval or even round. It may vary in different ears from an oval lumen, measuring from 100 to 150 μ in depth and about 5 to 10 μ in width, to a round lumen of about 25 or 35 μ in diameter.

On leaving the utriculus the duct lies adjacent to the convex medial surface of the utricular wall. In its course it gradually diverges from the surface of the utriculus and opens into the endolymphatic duct.

The utriculo-endolymphatic valve. The utriculo-endolymphatic valve is formed by the reflection of the wall of the utricular duct and that portion of the antero-medial wall of

the utriculus which overlies the flattened funnel-shaped utricular portion of the utricular duct (figs. 9 and 13). The core of this valve consists of a cellular, modified form of periotic (perilymph) tissue. In figures 10, 11, 12, 13, which are photomicrographs of the valve, the epithelial fold and supporting core of cellular connective tissue is clearly shown. The approximate extent of the valve is indicated by arrow 1, figure 13. The extent of the valve is also indicated in figure 9 as that part of the wall of the utriculus which overlies the fan-shaped expansion of the utricular duct. The base of the valve is continuous with the tissue (fig. 13, P.T.) that lies between the utriculus and endolymphatic duct. This tissue is an isthmus of periotic (perilymphatic) tissue which is continuous with the periotic tissue and fluid of the rest of the vestibule. This does not agree with the impression received from the recent account of the valve given by Anson and Wilson ('36) which reads, "The fold is not only a double structure, but is supported posteriorly by bone and a tongue of periosteal tissue." This infers that the valve extends from the utricular opening of the utricular duct to the bony process shown in figure 13, B. This, however, is not the case. The only part that can be regarded as a fold or valve is the flap of tissue which overlies the expanded portion of the utricular duct. The tissue which lies between the utriculus and the endolymphatic duct (fig. 13, P.T.) and which in sections appears as a basal extension of the valve, is in reality an isthmus of loose periotic tissue continuous above, below and posteriorly with the rest of the vestibular tissue. The bony process and periosteal tongue (fig. 13) referred to by Anson and Wilson is the inner margin of the bony capsule surrounding the aquaeductus vestibule. It does not support the valve. The valve itself consists of an epithelial fold with a core of cellular connective. Toward the base of the valve (fig. 13, arrow 1) this cellular tissue is rapidly replaced by the loose periotic tissue of the isthmus which separates the endolymphatic duct and the utriculus. This difference in structure of the tip and base of the valve is significant from the standpoint of function.

OBSERVATIONS ON THE GUINEA PIG EAR

A study of serial sections through ninety-three guinea pig ears showed that the utricular duct opens into the saccular and endolymphatic ducts at either right angles to both or at an obtuse angle to the saccular duct and at an acute angle to the endolymphatic duct (fig. 16). In the majority of cases the opening of the duct was directed slightly toward the sacculus or at an obtuse angle to the saccular duct. This stands quite in contrast to the condition in the human ear and the ears of monkey, cow, cat, rabbit, gopher, squirrel and rat (Hoffman and Bast, '30) where the duct forms an obtuse angle with the endolymphatic and acute angle with the saccular duct. The length of the utricular duct is variable but as a rule is quite long. Its length as in man depends upon the extent of development of fold I.

The utricular duct and its opening into the utriculus in the guinea pig. In man the utricular duct arched around the anteromedial wall of the utriculus, but in the guinea pig it takes an almost straight course lying parallel to the anterior surface of the utriculus (fig. 16) and opens obliquely through the anterior wall of the utricle. The opening, as in man and other animals, is slit-like so that the union of the posterior wall of the utricular duct and overlying portion of the utricular wall form a valve-like flap like that in man and the other animals. The valve in most guinea pigs is quite long as may be seen in figure 16.

DISCUSSION

The function of the utriculo-endolymphatic valve. From a purely anatomical point of view it would seem that in most animals and in all human ears, except in cases where it is not developed as shown in types 3 and 4, the utriculo-endolymphatic valve is a structure which could aid in the closing of the utricular end of the utricular duct. As a matter of fact in many histological sections the epithelium of the valve is in contact with the opposing wall of the slit-like opening of the duct which suggests that such a closure may exist, at least at

times, in the living ear. Furthermore, the fact that the valve lies between the cavity of the utriculus and the concave surface of the arching utricular end of the utricular duct adds to the probability of this function. In the guinea pig where the utricular duct takes a straighter course the function seems more doubtful. However, even here the valve in histological sections is usually seen to lie in apposition to the opposing wall (fig. 16) indicating that is can aid in closing the utricular opening of the utricular duct. The long valve in the guinea pig may compensate for the straight course of the duct. That the valve in the guinea pig can thus function is indicated by the experiment of Bast and Eyster ('35 a, b). These findings do not prove that the valve is a functioning structure. They only indicate the possibility of function. At the present time the following evidence has been accumulated to indicate that the utriculo-endolymphatic valve does aid in closing at times the slit-like opening of the utricular duct into the utriculus.

1. The location and form is similar to other known valves.

2. In many sections the valve epithelium is in contact with the epithelium of the opposing duct wall.

3. Bast ('34) showed two cases of ruptured and collapsed sacculi in children ears, but where the utriculus was expanded and the valve closed.

4. Bast and Eyster ('35 b) showed that in a guinea pig where fluid was withdrawn from the cochlear duct causing collapse of the saccule and the cochlear duct, the utriculus remained distended and the valve in contact with the opposing utricular duct wall.

5. Perlman and Lindsay ('36) showed sections of several children ears where the staining reaction of the utricular fluid was markedly denser than that of the sacculus, utricular duct, saccular duct and endolymphatic duct. In all of these cases the utricular end of the utricular duct was closed by close apposition of the valve and the opposing wall of the duct. In some of my own sections this finding is verified.

If such closure of the mouth of the duct occurs during life, what then is the mechanism? Does the valve move against

the opposing wall or does the opposing wall move against the valve? This problem is being investigated at the present time.

Anson and Wilson ('36) are of the opinion that the valve, because it is a stouter structure than the outer wall of the duct, would not be moved by pressure change. They write,

> We therefore believe that, were the movement of endolymph strong enough to produce a marked change in the shape of the duct, it would be the outer wall and not the inner or 'valvular' wall whose contour would be appreciably altered —and changed so that its utricular orifice would assume a lenticular rather than circular form.

This interpretation certainly is plausible and may be correct in case of certain pressure changes, but supposing the pressure in the utriculus is greater than in the surrounding perilymph so that the utricular wall is under tension due to this relatively greater intra-utricular pressure, then in case of reduced pressure in the rest of the endolymph channels the pressure of the utricular fluid on the valve, according to the laws of physics, should force it against the opposing duct wall. In checking through a series of guinea pig ears, used by Doctor Eyster and myself, in which both the perilymph and endolymph chambers of the cochlea were opened thus reducing the pressure of the perilymph and also the endolymph of the cochlear portion, it was found that the utricular end of the utricular duct was closed by apposition of the valve and opposing duct wall. Although the tip of the valve is bulky because of its cellular core, its base is made up of a loose perilymphatic tissue which should permit movement. This is also the condition in the aortic valves where the corpora aurangia make the free end bulky. However, whichever interpretation may prove to be correct, if the duct is closed at times, the utriculo-endolymphatic valve will be concerned, either actively or passively, in such closure.

Terminology. In a recent paper, Anson and Wilson ('36) attempt to show that the term 'valve' is not an appropriate name for the fold of tissue which projects over the expanded and flattened utricular end of the utricular duct. They sug-

gest the term utricular fold. In support of this contention they write (p. 496),

> in BNA terminology the term plica or fold refers to a permanent crest or elevation of a lining membrane which encroaches but little upon the space from whose wall it projects, as for example, the aryepiglottic folds of the pharynx . . . . The term valvula or valve on the contrary is restricted in application to those projections into hollow organs which unquestionably possess the physiological function of temporarily closing the lumen of the tube itself or the orifice of a smaller communicating channel.

If this is the meaning of 'valve' in BNA terminology then the BNA terminology is inconsistent for it applies the term valve to structures which lack such 'unquestionable function.' Examples of this are such BNA terms as valvula spiralis or valvula venae cavae inferioris.

I therefore see no objection to the term utriculo-endolymphatic valve, for it conforms to BNA terminology and also to the definition given in the thirteenth edition of Steadman's Medical Dictionary. Furthermore, there are the increasing number of observations listed above which indicate that the valve aids in closing the utricular end of the utricular duct.

SUMMARY

1. The relationship of the utricular, saccular and endolymphatic ducts may occur as one of three types in human ears.

In type I the utricular duct meets the endolymphatic duct at an obtuse angle and the saccular duct at an acute angle. This type occurred in 83.1% of the cases studied.

In type II the utricular duct is very short and it forms either right angles with the saccular and endolymphatic ducts or else an acute angle with the endolymphatic duct and an obtuse angle with the saccular duct. This type occurred in 14.1% of the cases studied.

In type III there is no true utricular duct and the utriculus communicates with the endolymphatic duct by means of a small opening. This type occurred in 2.8% of the cases studied.

2. Type I is the predominant type. Type II and III are regarded as atypical and appear to be the result of incomplete development of the embryonic folds I and III.

3. In the guinea pig the utricular duct is long but meets the endolymphatic duct at an acute angle and the saccular duct at an obtuse angle. This relationship is quite different from that in man and in most other animals where the utricular duct and the endolymphatic duct form an obtuse angle.

4. From a purely anatomical point of view the utriculo-endolymphatic valve should be capable of aiding in closing off the utricular opening of the utricular duct in all cases studied except in the human types II and III. In the guinea pig in spite of the adverse duct direction the long valve makes it possible for it to come in contact with the opposing duct wall.

LITERATURE CITED

Alexander, G. 1923 Makroskopische anatomie der Nervösen Anteile des Gehörorgans. Handbuch der Neurologie des Ohres, herausg. von Alexander. Marburg und Brunner, Bd. 1, S. 1–100.

——— 1924 Zur Anatomie des Ductus endolymphaticus. Zeits. f. Hals-, Nasen- u. Ohrenheilk, Bd. 9, S. 77–79.

Anson, B. J. 1934 The early development of the membranous labyrinth in mammalian embryos, with special reference to the endolymphatic duct and utriculo-endolymphatic duct. Anat. Rec., vol. 29, pp. 15–25.

Anson, B. J. and J. G. Wilson 1929 The utricular fold in the adult human ear. Anat. Rec., vol. 43, pp. 251–255.

——— 1936 The form and structure of the endolymphatic and associated ducts in the child. Anat. Rec.. vol. 65, pp. 485–498.

Anson, B. J. and J. P. Nesselrod 1936 Endolymphatic and associated ducts in man. Arch. of Otolaryngology, vol. 24, pp. 127–140.

Bast, T. H. 1928 The utriculo-endolymphatic duct. Anat. Rec., vol. 40, pp. 61–65.

——— 1933 Anatomy of the Rhesus Monkey, pp. 347–359. Edited by Hartman and Straus. Williams and Wilkins, Baltimore.

——— 1934 Function of the utriculo-endolymphatic valve. Arch. of Otolaryngology, vol. 19, pp. 537–550.

Bast, T. H. and J. A. E. Eyster 1935 a Is there localization in the cochlea for low tones? Ann. Oto., Rhin. and Laryngology, vol. 44, pp. 792–803.

——— 1935 b The function of the apical turns of the cochlea and the symptoms of a lesion in this location. Discussion from the point of view of animal experimentation. Trans. Am. Oto. Society, vol. 68.

Boettcher, H. 1869 Ueber Entwickelung und Bau des Gehörlabyrinths nach Untersuchungen an Säugethieren. Verh. d. Kais. Leop. Carol. d. Akad. d. Naturforscher, Bd. 35, S. 1–203.

Gegenbauer, C. 1892 Lehrbuch der Anatomie des Menschen. Verlag von Wilhelm Engelmann. Leipzig.

Guild, S. R. 1927 a Observations upon the structure and normal contents of the ductus and saccus endolymphaticus in the guinea pig (Cavia cobaya). Am. J. Anat., vol. 39, pp. 1–56.

——— 1927 b The circulation of the endolymph. Am. J. Anat., vol. 39, pp. 57–81.

Hoffman, E. F. and T. H. Bast 1930 A comparative study of the 'utriculo-endolymphatic valve' in some common mammals. Anat. Rec., vol. 46, pp. 333–347.

Perlman, H. B. and J. R. Lindsay 1936 The utriculo-endolymphatic valve. Arch. of Otolaryngology, vol. 24, pp. 68–75.

Roberts, J. T. 1932 On the utriculo-endolymphatic valve in the albino rat. Anat. Rec., vol. 53, pp. 255–264.

Spalteholz, W. 1914 Handatlas der Anatomie des Menschen, 7th ed. Verlag von S. Hirzell. Leipzig.

Wilson, J. G. and B. J. Anson 1929 The 'utriculo-endolymphatic valve' (Bast) in a 2-year-old child. Anat. Rec., vol. 43, pp. 145–153.

Wittmaack, K. 1924 a A critical review of the first half of Bd. 1 of the Handbuch der Neurologie des Ohres, by Alexander, Marburg and Brunner. Zentralbl. f. Hals-, Nasen-, u. Ohrenheilk., Bd. 5, S. 24–26.

——— 1924 b Entgegungen zu Vorstehenden Bemerkungen Alexander's über meine Besprechung der makroskopischen Anatomie der Nervösen Anteile des Gehörorgans im Handbuch der Neurologie. Zeits. f. Hals-, Nasen-, u. Ohrenheilk., Bd. 9, S. 80–83.

PLATE 1

EXPLANATION OF FIGURES

Figures 10 to 13 Photomicrographs of human fetal and children ears showing the usual relationship of the utricular, saccular and endolymphatic ducts. They are examples of the type I referred to in this paper. This type occurs in 83.1% of the cases studied.

10 A 183-mm. or 21-week-old human fetus.
11 A 230-mm. or 26-week-old human fetus.
12 and 13 A 4-day-old child.

U, utriculus; S, sacculus; S.D., saccular duct; U.V., utriculo-endolymphatic valve; U.D., utricular duct; E.D., endolymphatic duct; P.T., isthmus of periotic tissue between utriculus and endolymphatic duct; B, bone. Arrow 1, base of utriculo-endolymphatic valve.

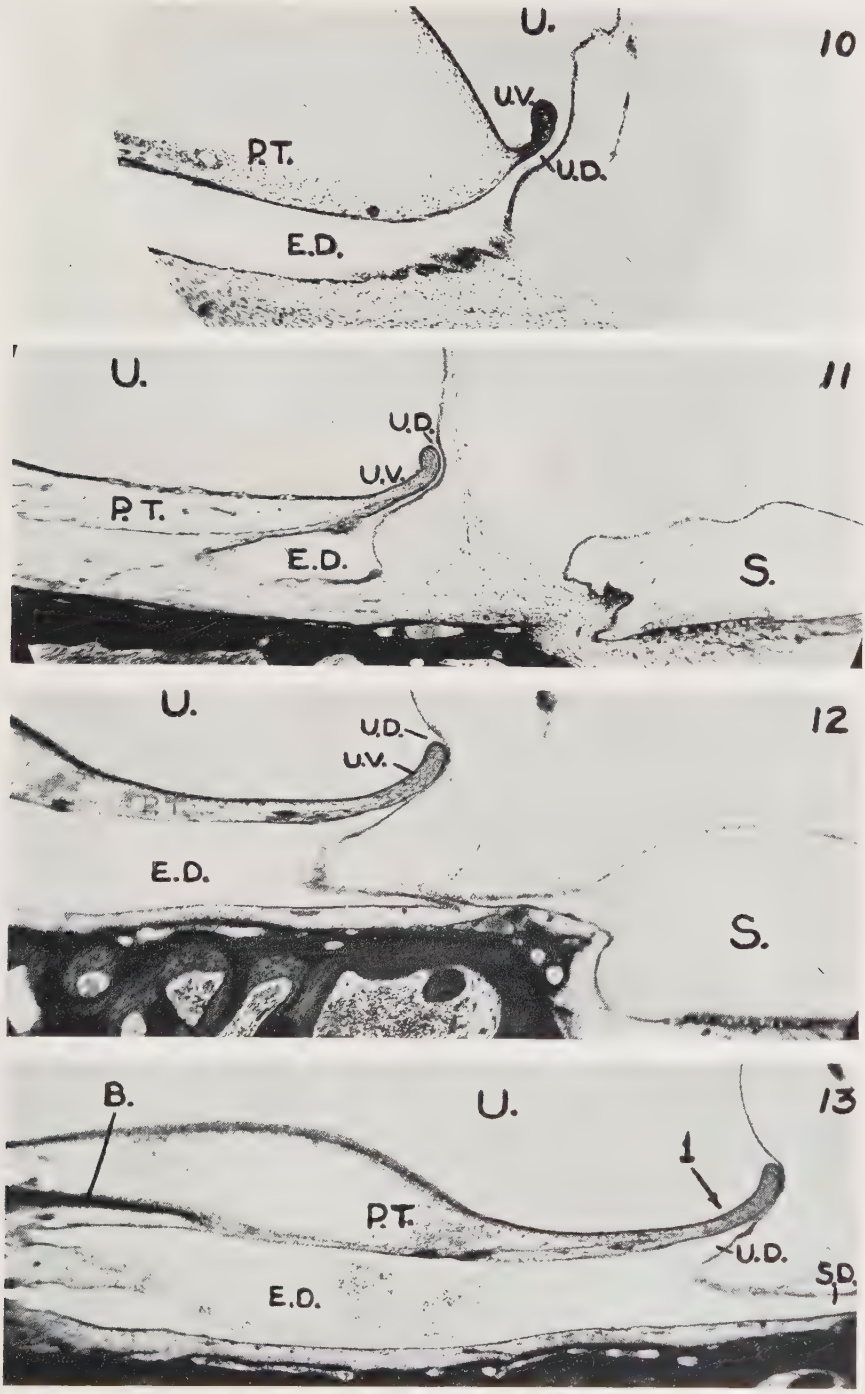
10
U.
U.V.
P.T.
U.D.
E.D.
11
U.
U.D.
U.V.
P.T.
E.D.
S.
12
U.
U.D.
U.V.
E.D.
S.
13
B.
U.
1
P.T.
U.D.
S.D.
E.D.

PLATE 2

EXPLANATION OF FIGURES

Figures 14 to 16 Photomicrographs of two human fetal ears and one guinea pig ear showing the relationship of the utricular duct to the endolymphatic and saccular ducts.

14 A 310-mm. or 34-week-old human fetus. The relationship of the duct system shown here is referred to in this paper as type II. It occurs in 14.1% of the cases studied.

15 A 280-mm. or 31-week-old human fetus. The relationship of the duct system shown here is referred to in this paper as type III. It occurs in 2.8% of the cases studied.

16 Guinea pig.

U, utriculus; S, sacculus; S.D., saccular duct; E.D., endolymphatic duct; U.D., utricular duct; U.V., utriculo-endolymphatic valve.


U.
14
S.D.
S.
E.D.

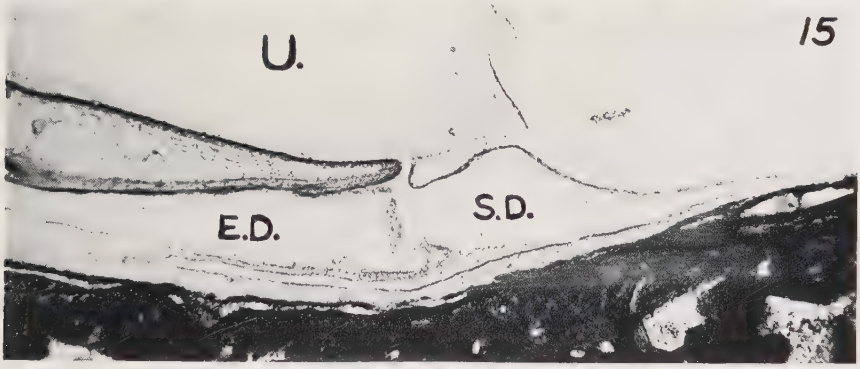
U.
15
E.D.
S.D.

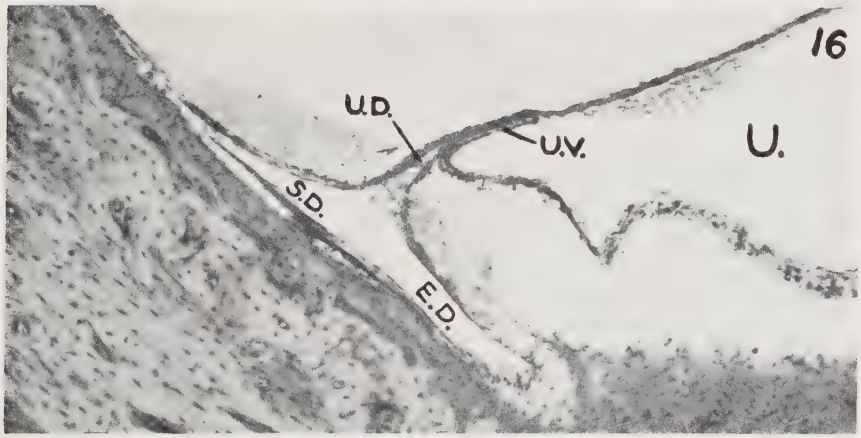
16
U.D.
U.V.
U.
S.D.
E.D.

ENDOMETRIAL AND MYOMETRIAL CHANGES, INCLUDING FIBROMYOMATOUS NODULES, INDUCED IN THE UTERUS OF THE GUINEA PIG BY THE PROLONGED ADMINISTRATION OF OESTROGENIC HORMONE [1]

WARREN O. NELSON

Department of Anatomy, Yale University School of Medicine

FOUR FIGURES

The possibility that an oestrogenic hormone is involved in the etiology of fibromyomas has been suspected for some time. In an analysis of the problem, Witherspoon ('33) has described the frequent association of cystic ovaries with uterine fibroids, and has strongly urged the possibility that the latter may be due to a stimulation of the uterine muscle and connective tissue by oestrogenic hormone.

In a series of thirty-two female guinea pigs that had been injected with oestrogenic hormone in oil for periods ranging from 2 to 10 months, six animals have shown one or more growths on the cornua or fundus of the uterus that appear to be definitely fibromyomatous in character. The preparations of oestrogenic hormone employed have been theelin, oestrone benzoate and benzo-gynoestryl. The first two are preparations of oestrone (theelin) and the third is a benzoated form of oestradiol (dihydrotheelin). Treatments have been given every other day for theelin and twice weekly for the other preparations. The amount per day of hormone (table 1) is given in both international units and in rat units. The dosage in international units is based upon the manufacturer's statement, while that in rat units is on the basis of assays in this

[1] This investigation was aided by grants from the Anna Fuller Fund and the Fluid Research Fund of Yale University.

laboratory. In our assays the rat unit is that minimum amount that will induce full cornification of the vaginal smear in at least seven of ten spayed rats.

TABLE 1

Guinea pigs injected with oestrogenic hormone that have developed fibromyomatous nodules

ANIMAL	AGE STARTED ON INJECTIONS	PERIOD	PREPARATION	INTERNATIONAL UNITS	RAT UNITS
		days			
49	Birth	265	Oestrone Benzonate	750	120
60	45 days	283	Theelin	500	70
100	Birth	104	Benzo-gynoestryl	700	300
101	Birth	125	Benzo-gynoestryl	700	300
80	Birth	218	Theelin	500	70
81	Birth	233	Theelin	500	70

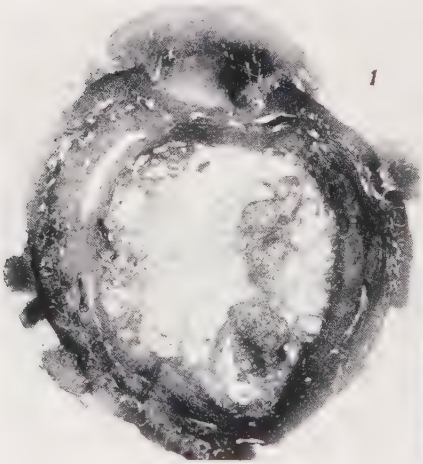



Fig. 1 Cross section of uterus of guinea pig 60 showing one large and several small fibromyomatous growths. The endometrium shows cystic glandular hyperplasia. × 7.

Fig. 2 Fibromyomatous growth on uterus of guinea pig. × 20.

Every animal in which fibromyomatous nodules have occurred showed several irregular periods of visible bleeding from the vagina. The tumors (figs. 1 and 2) are subperitoneal,

involving, or peripheral to, the outer longitudinal muscle layer, and range in size from small pedunculated growths a few millimeters in diameter to areas over a centimeter in length. Microscopically the tumors show a predominance of connective tissue elements, but fibers of the smooth muscle layer are present and interwoven with the connective tissue (fig. 3). Blood and lymph vessels are regularly dilated. This is particularly the case in the peripheral areas of the growths. In only one animal has there been any evidence of peritonitis.

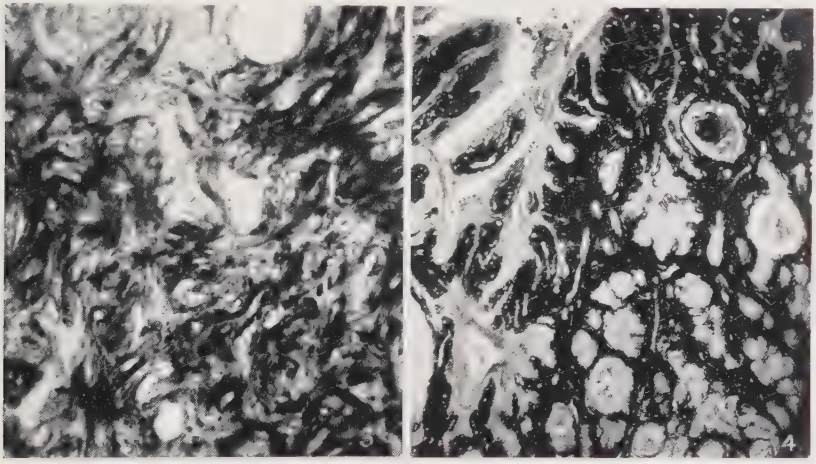

Fig. 3 High power photograph of a fibromatous nodule showing interwoven muscle and connective tissue fibers. × 215.

Fig. 4 Section through cervix of guinea pig 60. Note metaplastic downgrowths and pearl formation. Epithelium is light, connective tissue is dark. × 37.

The small growths, presumably representing early stages in the formation of the tumors are small reddish elevations which show widely dilated blood vessels and almost pure connective tissue proliferations.

Associated with these experimental fibroids, particularly the larger ones, there has been always a marked adenomatous hyperplasia of the endometrium with areas of hemorrhage into the lumina of glands and widespread metaplasia of the tips and crypts of the glands. In the cervical region extensive metaplastic downgrowths from the surface epithelium,

with keratinization and pearl formation are regularly present (fig. 4).

In animals treated less intensively, i.e., with oestrone or theelin for 2 to 6 months, cystic glandular hyperplasia of the endometrium of the cornua and adenomatous hyperplasia with metaplasia of the endometrium of the fundus are regularly present (Nelson, '36). When treatment is continued for longer periods the condition of adenomatous hyperplasia with metaplasia is superimposed upon the cystic glands of the cornua while these changes in the fundus also become progressively more marked.

It has been possible to correct the condition of cystic glandular hyperplasia by the administration of progestin, but in experiments so far conducted the metaplasia and adenomatous hyperplasia have not been significantly affected.[2]

SUMMARY

The administration of oestrogenic hormone preparations in the female guinea pig has led to the occurrence of cystic glandular hyperplasia in the uterine cornua and metaplastic downgrowths from the cervical epithelium. More prolonged treatment has resulted in the occurrence of an adenomatous hyperplasia of the endometrium, with bleeding, a marked increase in the glandular metaplastic changes, and the appearance of multiple subperitoneal fibromyomatous growths of varying size.

LITERATURE CITED

Hisaw, F. L. 1935 The physiology of menstruation in Macacus rhesus monkeys. Am. J. Obs. and Gyn., vol. 29, p. 638.

Nelson, W. O. 1936 Hyperplastic and metaplastic changes in the uterus of the guinea pig induced by prolonged administration of oestrone. Anat. Rec., vol. 64 (Suppl. no. 1), p. 70.

Witherspoon, J. T. 1933 A possible cause of uterine fibroids. Endocrinology, vol. 17, p. 703.

[2] In the rhesus monkey Hisaw ('35) has stated that injections of progestin would abolish the metaplastic changes which occur in the cervix following the prolonged administration of oestrin.

THE STRUCTURE OF THE SECRETING AND RETROGRESSING MAMMARY GLAND IN THE GUINEA PIG [1]

CORA HESSELBERG AND LEO LOEB

Department of Pathology, Washington University School of Medicine, St. Louis

In a former paper Kuramitsu and Loeb[2] compared the stages of secretion and involution of the mammary gland in rat and guinea pig in normal as well as in castrated animals. They also studied the effect of ligation of the nipple soon after labor in the guinea pig and found that this procedure caused a rapid retrogression of the mammary gland of the ligated gland, whereas secretion continued actively in the non-ligated mammary gland. The findings of Turner and Gomez[3] concerning the retrogression of the mammary gland in the guinea pig were similar to our own. In the rat, Jeffers[4] studied subsequently the cytological changes taking place in the mammary gland during lactation and involution. A difference of opinion developed, however, in regard to the effect of suckling in a non-ligated gland on the glands in which suckling had been prevented by means of ligation or excision of the nipples. In the rat it was observed by Selye[5] that suckling in one gland prevented or much delayed the retrogression of a non-suckled gland, while as stated in the guinea pig Kuramitsu and Loeb had previously noted a lack of effect of the suckled on the non-suckled gland. In order to make certain

[1] These investigations were carried out with the aid of a grant for research in science made to Washington University by the Rockefeller Foundation, and with the aid of a grant from the International Cancer Research Foundation.

[2] Kuramitsu, Choizu and Leo Loeb 1921 Am. J. Physiol., vol. 56, p. 40.

[3] Turner, C. W. and E. T. Gomez Research Bull. no. 194, Agricultural Exp. Station, Univ. of Missouri.

[4] Jeffers, K. R. 1935 Am. J. Anat., vol. 56, p. 257.

[5] Selye, Jans 1934 Am. J. Physiol., vol. 107, p. 535.

that our observations in the guinea pig had been correct, we carried out a new series of experiments in which we compared the condition of the mammary gland in suckling guinea pigs and in guinea pigs in which soon after labor the young had been removed from the mother and thus an early retrogression had been induced; and furthermore we compared the two mammary glands in guinea pigs in which the mammary gland of one side was ligated soon after labor while the gland of the other side was left intact. We wish here to report on some observations which we have made in the course of the microscopical study of these various tissues concerning the structure of the lactating and retrogressing mammary gland in the guinea pig.

THE SECRETING GLAND

In the guinea pig the young are born in a much more mature state than in the rat, mouse and rabbit, and the young guinea pig is able, therefore, to live and grow without suckling at a much earlier period of extrauterine life than the young of these other species. Under ordinary conditions, milk secretion and suckling in the guinea pig may last for from 3 to 4 weeks; after 3 weeks retrogressive changes usually begin to appear in the mammary glands. If the young should cease suckling earlier than this, either on account of the relatively mature state they have reached or due to too great a loss of weight of illness of the mother, retrogressive changes may set in in the mammary gland tissue even before that time. In this series we have studied the secreting mammary gland of the guinea pig only during the first 12 days following labor. If nursing proceeds normally, the glands during this period are large and full of milk. The acini are wide and the majority of them are full of secreted material, which collects in the lumen of the acini. The acinus cells are more or less flat and often show a frayed margin, a granular cytoplasm and vesicular nuclei. The more distended the acini are, the flatter the epithelial cells, as a result of the pressure exerted on them by the secreted material. Desquamated gland cells are observed here and there in the lumen of these acini, and in

other places acinus cells may undergo solution processes in situ. In such a gland the epithelial cells forming the lining of some of these acini may be lost, and thus granular material, representing remnants of the cells, may directly adjoin the stroma.

There may be found, however, in such glands a second type of acini in which the epithelial cells are higher and the lumen is smaller and here some cells may protrude into the lumen in a papilla-like fashion. In these cells amitotically divided nuclei are found not rarely and secretion vacuoles also occur. The lumens of such acini are either empty or they contain a finely granular material. This latter type of acini is often seen especially in the periphery of the gland. They probably represent an earlier stage of secretion than the usual type of acini in which the secreted material has accumulated in the lumen. There occur also occasionally intermediate stages between these two types of acini. If it should happen that suckling of the young ceases prematurely, changes set in in the mammary gland which are characteristic of the gland following labor, in which for some reason suckling has been interfered with.

THE EFFECT OF INTERFERENCE WITH SUCKLING OF THE MAMMARY GLAND OF THE GUINEA PIG FOLLOWING LABOR

The interference with suckling was accomplished through removal of the young from the mother in the first few hours after they were born. We studied this condition from 8 to 12 days following labor. In the non-suckling guinea pig, the mammary gland is composed mainly of small acini, in which no lumen or only a small lumen is visible. The acinus cells as a rule are flat cuboidal and contain flat nuclei; small vacuoles may occasionally be seen in such cells. In the lumen of these acini there may be some solid colloid or granular material. These acini are arranged in lobules, which after 12 days are mostly small. However, not all acini are of this kind. There occur also some larger acini, not unlike those seen in the secreting gland, in which the cells are higher, some

of them occasionally protruding into the lumen. These larger acini may be scattered among the other more usual kind of acini, or there may be in places collections of such larger ones. Vacuoles occur in the cells of this latter type of acini only ocasionally; also double nuclei due to amitotic division may be seen, and granular material may fill the lumen, or the granules may coalesce into a homogeneous colloid material; in other acini, one or several colloid cells are seen. This diffuse colloid material as well as colloid balls or discs represent inspissated secretion. The intraacinar pressure exerted by the secreted material may flatten out the acinus cells. In still other areas, especially in the peripheral parts of the gland, where the circulation is perhaps better, there may be found, interspersed with the areas consisting of the small acini, whole areas with the larger type of acini. The latter correspond to the second type of acini which, as stated above, occurs also in the normal nursing mammary gland.

Signs of degeneration may appear in some of the acinus cells; they may undergo vacuolization and desquamation; their nuclei may become pyknotic and karynorrhectic. As a result of these degenerative changes the epithelium may be lost in some places and the granular material come into direct contact with the connective tissue in the stroma. The connective tissue around ducts and also around acini may be increased in quantity; it is fibrillar and especially the interlobular stroma may be edematous at certain points. Loose connective tissue may penetrate also into the lobules between the acini and form here larger septa. More commonly at later periods it can be seen that the connective tissue has grown into certain areas between the acini; in addition some fat cells may penetrate into the lobules from the direction of the interlobular fat tissue.

Grossly it is seen that the size of the mammary gland is much diminished in the non-nursing guinea pigs. This is due in the first place to the diminution in the size of the large majority of the acini, but at the same time a greater destruction of the gland tissue has taken place accompanied by an

increase in the amount of the connective tissue separating the acini and lobules. This increase may in part be relative, the result of the shrinking of the acini, but there occurs also an actual increase in the amount of the stroma. Some remnants of stagnating milk may still be found in such retrogresssing glands, which readily become apparent on cutting into the gland tissue. In one specimen, 10 days after labor, an infection had taken place in the retrogressing gland with formation of abscesses and an increase in connective tissue in which collections of lymphocytes were visible; it is interesting that in this case an infection had occurred also in the uterus.

EFFECT OF LIGATING THE MAMMARY GLAND ON ONE SIDE WITHIN A FEW HOURS FOLLOWING LABOR

In these experiments the mammary gland of the non-tied side could be used for suckling. In some of the cases, in addition to ligating, the nipple was cut off in order to prevent attempts at suckling on this side. At different periods, namely from 3 to 20 days following labor, the mother was sacrificed and both mammary glands were removed for microscopic examination. Grossly there was in each instance a very marked difference in size between the mammary glands of the two sides, which was already evident as early as 3 days following labor. The nursing gland was much larger and the amount of milk present was much greater in the non-ligated than in the ligated gland. In the gland which could not be used for suckling, milk was either lacking altogether or it was present only in small amounts in a few places during the first eight days; subsequently no milk was noted. After 12 days and later the amount of gland tissue left on the ligated side was very small. During the first 13 days, the mammary glands of the side where the nipples had not been ligated had the typical structure of the secreting gland, the two kinds of acini characteristic of the nursing gland being visible and the content of the lumen in different acini showing certain variations. There were occasionally signs that to a limited degree

retention of the secreted material had taken place, and it seemed that in these series suckling began to diminish at a relatively early period following labor. The number of acini with higher cells and double nuclei varied in different specimens; likewise the degree of vacuolization varied, and in glands removed on the seventh, eighth and twelfth days after labor there were areas in which the vacuolization of the mammary gland tissue was so pronounced that the secreting tissue assumed almost the appearance of fat tissue. This condition probably indicated an incomplete evacuation of the milk. The secreted inspissated material in the lumen of the acini was granular while in others it was colloid, but in still other cases the lumen appeared empty. In the areas in which the retained secretion presented the form of colloid, polymorphonuclear leucocytes were observed in some instances attracted presumably by the stagnating secretion, and disintegrated there; in places these cells caused solution processes in the colloid material. In addition, desquamation and degeneration of some epithelial cells lining the acini led at certain points to a loss of the lining epithelium in some of the acini, and masses of granules here and there adjoined the stroma directly. This granular material was the remnant of degenerated gland cells. When such degenerative processes took place, fibroblasts, subsequently forming fibrillar connective tissue, began to penetrate between the small acini. During the latter periods of observation areas limited in size, consisting of acini with solid cells and containing small lumens, developed. These acini were similar to those characteristic of the ligated gland. They presumably indicated that the function of the gland at this time had become insufficient. In the specimens examined after 20 days, a great part of the mammary gland had become necrotic and abscess-like collections of polymorphonuclear leucocytes were seen in such areas, and also in some adjoining acini and ducts collections of polymorphonuclear leucocytes and lymphocytes were noted. The remaining acinar tissue consisted largely of small acini containing small lumens; in addition clotted blood was found

in the ducts and also in the acini of some areas. It is probable that infection had taken place as a result of the abnormal conditions prevailing in the mammary gland and, owing to tissue destruction, hemorrhages had occurred. Suckling and secretion had largely come to an end at this period. On the whole, a greater number of leucocytes were found only where degenerative processes had taken place in the gland tissue; but elsewhere isolated leucocytes and especially isolated lymphocytes were also seen. In some of the areas in which secretion had ceased the amount of connective tissue appeared to be increased.

On the ligated side, in the large majority of cases, the microscopic structure of the mammary gland was identical with that seen in the control experiments in which suckling had been prevented. The glandular tissue presented a solid character; the acini were small and contained a lumen correspondingly small or missing altogether; they were lined with flat or low cuboidal cells in which occasionally vacuoles were still noted. In the lumen of some acini, balls or sausage-like structures of solid colloid could be found, while in other acini or also in some ducts granular material staining with haematoxylin was seen. These changes were noticeable as early as 3 days after labor, as well as at later periods. Gradually the lobules shrunk more and more; but in addition signs of degeneration, such as desquamation of acinus cells, appeared in areas where acini were being destroyed; at last only small branching ducts were observed. At 20 days the disintegration of the acini was quite distinct, and the majority of the lobules had now disappeared, while some of the remaining acinus cells had undergone granular degeneration. Lymphocytes also helped to destroy some acini. In a specimen examined 10 days following labor, considerable accumulations of polymorphonuclear leucocytes and lymphocytes were seen in some of the large ducts which were dilated; furthermore leucocytes had penetrated also into the acini and had actively destroyed the colloid material in the lumen of the ducts and acini.

While the picture of areas consisting of small acini, which we have described, was the typical condition observed on the ligated side, there occurred among them quite commonly a small minority of larger acini similar to those seen in secreting normal glands. Either a whole lobule or a part of a lobule consisted of such larger acini or in other instances some larger acini were found scattered among the typical small acini. Even as late as 20 days following labor, a few large acini could be seen. They were lined with flat cells, if the material which filled the lumen of the acini pressed on the lining acinar cells, or with cells which were cuboidal or even higher and sometimes protruded into the lumen of the acini. In such cells double nuclei and vacuoles appeared as a sign that some secretion still persisted in a rudimentary form. In the lumen of some of these larger acini either colloid or granular material, taking on a purple color with hematoxylin and eosin, was found. In other acini the colloid was vacuolated and corresponding vacuolizations were seen occasionally in the acinus cells; in some cases a part of the cytoplasm or even the whole cytoplasm of an acinus cell became converted into granular material taking on the purplish stain. This granular transformation of the cell substance is probably the source of the granular material which was seen in the lumen of the acini or in the ducts in many cases. In these areas containing larger acini the size of the vacuoles in the acinus cells differed much in different parts and in some places the vacuolization was so pronounced that the mammary gland tissue assumed almost the appearance of fat tissue. We see then that even in the ligated mammary gland some rudimentary form of secretion persisted in a minority of the acini; however, in by far the greater part of the mammary gland the typical state indicating inactivity and retrogression of the gland was found.

As to conditions prevailing in the stroma, as early as 3 days after labor phagocytic mononuclear cells were seen penetrating into the colloid material in the lumen of the acini and helping to destroy it. Also lymphocytes were found in

variable numbers in the stroma, and occasionally these cells also penetrated into the acini and assisted in their destruction. In some specimens polymorphonuclear leucocytes were prominent, especially in the lumen of the large ducts, but sometimes also around ducts and in the acini. Their frequency varied greatly in different specimens. Around the larger ducts and lobules the connective tissue was usually densely fibrous. In some specimens fibroblasts were observed penetrating between the acini and subsequently giving rise to the formation of fibrillar connective tissue, while in other places this dense fibrillar connective tissue compressed the smaller acini.

SUMMARY

1. In the lactating gland of the guinea pig two kinds of acini can be distinguished which probably represent different stages of secretion.

2. In the secreting mammary gland there may develop some areas in which the acini closely resemble those found in the retrogressing gland. Conversely, in the retrogressing gland there may still persist for some time, areas in which the acini have the characteristics of a secreting gland. We may therefore conclude that in different parts of the same mammary gland conditions may favor either secretion or retrogression and that such variations may occur in the lactating as well as in the retrogressing gland.

3. One of the characteristic kinds of degeneration which acinus cells of the mammary gland may undergo following the stage of secretion is a conversion of the cytoplasm into a mass of granules which assume a purplish stain with haematoxylin and eosin. This change may be associated with a complete degeneration of the acinus cells; the granular material may then adjoin directly the connective tissue. These granular masses may secondly coalesce into a homogeneous colloid material filling the lumen of acini or ducts. Large ducts may contain a great number of colloidal balls or discs which had such an origin.

4. During the stage of retrogression there develop not only substances which attract lymphocytes and polymorphonuclear leucocytes, but processes of degeneration in the acini may stimulate also connective tissue cells which then invade actively the acinar tissue which thus becomes replaced by fibrous tissue. Also lymphocytes may invade and help to destroy some acini. There may, therefore, take place not only a relative, but also an absolute increase in connective tissue during the process of retrogression of the mammary gland in the guinea pig.

HISTOLOGICAL STUDY OF RENAL ELIMINATION OF ASCORBIC ACID *

A. GIROUD AND C. P. LEBLOND

Medical School of Paris and Yale University School of Medicine

SIX FIGURES

Although van der Walle ('22) was unable to detect ascorbic acid (vitamin C) in urine, modern researches have definitely demonstrated its presence there. Titration have been performed in the urine of man by van Eekelen, Emmerie, Josephy and Wolff ('33), Harris Ray and Ward ('33) and von Euler and Burström ('35). After their publications, extensive researches on this subject have been undertaken in many laboratories.[1]

The results of these authors have been somewhat contradictory, chiefly in regard to the variations of the ascorbic acid content of blood and urine after oral absorption or injection of ascorbic acid. Probably considerable individual variations (Hawley, Stephens and Anderson, '36) complicate the observations in humans.

With the use of guinea pigs as experimental animals, clear-cut responses were readily obtained. The ingestion and chiefly the injections of ascorbic acid were followed by a rise in the urine content of this substance. After its withdrawal from the diet, the level of elimination in urine was quickly lowered.[2]

* A demonstration of the results described in this paper was given before the American Association of Zoölogists, December, 1935 (Giroud and Leblond, '35).

[1] Hess and Benjamin ('34), Johnson and Zilva ('34), Drigalski ('35), Schroeder ('35), Hawley, Stephens and Anderson ('36), Casazza ('36), Armentano ('36), Jezler and Niederberger ('36), Baena Baena and Garcia Porrero ('36), Ahmad ('36), Archer and Graham ('36), Bowman and Muntwyler ('36), Gabbe ('36), Klodt ('36), Widenbauer ('36).

[2] De Caro ('34), Leblond ('34), Rohmer, Bezssonoff and Stoerr ('34), Rohmer, Bezssonoff, Stoerr and Perier ('35), Giroud, Chuc, Ratsimamanga and Leblond ('35), Mouriquand and Coeur ('35), Mouriquand, Weil and Simon ('34).

In the kidney itself, chemical titrations showed results varying according to the amount of ascorbic acid in the diet (Bessey and King, '33; de Caro, '34; Martini and Pinotti, '35), but little was known of the mechanism of excretion.

Meanwhile, silver nitrate, known as a test for ascorbic acid since Zilva ('25), Szent-Györgyi ('28), was applied to the histological detection of ascorbic acid. The acidification of the reagent rendered it more specific and its introduction by injection into the aorta soon after death made possible a precise localization (Giroud and Leblond, '34). The use of this method in correlation with chemical titrations permitted the observation of some details in the excretion of ascorbic acid.

TECHNIQUE

Both the chemical and histological methods have been applied: 1) to normal animals, 2) to guinea pigs given a vitamin-free diet, 3) to guinea pigs receiving injections of ascorbic acid. Notice should be taken of the fact that, in the three series (tables 1, 2, 3), different normal control animals were kept in conditions similar to those of the experimental animals.

Guinea pigs of about 300 gm. were used. In order to deplete them of their supply of ascorbic acid, the vitamin-free diet of Randoin and Lomba ('23) was used. Guinea pigs received injections of ascorbic acid into the jugular vein. Fifty milligrams were usually injected at one time. Such injections had no harmful effects upon the animals. Urine was obtained from the female guinea pigs by catheterization at 5- or 15-minute intervals beginning immediately after the injection.

Chemical titrations of the organs and urine were performed by Bessey and King's modification of the dichlorophenolindophenol method ('33); the modification of Emmerie and Eekelen ('34) was used in part of the experiments, apparently with more precise results.

Histological technique consisted of injecting an acid solution of silver nitrate into the aorta of the animal immediately

after the animal is killed by bleeding. The details of the method are given by Giroud and Leblond ('34). The value of the acid silver nitrate reaction as a test for ascorbic acid has been questioned. Harris and Ray ('33), noticing that the liver and the suprarenal medulla though rich in ascorbic acid failed to be stained by silver nitrate, concluded that the absence of this reaction was a poor guide as to the presence or absence of vitamin C. Like most of the investigators, King, in a recent review ('36), says: "Silver nitrate staining is not reliable qualitatively or quantitatively as an index of vitamin C in tissues."

However, this paper will bring out evidence that the reaction is very valuable as long as its limitations are borne in mind. Its specificity is shown by the occurrence of marked reactions in the organs which by chemical and biological methods appear to be rich in ascorbic acid (suprarenal cortex, corpus luteum, interstitial cells of the testis and anterior pituitary); but it is mainly the rapid disappearance of all the reactions, when guinea pigs are given a vitamin-free diet, and their recurrence soon after injection of ascorbic acid, that show the specificity of acid silver nitrate.[3] The absence of reaction is observed in some tissues containing ascorbic acid. This is caused for the most part by inhibiting factors that prevent the oxidation of the ascorbic acid, so that it does not reduce silver nitrate. In short, the absence of a coloration by acid silver nitrate does not necessarily mean the absence of ascorbic acid, but a positive reaction is a specific test for this substance.

RESULTS

Normal animals

Chemical estimations established the presence of ascorbic acid in the kidney of the rat (0.19 mg. per gram of fresh

[3] However, there is one exception: the melanin granules in the epidermis show a reaction which may not be attributed to ascorbic acid since it persists after methyl alcohol extraction and does not disappear in the scorbutic guinea pig. This single exception ought not to cause confusion because of the easily recognizable pigment granule.

material),[4] guinea pig, sheep, pig, cow and horse. Separate titrations of the cortical and medullary parts of the kidney (table 1) show slightly larger amounts in the cortex, with the exception of the kidney of the horse.[5]

Histological examination of the kidneys of rats and cats confirms the presence of ascorbic acid. The black precipitated silver is localized in the proximal convoluted tubules. No reaction is observed in the glomeruli or other tubules. As in other organs, a slight but definite reaction is seen along the walls of the blood vessels. Very often the red blood corpuscles in the capillaries are stained. The reaction is fairly comparable, though not marked, to that described below

TABLE 1

Amount of ascorbic acid in the kidney
(in milligrams of ascorbic acid per gram of fresh material)

	Cortex	*Medulla*
Cow	0.09	0.08
Horse	0.08	0.09
Sheep	0.13	0.09
Ox	0.14	0.08
Guinea pig	0.15	0.14

in the guinea pig (fig. 1). No apparent diminution of the reaction is observed in rats given a scorbutic diet; this might be expected since they synthesize ascorbic acid.

In the guinea pig, receiving the normal mixed diet (cabbage and cereals) the reactions are not marked. Only a few convoluted tubules and capillaries show black granules.

Scorbutic animals

The guinea pig synthesizes little or no vitamin C. When given a vitamin-free diet, the amount of ascorbic acid diminishes quickly in the organs. The average figures for titrations of the kidneys of guinea pigs killed at different intervals after the beginning of the diet are given in table 2.

[4] This result is the average figure for ten titrations.

[5] Loeper and others ('36) have made titrations of ascorbic acid in the urine of the dog.

Histologically, all the reactions disappear in the convoluted tubules and blood vessels, which fact confirms ascorbic acid as the cause of these reactions.

Effect of injections

A single injection of 50 mg. of ascorbic acid into the jugular vein of the guinea pig is followed by an increase in the content of ascorbic acid in the organs. There is a large accumulation in the kidney as compared with other organs. From table 3 it may be calculated that the amount in the kidney is increased more than ten times, while it is increased only 3.40 times in the liver and 2.10 in the adrenal.

TABLE 2

Decrease of the amount of ascorbic acid in the kidneys of guinea pigs given a vitamin-free diet (in milligrams of ascorbic acid per gram of fresh material)

	Kidney	*Adrenal (for comparison)*
Normal	0.10	0.90
After 4 days	0.03	0.23
After 7 days	0.02	0.13
After 10 days	0.03	0.05
After 12 days	0.02	0.035
After 20 days (scorbutic)	0.01	0.05
After 22 days (scorbutic)	0.01[1]	0.05[1]

[1] The slight amounts found in the adrenals and kidneys of scorbutic animals may be explained either by the presence of amounts of ascorbic acid too slight to protect the animal against scurvy or by the lack of specificity of the chemical reagent, or by both.

The figures obtained for urine (table 3) show a considerable elimination of ascorbic acid, corresponding to its accumulation in the kidney.

The reactions given by silver nitrate confirm these observations. As previously stated, for the histological detection of ascorbic acid, silver nitrate is injected into the aorta of the animal soon after death. When the abdomen of such animals is open, the organs appear more or less gray. If their supply of ascorbic acid is normal, the adrenals, rich in ascorbic acid, appear black, the muscles which contain very little of it look white and the kidneys are only slightly gray. If, however, the

guinea pig has received 50 mg. of ascorbic acid, the kidneys will appear very gray or black.

Macroscopic examination of a fresh cross section of the organ shows the blackening restricted to the cortex. This localization is not due to a lack of penetration of the silver nitrate introduced by vascular injection, because if after the

TABLE 3

Increase of the amount of ascorbic acid in the kidney and urine after intravenous injections of 50 mg. of ascorbic acid (in milligrams of ascorbic acid per gram of fresh material)

Time after injection	*Kidney*	*Urine*	*Adrenal (for comparison)*
Normal	0.07 to 0.10	0.27	0.70 to 1.09
2 minutes	0.90	....	1.12
5 minutes	0.83	21.27	1.11
10 minutes	1.03	37.36	1.37
15 minutes	0.86	31.62	1.09
20 minutes	0.88	47.36	1.22
30 minutes	0.98	33.27	1.55
1 hour	0.49	23.41	1.48
1½ hours	0.37	14.17	1.73
2 hours	0.32	4.33	1.88
3 hours	0.27	0.90	1.48
4 hours	0.20	0.35	1.31
5 hours	0.21	0.30	0.98

The values for the urine are the average values in six animals. For the organs they are average values of one to four animals for every number.

treatment with ascorbic acid the kidney is removed, sectioned and put in a solution of silver nitrate, the same blackening of the cortex is observed.

Histological examination confirms the presence of marked reactions in some tubules of the cortex (fig. 1) and no silver

Fig. 1 Cortical part of the kidney of a guinea pig injected with 50 mg. of ascorbic acid. The silver nitrate reaction shows a precipitate in the cells of some tubes. × 300.

Fig. 2 Medullary part of the kidney of a guinea pig injected with 50 mg. of ascorbic acid. The silver nitrate does not produce any reaction in the tubes. A group of capillaries, containing red blood corpuscles show the reaction. × 300.

Fig. 3 Cortex of the kidney of the guinea pig after injection of 50 mg. of ascorbic acid. Silver nitrate. No reaction is observed in the glomeruli, except in the red blood corpuscles in the capillaries. The proximal convoluted tubules show a precipitate. Some distal convoluted tubules, recognizable by their smaller size and lower epithelium, have not reacted. × 300.


1

2


3

reduction in the medulla, with the exception of the blood vessels (fig. 2). In these, the precipitate occurs along the walls. Some red blood corpuscles are stained. These reactions of both the blood vessel walls and the red corpuscles are observed only in the small blood vessels.

Such contrast between the cortex and the medulla is not confirmed by chemical titrations in the normal guinea pig (table 1). Separate titrations of cortex and medulla were also conducted in guinea pigs at 15 minutes and 5 hours after the treatment by 50 mg. of ascorbic acid. In the first case the cortical part of the kidney contained 1.38 mg. per gram of tissue and the medulla 1.30 mg.; in the second case, 0.23 mg. were found in the cortex and 0.27 mg. in the medulla. Apparently there are only slight differences between the two parts of the organ. Since within 15 minutes after the intravenous injection, the urine in the bladder contains as much as 31.62 mg. per cubic centimeter (table 3), one may assume that the urine in the collecting tubules of the medulla contains a large amount of ascorbic acid, which fact accounts for the high values in the medulla. On the other hand, the urine in the medullary tubules does not produce a reduction of silver nitrate in the lumen of these tubules. This is probably explained by the diffusibility of the ascorbic acid, which, in urine, is not connected with colloid particles as it possibly is in the protoplasm of cells.[6] Furthemore, in urine the existence of substances inhibiting the reduction of the reagent is probable.

Following the uriniferous tubules from the beginning, the glomeruli do not show any reaction, either because no ascorbic acid filters through them or, if ascorbic acid is present in the glomerular fluid, because its diffusibility prevents it from being detected in situ.[6] Only a few stained red blood corpuscles may be observed in the capillaries of the glomeruli (fig. 3). In contrast, the first cells of the proximal convoluted tubule leaving the glomerulus already contain black granulations (fig. 4).

[6] Lison ('36) claims that very soluble substances (such as ascorbic acid) cannot be detected histochemically, unless connected with elements of the cells.

Indeed the proximal convoluted tubules give a pronounced reaction. Their cytoplasm is filled with black granules that are crowded, mostly in the basal part of the cell. No reaction is observed in the nucleus (fig. 6). The granules have a tendency to be organized along parallel lines oriented perpendicularly to the tubule wall; this arrangement corresponds



Fig. 4 Glomerulus and proximal convoluted tubules. Silver nitrate reaction in a guinea pig treated with 50 mg. of ascorbic acid. No reaction is observed in the glomerulus. The first cells of the convoluted tubule leaving the glomerulus show the reaction of ascorbic acid. Camera lucida drawing.

approximately to the mitochondrial rods, as they appear when disintegrated into granules by a poor fixation, such as afforded by silver nitrate.

One knows that the descending branches of Henle's loop with their brush-border epithelium, may be considered somewhat similar to the proximal convoluted tubules and sharing

in their functions. The cells of these tubules contain also the silver precipitate characteristic of ascorbic acid.

On the contrary, the ascending branches of Henle's loop and the distal convoluted tubules, which are histologically and physiologically similar do not show any reaction (figs. 5 and 6).

As for the excretory tubules (and the collecting ducts of Bellini), which are only given the role of carrying the urine to the sinus, no reaction is observed in them.

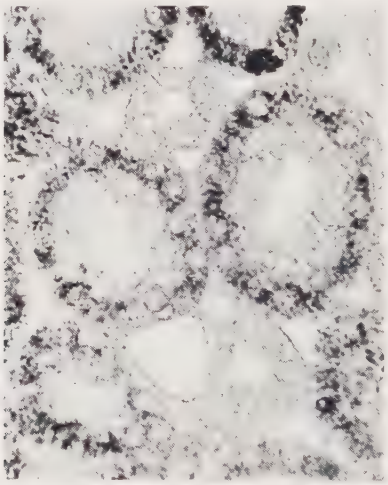

Fig. 5 Proximal and distal convoluted tubules. Silver nitrate reaction in a guinea pig treated with 50 mg. of ascorbic acid. The two kinds of tubules are easily recognizable by their size and the presence or absence of reactions.

These observations localize the accumulation of ascorbic acid during its excretion in the cells of the tubules with a brush-border epithelium. The concentration of the ascorbic acid in their cells might be explained either by its direct passage from the blood vessels into the cells, from which it will be secreted into the lumen, or by its resorption from the fluid that filtered through the glomerulus. The appearance of the reaction in the convoluted tubules as early as 1 minute after intravenous injection of ascorbic acid seems to indicate

a direct secretion of the tubules with accumulation in the cells. However, the modern results of kidney physiology strongly suggest that a substance as soluble as ascorbic acid goes through the glomerulus and is partly resorbed in the tubules. Our data do not permit a definite conclusion.



Fig. 6 Proximal and distal convoluted tubules. Same animal as figure 4. The reaction occurs only in the cytoplasm of the cells of the proximal convoluted tubules. The fragile membrane limiting the lumen of the proximal tubules has been destroyed by the silver nitrate fixation. The distal convoluted tubules are better preserved and show no ascorbic acid reaction. Camera lucida drawing.

CONCLUSIONS

1. A method for histological detection of ascorbic acid (vitamin C) has been devised and, the results being checked by chemical titrations, was applied to the study of the renal elimination of ascorbic acid in various circumstances.

2. Ascorbic acid is present in the kidneys of the rat, guinea pig, cat, sheep, pig, cow and horse.

3. It disappears progressively from the kidneys of guinea pigs receiving a diet without vitamin C, but persists in the kidneys of rats given the same diet.

4. After a single intravenous injection of 50 mg. of ascorbic acid into the guinea pig, the amount of this substance in the kidney becomes more than ten times, and in the urine more than 100 times, as high as in the normal animal.

5. Histologically no reaction appears in the glomerulus. The reaction is marked in the cells of the proximal convoluted tubules and the descending branch of Henle's loop. None is observed in the ascending branch of Henle's loop, the distal convoluted tubules, and the excretory ducts.

The authors wish to express their appreciation to Dr. E. Allen, Dr. W. U. Gardner and Mrs. C. P. Leblond for their help in the preparation of this manuscript and to Mr. H. Ants for the photographs.

LITERATURE CITED

Ahmad, B. 1936 Observations on excretion of vitamin C in human urine. Biochem. J., vol. 30, p. 11.

Archer, H. E. and G. Graham 1936 Some observations on excretion of ascorbic acid. Lancet, vol. 1, p. 710.

Armentano, L. 1936 Hämorrhagische Diathese und Vitamin C. Ztschr. f. Klin. Med., Bd. 129, S. 685.

Baena Baena, V. and A. Garcia Porrero 1936 Sobra hipoavitaminosis C. Med. Ibera., T. 1, p. 257.

Bessey, O. A. and C. G. King 1933 The distribution of vitamin C in plant and animal tissues and its determination. J. Biol. Chem., vol. 103, p. 687.

Bowman, D. E. and E. Muntwyler 1936 Further experiments upon the excretion of ascorbic acid in the urine following ether anesthesia. J. Biol. Chem., vol. 114, p. 14.

Casazza, R. 1936 Riserche dosimetriche sulla vitamina C in alcuni alimenti e nella urina dell'uomo. Arch. Ist. biochim. ital., T. 8, p. 39

De Caro, L. 1934 Ueber die Fähigkeit der Gewebe Ascorbinsäure zu fixieren. Z. f. Physiol. chem., Bd. 223, S. 229.

Drigalski, W. 1935 Ueber Vitamin C im Urin von Gesunden und Kranken. Klin. Wochschr., Bd. 14, S. 338.

Eekelen, M. van, A. Emmerie, B. Josephy and L. K. Wolff 1933 Vitamin C in blood and urine. Nature, vol. 132, p. 315.

EMMERIE, A. AND M. VAN EEKELEN 1934 The chemical determination of vitamin C with removal of interfering reducing and coloured substances. Biochem. J., vol. 28, p. 1153.

EULER, H. VON AND D. BURSTRÖM 1935 Ascorbinsäure Bestimmung im Harn durch Titration. Biochem. Ztschr., Bd. 283, S. 153.

GABBE, E. 1936 Vitamin-C studien an Harn und Blut. Klin. Wochnschr., Bd. 15, S. 292.

GIROUD, A., R. CHUC, R. RATSIMAMANGA AND C. P. LEBLOND 1935 Fixation et elimination de l'acide ascorbique. C. R. de Soc. Biol., T. 120, p. 330.

GIROUD, A. AND C. P. LEBLOND 1934 Recherches histochimiques sur la vitamine C dans l'organisme. Bull. de Soc. Ch. Biol., T. 16, p. 1352.

——— 1935 Histology and physiology of urinary elimination of vitamin C. Anat. Rec., vol. 64, Suppl. no. 1, p. 75.

HARRIS, L. J. AND S. N. RAY 1933 Vitamin C in the suprarenal medulla. Biochem. J., vol. 27, p. 2006.

HARRIS, L. J., S. N. RAY AND A. WARD 1933 The excretion of vitamin C in human urine and its dependence on the dietary intake. Biochem. J., vol. 27, p. 2011.

HAWLEY, E. E., D. J. STEPHENS AND G. ANDERSON 1936 The excretion of vitamin C in normal individuals following a comparable quantitative administration in the form of orange juice, cevitamic acid by mouth and cevitamic acid intravenously. J. Nutrition, vol. 11, p. 135.

HESS, A. F. AND H. R. BENJAMIN 1934 Urinary excretion of vitamin C. Proc. Soc. Exp. Biol. and Med., vol. 31, p. 855.

JEZLER, A. AND W. NIEDERBERGER 1936 Zur Methodik der Ascorbinsäurebestimmung im Urin. Klin. Wochnschr., Bd. 15, S. 710.

JOHNSON, S. W. AND S. S. ZILVA 1934 The urinary excretion of ascorbic and dehydroascorbic acids in man. Biochem. J., vol. 28, p. 1393.

KING, C. G. 1936 Vitamin C, ascorbic acid. Physiol. Reviews, vol. 16, p. 238.

KLODT, W. 1936 Ueber den chemischen Nachweis der Ascorbinsäure im Urin. Med. Klin., Bd. 32, S. 421.

LEBLOND, C. P. 1934 Recherches histochimiques sur la localisation et le cycle de la vitamine C dans l'organisme. Medical thesis. Paris.

LISON, L. 1936 Histochimie animale. Paris.

LOEPER, M., E. CHABROL, J. COTTET AND A. LESURE 1936 Elimination comparee de l'acide ascorbique par les glandes hepatique et renale. C. R. de Soc. Biol., T. 122, p. 404.

MARTINI, E. AND F. PINOTTI 1935 Acido ascorbico e deidroascorbico nell'urina di cavie normali e scorbutiche. Boll. Soc. ital. Biol. sper., vol. 10, p. 58.

MOURIQUAND, G. AND A. COEUR 1935 Precarence C experimentale et reaction de Bezssonoff. C. R. de Soc. Biol., T. 118, p. 566.

MOURIQUAND, G., L. WEIL AND F. SIMON 1934 Acide ascorbique, scorbut experimental et reaction de Bezssonoff. C. R. de Soc. Biol., vol. 116, p. 543.

RANDOIN, L. AND L. LOMBA 1923 Production de scorbut chez le cobaye et le lapin jeune au moyen d'un nouveau regime biochimiquement equilibre et seulement depourvu de facteur C. C. R. Acad. Sci., Paris, T. 176, p. 1003.

ROHMER, P., N. BEZSSONOFF AND E. STOERR 1934 Sur l'excretion urinaire de la vitamine C. C. R. de Soc. Biol., T. 116, p. 1414.

ROHMER, P., N. BEZSSONOFF, E. STOERR AND J. PERIER 1935 La teneur en vitamine C du sang et des urines apres injections massives. C. R. de Soc. Biol., T. 118, p. 1090.

SCHROEDER, H. 1935 Die Ausscheidung der Ascorbinsäure im gesunden und kranken organismen. Klin. Wochnschr., Bd. 14, S. 484.

SZENT-GYÖRGYI, A. 1928 Observations on the function of peroxydase systems and the chemistry of adrenal glands. Biochem. J., vol. 22, p. 1387.

WALLE, N. VAN DER 1922 The presence of the antineuritic and antiscorbutic vitamins in urine. Biochem. J., vol. 16, p. 713.

WIDENBAUER, F. 1936 Ascorbinsäure im Urin. Klin. Wochnschr., Bd. 15, S. 94.

ZILVA, S. S. 1925 Recent progress in the study of experimental scurvy. Proc. Roy. Soc. Med. (Sect. Therap.), vol. 18, p. 1.

THE SPEED OF TRAVEL OF RAM SPERMATOZOA

RALPH W. PHILLIPS AND FREDERIC N. ANDREWS
Massachusetts State College, Amherst, Massachusetts

The speed at which mammalian spermatozoa travel under their own power has been estimated at from 1 to 3.6 mm. per minute by various workers (Lott, 1872; Henle, 1873; Lloyd-Jones and Hays, '18; and Parker, '31).

The time required for the passage of ram spermatozoa from the vagina to the ovarian end of the fallopian tubes has been reported to be about 5 to 6 hours (Quinlan and Mare, '31; Green and Winters, '35). Assuming the same average length of the genital tract to be as is observed later the rate would be about 1.2 mm. per minute. With the figures obtained by these workers as a basis, an experiment was designed to determine if spermatozoa from another species would be transported through the reproductive tract of the ewe at the same rate as ram spermatozoa, and a second experiment was carried out to compare the speed at which ram spermatozoa travel in vivo with the rate they can travel in vitro.

SPEED OF TRAVEL IN THE REPRODUCTIVE TRACT

To compare the speed at which the spermatozoa of another species travel in the reproductive tract of the ewe with the speed of ram spermatozoa the rat was selected because of the difference in form of the spermatozoon of the two species.

The procedure used was to obtain rat spermatozoa by macerating an epididymis in a small quantity of Ringer's solution. A ram was then allowed to serve a ewe and the semen was immediately recovered from the vagina with a pipette. Equal amounts of ram semen and the suspension of rat spermatozoa were mixed together and immediately introduced into the anterior end of the vagina of an experimental ewe by means of a pipette.

THE ANATOMICAL RECORD, VOL. 68, NO. 1 AND SUPPLEMENT NO. 1

Seven ewes were available for this work and it was decided to slaughter the first one at 7 hours after insemination and that the time of slaughter of successive ewes would be determined by inspection of results as the work progressed. At the time of slaughter the reproductive tract was immediately removed and cut into sections as follows: Three equal sections of one fallopian tube, two sections of a uterine horn, body of uterus, cervix and vagina. The lumen of each section was washed with Ringer's solution, beginning with the section nearest the ovary and ending with the vagina. Smears were made of the washings, and after drying these were cleared

TABLE 1

The transport of ram and rat spermatozoa in the genital tract of the ewe

EWE NO.	LENGTH OF TRACT FROM EXTERNAL OS OF CERVIX TO OVARY (IN CENTIMETERS)	TIME FROM INSEMINATION TO SECTIONING OF TRACT	RAM SPERM IN UPPER SECTION OF FALLOPIAN TUBE	RAT SPERM PRESENT		
				Cervix	Uterus	Tubes
115[1]	37.2	30 min.	Yes	Yes	Yes	No
608	38.8	1 hr. 14 min.	Yes	Yes	Yes	Yes
766[1]	41.7	2 hrs.	Yes	Yes	Yes	Yes
27	39.5	3 hrs., 5 min.	Yes	Very few	No	No
28[1]	36.2	3 hrs., 59 min.	Yes	Yes	No	No
700	44.1	5 hrs., 12 min.	Yes	No	No	No
345[1]	36.3	7 hrs., 7 min.	Yes	Very few	Very few	Very few

[1] In heat when inseminated. Green and Winters ('35) report that oestrus does not affect the rate of travel.

with chlorazene, stained with Ziehl-Neelson's carbol-fuchsin, and examined.

The time of slaughter of each of the ewes and data concerning the length of the reproductive tract and presence or absence of ram and rat spermatozoa are given in table 1. The first ewe was slaughtered so that the tract was cut into sections at 7 hours and 7 minutes after insemination. Since ram sperm were present in all sections of the tract the next ewe was killed after a shorter time. This process was repeated until the tract of the last ewe was sectioned at 30 minutes after insemination and ram sperm were still present in all sections.

Rat sperm were observed in the fallopian tubes in only three cases. Apparently they traveled more slowly than ram spermatozoa, and if any reached the tubes in the other four cases they had degenerated before the tubes were washed. In those cases marked 'very few' in table 1 many of the heads had disappeared, leaving only tails.

These results indicate that the time required for ram sperm to reach the ovaries of the ewe is much shorter than that reported by Quinlan and Mare ('31), and by Green and Winters ('35). The conditions are different, however, since the ram semen used in the work herein reported was diluted with Ringer's solution and mixed with rat sperm. There is need for further work to determine the reason for the great differences in the results obtained.

SPEED OF TRAVEL OF RAM SPERMATOZOA IN VITRO

The method of studying the speed at which ram sperm are able to swim outside the body was to use glass tubes 12 mm. in diameter and 38.1 cm. long, with seven side tubes about 2 cm. long. These tubes were filled with Ringer's or 0.9% NaCl solutions and placed in a water bath held between 39 and 40°C. with all but the ends of the side tubes immersed. A depression at one end of the main tube prevented the drop of semen from flowing along the bottom when it was placed in the tube. At frequent intervals after placing a drop of fresh ram semen in one end of the tube sample drops were taken from the side openings and observed for the presence or absence of sperm. This was continued until sperm appeared at the opposite end of the tube.

The length of the tube used is similar to the distance the sperm must travel in the ewe from the external os of the cervix to the ovary. The average distance in the seven ewes described earlier was 39.1 cm.

The semen samples used were obtained from three normal rams showing an average of fifty-five abnormal spermatozoa per thousand. The significance of this figure as an index of normality is discussed elsewhere (McKenzie and Phillips, '36).

The tubes which have already been described had seven side tubes, hence six sections, each of which was 6.35 cm. long. In table 2 the number of minutes required for sperm to travel to the end of each section, the time required to traverse each section and the average speed in each section are shown.

The results obtained with Ringer's and 0.9% NaCl solutions were very similar so are not presented separately. Eighteen trials were made with Ringer's solution and seven with 0.9% NaCl solution.

The speed of travel in vitro is obviously slower than that observed in the genital tract of the ewe. The average speed

TABLE 2

Speed of travel of ram spermatozoa in vitro over a distance of 38.1 cm. long. Each section was 6.35 cm. long

Section no.	1	2	3	4	5	6
Average time to reach end of section (minutes)	4.11	9.28	27.10	35.21	49.03	76.79
Average time per section (minutes)	4.11	5.17	17.82	8.11	13.82	27.76
Speed per minute in each section (millimeters)	15.45	12.28	3.56	7.82	4.58	2.28

over the entire length in vitro was 4.83 mm. per minute while in the ewe slaughtered so that the genital tract was sectioned at 30 minutes after insemination the speed was 12.4 mm. per minute assuming that the full 30 minutes was required for the sperm to reach the upper end of the fallopian tubes. This is not surprising since many factors other than the swimming ability of the spermatozoa are known to be concerned in their transport through the female genital tract (Parker, '31; Hartman, '32 and Phillips, '36). It is also possible that the high rate of speed exhibited by sperm over the first two sections of the tubes described above may be maintained for a longer time in the female tract.

In addition to the work with normal spermatozoa, semen was obtained from two rams that had been inactive for a considerable time since the work was done in February, several months after the normal breeding season. A total of fourteen trials were made. In one ram 972 abnormal spermatozoa per 1000 were observed and spermatozoa did not travel beyond the second section of the tube. After being allowed several services the abnormality count dropped to 318 and sperm were observed at the end of the fifth section. In three trials made on the second ram, the abnormality count being 212 per 1000, spermatozoa reached the end of the fifth section in one case, the end of the sixth in another, and in the third failed to reach the end of the first section.

SUMMARY AND CONCLUSIONS

1. Ram sperm diluted in Ringer's solution had traversed the entire length of the genital tract in all the seven ewes studied, the times ranging from 30 minutes to 7 hours and 7 minutes after insemination. Other workers have reported the required time to be 5 to 6 hours. Conditions of the work herein reported differed from the earlier work in that the semen was diluted with Ringer's solution. Artificial insemination was used to insert the semen into the vagina. Further work is necessary to determine the reason for such widely different results.

2. Rat sperm apparently traverse the genital tract of the ewe at a slower rate than ram sperm.

3. Ram sperm in vitro traversed a distance similar to the length of the genital tract of the ewe in an average time of 76.79 minutes, a rate of 4.83 mm. per minute. The rate was much more rapid at first and gradually decreased.

4. The rate of travel in vitro is considerably slower than that observed in the genital tract of the ewe by the authors and somewhat faster than the rate reported by other workers.

LITERATURE CITED

GREEN, W. W. AND L. M. WINTERS 1935 Studies on the physiology of reproduction in the sheep. Anat. Rec., vol. 61, pp. 457–467.

HARTMAN, C. G. 1932 Ovulation and the transport and viability of ova and sperm in the female genital tract. Sex and Internal Secretions (Edgar Allen, editor), pp. 647–733. Williams and Wilkins, Baltimore.

HENLE, J. 1873 Handbuch der systematischen Anatomie des Menschen. II. Eingeweidelehre. Braunschweig, F. Vierveg and Son.

LLOYD-JONES, A. AND F. A. HAYES 1918 The influence of excessive sexual activity of male rabbits. I. On the properties of the seminal discharge. J. Exp. Zool., vol. 25, p. 463.

LOTT, G. 1872 Zur Anatomie und Physiologie des Cervix uteri. F. Enke, Erlangen, vol. 9, 150 pp.

MCKENZIE, F. F. AND R. W. PHILLIPS 1934 Measuring fertility in the ram. J. Am. Vet. Med. Assoc., vol. 84, pp. 189–202.

PARKER, G. H. 1931 The passage of sperms and eggs through the oviducts in terrestrial vertebrates. Phil. Tr. Roy. Soc., London, B, vol. 219, pp. 381–419.

PHILLIPS, R. W. 1936 The physiology of spermatozoa. Proc. Am. Soc. Animal Production for 1935, pp. 222–235.

QUINLAN, J. AND G. S. MARÉ 1931 Union S. Africa Department of Agriculture, Div. Vet. Serv. and Animal Industry Report, vol. 17, pp. 663–703.

NEW BOOKS AND PUBLICATIONS

MAMMALIAN ANATOMY WITH SPECIAL REFERENCE TO THE CAT, by Alvin Davison. Sixth edition, revised by Frank A. Stromsten (Princeton). 1937. Size, $5\frac{3}{4} \times 8\frac{3}{4}$ inches. Pages xiv + 328. 174 illustrations. Glossary. Index. Cloth. Price, $3.00. P. Blakiston's Son and Co., Inc., Philadelphia.

In addition to the chapters descriptive of mammalian systems and organs, this textbook supplies an introduction of particular interest to the beginning student. After a few definitions of anatomical terms and a brief classification of vertebrates and their phylogeny it takes up the principles of laboratory procedures. It gives simple and definite instructions on how to preserve material and to prepare specimens for dissection of the vascular system, muscles, peripheral nerves, viscera, central nervous system and osseous system. It also describes methods for making dried preparations, corrosion specimens and demonstrating the skeleton in embryos. Each chapter of the text is followed by a list of questions and suggestions for laboratory study. A glossary of terms and their derivations is convenient for reference.

EXPERIMENTAL AND CLINICAL STUDIES OF THE SPINE OF THE DOG, by Geoffrey Bernard Brook. 1936. Size, $5\frac{1}{2} \times 8\frac{3}{4}$ inches. Pages x + 122. Illustrated with 50 photographs arranged in 24 plates. List of references. Cloth. Price, $2.00. William Wood and Company, Baltimore.

This thesis will be of interest not only to the clinician engaged in diagnosis and treatment of diseases of the dog but also to the comparative worker utilizing observations on the lower animals in the study and elucidation of disease processes in man. The first part of the work describes the technique used by the author for cisternal puncture, its effects on the subject, the characters of normal cerebrospinal fluid and the clinical applications of the method. The second part discusses the characteristics of radiopaque oils, particularly lipiodol descendant, and their use for injection into the cisterna magna, in order to determine time of descent into the subarachnoid cul-de-sac, the conformation of the cul-de-sac, adhesions occurring in the course of a descent, movements of the oil after injection, and the effects of injection. It has definite clinical applications in the demonstration of certain spinal affections. An appendix calls attention to features of the spine of the dog which are important in interpreting photographs of a lipiodol injections.

PFITZNERS LEITFADEN FÜR SITUSÜBUNGEN AN DER LEICHE ZUM GEBRAUCHE BEI DEMONSTRATIONEN UND REPETITIONEN, by K. O. Henckel. Size $5\frac{1}{4} \times 7$ inches. 38 pages. Price, M 1.20. Franz Deuticke, Leipzig and Wien.

The ninth edition of this standard outline of regional anatomy of the cadaver has been revised to accord with the nomenclature adopted last year in Jena by the Anatomische Gesellschaft.

RIVISTA DI PARASSITOLOGIA. Publicata da A. Missiroli. Size, 7 × 10 inches. Published quarterly. Price per year, L. 90–. Rome.

This new publication, the first issue of which appeared in January, 1937, is the only periodical in Italy dealing exclusively with parasitology and it expects to publish the best of Italian research in the field. The first issue contains six original articles. Each article is supplied with a brief summary in Italian, English and German, and is followed by a list of references cited. A supplement to volume I gives a list and a description of all species of anopheline mosquitoes found in the Italian colonies.

SUPPLEMENT

PROCEEDINGS OF THE AMERICAN ASSOCIATION OF ANATOMISTS

FIFTY-THIRD SESSION

University of Toronto, Toronto, Canada,

March 25, 26 and 27, 1937

Thursday, March 25, 1937

10.00 a.m. The Fifty-third Session of the American Association of Anatomists was called to order by President Frederic T. Lewis, who announced the appointment of the following committees:

Auditing Committee: Prof. Ralph F. Shaner, Chairman; Prof. Chester H. Heuser.

Nominating Committee for 1938: Prof. Robert R. Bensley, Chairman; Prof. Clarence M. Jackson, Prof. Warren H. Lewis.

The remainder of the session was devoted to the presentation of scientific papers.

Friday, March 26, 1937

12 noon. Business Meeting, President Frederic T. Lewis in the chair. The Secretary-Treasurer reported that the minutes of the Fifty-second Session were printed in The Anatomical Record, vol. 65, no. 2 (supplement), pp. 1–50, inclusive. On motion, seconded and carried, the minutes were approved as printed.

Report of the Treasurer: The Secretary-Treasurer made the following report for the year 1936:

Balance on hand in checking account, December 31, 1935 (last audit of accounts)	$632.31	
Receipts from dues and abstracts, 1936	662.65	
Total credits		$1294.96
Expenditures, 1936:		
Postage, stationery, supplies	158.46	
Printing	38.00	
Programs, 52nd meeting	102.72	
Secretarial assistance	0.80	
Traveling expenses, secretary	69.08	
Wistar Institute (abstracts)	102.50	
Local Committee, 52nd meeting	150.00	
Lincoln-Alliance Bank (collection fee)	1.00	
Total expenditures		622.56
Balance on hand December 31, 1936, and deposited in the name of the American Association of Anatomists in the Lincoln-Alliance Bank and Trust Company, Rochester, N. Y.		672.40
Special interest account no. 19439, Lincoln-Alliance Bank		
Balance December 31, 1935	633.30	
Interest	12.72	
Balance December 31, 1936		646.02
Total balance		$1318.42

It will be noted that the general account shows an increase of $40.09 and the special account an increase of $12.72, making a total increase over last year of $52.81.

George W. Corner, *Treasurer.*

Report of the Auditing Committee: Professor Shaner reported as follows:

"The undersigned Auditing Committee has examined the accounts of the Secretary-Treasurer for the year 1936, and finds total receipts reported to be those entered in the journal, expenditures in accordance with receipted bills, and the balance on hand December 31, 1936, in agreement with the bank statement of that date and pass-book of special account."

(Signed) R. F. Shaner,
C. H. Heuser.

On motion, duly seconded, the reports of the Secretary-Treasurer and of the Auditing Committee were accepted and adopted.

Election of Officers: Prof. Eliot R. Clark, Chairman of the Committee on Nominations for 1937, placed the following nominations before the Association:

For Members of the Executive Committee, Prof. Wayne J. Atwell, of the University of Buffalo, and Prof. George B. Wislocki, of Harvard University.

On motion, seconded and carried, the Secretary was instructed to cast a ballot for the election of the above-named, with terms of office as specified in the Constitution of the Association.

Election of Representatives: The Secretary then read, on behalf of the Executive Committee, the following nominations: Representative on the Commission for the Standardization of Biological Stains, Prof. H. E. Jordan; Representatives on the Council of the American Association for the Advancement of Science, Prof. Ivan E. Wallin and Prof. Burton D. Myers; Representative to the National Research Council, Prof. Philip E. Smith.

The persons proposed were duly elected, with terms as specified in the Orders of the Association.

New Members: The Secretary presented the following names of persons recommended by the Executive Committee for the election to membership in the Association:

Allen, Lane H., M.S., Ph.D., Assistant Professor of Anatomy, *University of Georgia School of Medicine, Augusta, Ga.*

Andrew, Warren, M.S., Ph.D., Fellow in Anatomy, *University of Georgia School of Medicine, Augusta, Ga.*

Baker, Dan D., M.A., M.D., Assistant Professor of Anatomy, *Louisiana State University, Medical Center, New Orleans, La.*

Barnard, John W., M.S., Ph.D., Instructor in Anatomy, *University of Michigan, Ann Arbor, Mich.*

Benoit, Jacques, M.D., Professeur Agrégé d'Histologie, *Université de Strasbourg, Strasbourg, France.*

Blair, Duncan M., M.B., Ch.B., D.Sc., Professor of Anatomy, *University of Glasgow, Glasgow, Scotland.*

Bodian, David, S.B., Ph.D., Assistant in Anatomy, *The University of Chicago, Chicago, Ill.*

Book, M. H., M.D., Assistant in Histology, *Department of Anatomy, University of Toronto, Toronto 5, Canada.*

Brashear, Alton D., M.S., D.D.S., Instructor in Anatomy, *Louisiana State University, Medical Center, New Orleans, La.*

Campbell, Berry, A.B., Ph.D., National Research Council Fellow, *Department of Anatomy, Western Reserve University, 2109 Adelbert Rd., Cleveland, Ohio.*

Daron, Garman H., B.S., Ph.D., Instructor in Anatomy, *New York University, College of Medicine, 477 First Ave., New York City.*

Essenberg, J. M., Ph.D., Associate Professor of Anatomy, *Loyola University School of Medicine, Chicago, Ill.*

Foust, H. L., D.V.M., Professor of Veterinary Anatomy, *Iowa State College, Ames, Iowa.*

Godwin, Melvin C., B.A., Ph.D., Instructor in Anatomy, *West Virginia University, Morgantown, W. Va.*

Goldsmith, Joseph B., M.A., Ph.D., Associate Professor of Histology and Embryology, *Oklahoma University School of Medicine, Oklahoma City, Okla.*

Greep, Roy O., M.S., Ph.D., Research Assistant, *Biological Laboratories, Harvard University, Cambridge, Mass.*

Hamblen, E. C., M.D., Associate Professor of Obstetrics and Gynecology, *Duke University School of Medicine, Durham, N. C.*

Hamburger, Viktor, Ph.D., Assistant Professor of Zoölogy, *Washington University, St. Louis, Mo.*

Hamilton, James B., Ph.D., Instructor in Physiology, *Albany Medical College, Albany, N. Y.*

Hellbaum, Arthur A., Ph.D., Assistant Professor of Physiology, *University of Oklahoma, Oklahoma City, Okla.*

Huber, John F., M.D., Ph.D., Associate Professor of Anatomy, *Temple University, Philadelphia, Pa.*

Hummel, Katharine P., Ph.D., Instructor in Animal Nutrition, *Cornell University, Agricultural Experiment Station, Ithaca, N. Y.*

Humphrey, Tryphena, M.D., Ph.D., Instructor in Anatomy, *University of Michigan Medical School, Ann Arbor, Mich.*

Ingersoll, Everett H., Ph.D., Associate Professor of Anatomy, *Medical College of Virginia, Richmond, Va.*

Jones, Oliver P., Ph.D., Instructor in Anatomy, *University of Minnesota, Minneapolis, Minn.*

Kabat, Herman, Ph.D., Instructor in Physiology, *University of Minnesota, Minneapolis, Minn.*

Kirschbaum, Arthur, Ph.D., Fellow in Anatomy, *University of Minnesota, Minneapolis, Minn.*

Krehbiel, Robert H., M.S., Ph.D., Instructor in Anatomy, *University of Illinois, College of Medicine, 1853 W. Polk St., Chicago, Ill.*

Lachmann, Ernst, M.D., Assistant Professor of Anatomy, *University of Oklahoma School of Medicine, Oklahoma City, Okla.*

Lawless, John J., M.A., Ph.D., Assistant Professor of Anatomy, *West Virginia University School of Medicine, Morgantown, W. Va.*

Leblond, C. P., M.D., Assistant in Histology, *University of Paris, Paris, France.*

MARTIN, CECIL P., A.B., M.B., D.Sc., Professor of Anatomy, *McGill University, Montreal, Canada.*

PAFF, GEORGE H., Ph.D., Assistant Professor of Anatomy, *Long Island College of Medicine, 350 Henry St., Brooklyn, N. Y.*

PARKES, A. S., D.Sc., Member, *National Institute for Medical Research, Hampstead, London, N.W. 3, England.*

PEARSON, ANTHONY A., M.A., Ph.D., Instructor in Anatomy, *The University of Chicago, Chicago, Ill.*

QUIRING, D. P., M.A., Ph.D., Instructor in Biology, *Western Reserve University, Cleveland, Ohio.*

RAMSAY, ANDREW J., Ph.D., Associate in Histology and Embryology, *Jefferson Medical College, Philadelphia, Pa.*

SMITH, CARL G., M.D., Ph.D., Lecturer in Anatomy, *University of Toronto, Toronto 5, Canada.*

WARBRITTON, VIRGENE, M.A., Ph.D., Instructor in Animal Husbandry, *University of Missouri, College of Agriculture, Columbia, Mo.*

WESTON, JEAN K., M.S., Ph.D., Instructor in Anatomy, *University of Michigan, Ann Arbor, Mich.*

WOODBURNE, RUSSELL T., M.A., Ph.D., Instructor in Anatomy, *University of Michigan, Ann Arbor, Mich.*

YOUNG, M. WHARTON, M.D., Ph.D., Assistant Professor of Anatomy, *Howard University, Washington, D. C.*

On motion, duly seconded, the Secretary was instructed to cast a ballot for all candidates proposed by the Executive Committee.

Members deceased: The Secretary then presented the following statement of the Executive Committee:

The Association has suffered great loss by the death, during the past year, of four members

CHARLES E. JOHNSON, born April 24, 1880, died June 6, 1936. Elected to membership in 1914. Head of Department of Zoölogy, and Director of the Roosevelt Wild Life Forest Experiment Station, New York State College of Forestry, Syracuse, New York. Author of important contributions to natural history, and a pioneer in motion picture photography of animal life. An obituary notice appeared in Science, July 10, 1936.

K. OKAJIMA, elected to membership in 1920. Professor of Anatomy, Keio University Medical College, Tokyo, Japan.

RICHARD ROOT RUPERT, born January 1, 1882, died October 16, 1935. Elected to membership in 1920. Surgeon of S. S. American Trader.

SIR GRAFTON ELLIOT SMITH, born August 15, 1872, died January 1, 1937. Elected to membership in 1913. Professor of Anatomy in University College, London, England. Former President of the Anatomical Society of Great Britain and Ireland. A distinguished investigator and one of the leaders of British anatomy. An obituary notice appeared in Nature, January 9, 1937.

Members resigned: The Secretary then announced the resignation of the following members:

K. Kunitomo, Tokyo, Japan
John Sundwall, Ann Arbor, Mich.

Members dropped: The Secretary then announced the following names dropped from the list of members on account of non-payment of dues for the past 2 years:

F. E. Chidester, Morgantown, W. Va.
A. D. Robertson, London, Ontario, Canada

Payment to Local Committee: In accordance with the policy adopted by the Association at the Forty-third Session, it was moved, seconded, and voted that the Treasurer be authorized to pay the sum of $150.00 from the general funds of the Association to the local committee on arrangements at the University of Toronto, for the purpose of defraying the cost of entertainment of the Association during the present session.

Dues for the year 1937: A recommendation of the Executive Committee, that dues for the year 1937 be set at one dollar per member, was adopted by the Association.

Place of next meeting: It was announced that the Executive Committee had not yet decided upon the place at which the Fifty-fourth Session of the Association will be held.

Committee on Nomenclature: An informal report of the Committee on Anatomical Nomenclature was made by the chairman, C. M. Jackson. An account of the establishment of a permanent International Commission on Anatomical Nomenclature was published in The Anatomical Record, 1936, vol. 67, no. 1, pp. 1–6. This Commission adopted the NA system of nomenclature as the basis for revision, and requested that any desired changes be submitted before September, 1937. (The NA list was printed in the Anatomischer Anzeiger, Ergänzungsheft zum Band 81, 1936.)

Accordingly during the present year our American Committee has studied the question as to what changes should be proposed. Many difficult problems are involved. While the committee has not yet reached a final decision, it has agreed upon some questions of general policy. One is that in order to reconcile conflicting views it will be desirable for the present to use synonyms for some of the terms, as (for example) many of those of position and direction.

Any member of the Association may propose desired changes in the terms listed by the NA, and our committee would be glad to have these proposals for consideration. As the time is short, any such proposals should be submitted promptly, with reasons therefor. It is hoped that the final report of nomenclature with the recommended changes can be formulated in time to submit it to the Executive Committee of the Association for review and criticism before it goes to the International Commission.

The Business Session then adjourned.

Saturday, March 27, 1937

12.45 p.m. A business session followed the scientific sessions of the morning. The Secretary reported that there was no unfinished business.

Resolution of appreciation: Prof. T. Wingate Todd presented, through the Secretary, the following resolution, which was unanimously adopted:

For three days the American Association of Anatomists has enjoyed the welcome of His Majesty's Dominion of Canada and the generously expressed hospitality of the University of Toronto.

Assured by the gracious message from Lord Tweedsmuir, the Governor General; warmed by the felicitous phrases of Canon Cody, the President of the University; cheered by the genial presence of Professor McMurrich; beset about and about by myriad practical expressions of efficient preparation and organization on the part of Professor Grant, his colleagues and his Staff, for our ease, our comfort and the interchange of our scientific thought, we desire to record our appreciation and express our thanks to all those named and implied in this resolution.

We would have them know that human kindliness, hospitality and fellowship, no matter how certainly anticipated or relied upon, are experiences ever shiningly and exhilaratingly new. In joy of this realization we bear our witness and beg our hosts to accept this testimony.

There being no further business, the Fifty-third Session was concluded, in the afternoon, with the President's invitation program of scientific papers.

George W. Corner,
Secretary of the Fifty-third Session of
the American Association of Anatomists.

MESSAGE FROM THE GOVERNOR-GENERAL

At the annual dinner of the Association on Friday, March 26th, the president, Prof. Frederic T. Lewis, read the following message received from Lord Tweedsmuir, the Governor-General of Canada.

"Government House, Ottawa:

"It is with great pleasure that I welcome to Canada the American Association of Anatomists. Your coming is a further example of the fact that Science knows no political frontiers. You have my best wishes for the success of your deliberations.

TWEEDSMUIR."

It was announced that the following reply had been sent on behalf of the Association.

"His Excellency, the Governor-General. Government House, Ottawa:

"The American Association of Anatomists assembled at Toronto is gratified to receive Your Lordship's stimulating message. We would assure Your Excellency that Canadian and other American anatomists form what we call a syncytium."

ROUND TABLE DISCUSSIONS

Factors in sperm production. Chairman, Philip E. Smith. Participants: Earl T. Engle, Carl R. Moore, D. Roy McCullagh, Warren O. Nelson, Roy O. Greep, Harald Okkels.

A failure to produce precocious sexual maturity in male rats and in monkeys was reported. The time of maturity in male monkeys is correlated with size, appearing when a weight of 5 to 5.5 kg. is attained. In a discontinuous breeder—the ground squirrel—the seasonal development of sperm can be hastened by the injection of gonadotropic hormones even in the young animal. In the latter, maturity may have been retarded by a seasonal factor. Atrophy of the testes after hypophysectomy in rats can be prevented by administration of the androgens but repair after an atrophy cannot be obtained with these hormones. Progestin injections also prevent testicular atrophy after hypophysectomy. The failure of these substances to effect restoration contrasts with the results obtained from hypophyseal extracts with which restoration can be secured. The nature of the maintenance or restoration of the testes with hypophyseal extracts depends on

the type of preparation used. F.S.H. causes a tubule maintenance or restoration and L.H. a Leydig cell response with enlargement of the accessories. In monkeys a failure to maintain a normal testicular structure with the androgens and with certain gonadotropic extracts was reported. A large percentage of testes secured after accidental death and also under the Danish sterilization law were shown to deviate from what is usually considered to be a structurally normal organ.

The embryonic heart. Chairman, Bradley M. Patten. Participants, P. B. Armstrong, J. L. Bremer, W. M. Copenhaver, C. M. Goss, B. M. Patten and B. H. Willier.

In planning the round table on 'The embryonic heart,' an effort was made to assemble a group who would bring to bear on the subject widely different angles of approach. While this procedure did not call forth the argumentative discussion that sometimes follows the presentation of diverging conclusions from similar approaches, the interrelations of the diverse work brought out by the papers and further developed in the informal discussions seemed much appreciated by the group as a whole. In the opening paper, B. H. Willier discussed the localization of the heart-forming areas in pre-somite chicks as determined by the method of chorio-allantoic grafting. His results showed roughly eliptical areas lateral to Hensen's node, each exhibiting in its center a 90% potency for heart formation. Peripherally these areas showed a descending gradient in heart-forming potency. C. M. Goss presented his findings as to the normal sequence of fusion of the paired cardiac primordia of rat embryos grown in vitro, and the methods by which double hearts could be produced by mechanical interference with the fusion of the primordia. Goss then demonstrated with moving pictures the manner in which the early slow ventricular beat commenced, and the increase in rate which occurred with the incorporation of the subsequently formed sino-atrial region of the heart. B. M. Patten presented the results of work done in collaboration with Hoff, Kramer, and DuBois on the character of the early heart beat in the chick. An attempt was made to correlate electrocardiographic records taken at various stages in cardiac loop formation with the changes in rhythm, place of initiation beat, and direction of spread of the contraction as recorded by micromoving pictures during this phase of heart development. W. M. Copenhaver discussed the retention of species-specific morphological and physiological characteristics of cardiac tissue in heteroplastic grafts between Amblystoma punctatum and A. tigrinum. A gradient in the inherent contraction rate of different anteroposterior levels of the cardiac primordia was demonstrated for amphibia similar to that which Goss had reported for mammals and Patten for the chick. Copenhaver further analyzed this gradient in the light of a series of homo- and heteroplastic grafting experiments involving both normal and heterotopic placing of the grafts. J. L. Bremer demonstrated with micromoving pictures the presence of two spiral blood streams in the developing chick heart and analyzed in detail the possible effects the presence of such streams might have in moulding the cardiac septa. P. B. Armstrong first summarized the issues involved in recent work with neurohumors as they affect the heart, and then presented his own work along these lines with embryonic fish hearts. The effects of quantitatively accurate experiments with

acetylcholine were reported in detail and the responses as recorded by micro-cinematographs were demonstrated. Most striking was the absence of any vagomimetic effect in the aneural heart, and its consistent appearance after the innervation of the heart.

Each of the papers presented is covered by the author's own abstract in the March Anatomical Record in more detail than was feasible in this brief summary by the chairman.

Structure of the teeth. Chairman, T. Wingate Todd. Participants: Isaac Schour, B. Holly Broadbent, Lawrence W. Baker, Milo Hellman (not present), Alton D. Brashear, Harold L. Weatherford.

By micro-measurement of the deposition of enamel and dentine Isaac Schour showed that a growing tooth carries in the substance a dated register of constitutional changes. He hesitated to acknowledge an all-or-none principle in growth despite the suggestion from his preparations that growth presents a definite pattern of uniform velocity when not temporarily inhibited. B. Holly Broadbent demonstrated in serial roentgenograms converted into animated cartoons, the stages of development and eruption of milk and permanent dentitions. He showed the changes in axial position of growing teeth and their transit through the jaws in the course of eruption, thus differentiating incipient malocclusion from stages proper to the adjustment of the developing teeth to the growing jaws. Eruption of teeth is spasmodic and independent of growth at the root ends. Defects in developmental growth of the face are the principal cause of crowded teeth and prevents their normal eruption and alignment. L. W. Baker carried this theme further by showing in a series of clinical and experimental studies the real injury to growth of jaws necessarily inflicted by caries and subsequent loss of first permanent molars and by the enucleation of third molar buds the entirely normal position of which in their course of eruption is mistaken for incipient malocclusion. Milo Hellman intended to emphasize significant differences between the time schedules of permanent tooth eruption and of milk tooth shedding. Whereas there is delay both in shedding of lateral milk incisors and eruption of their successors in orphanage children as compared with children of economically stable families the reverse is true of the milk molars and their successors. Central incisors and canines show no such social-class distinction. Owing to preoccupation with the themes of growth and innervation the chairman was unable to press home distinction between the early appearing constitutional disturbances which result in tooth malformation and experimental procedures which result merely in disturbances of the eruption pattern. Alton D. Brashear made a striking analysis of the probable functions of nerve endings to teeth and peridental tissues based on Ranson's discrimination of nerve fibers (Science, 1933, vol. 78, pp. 395–399). He postulated tactile sense for large medullated fibers which end only in peridental tissues. Small medullated fibers to both tooth and surrounding tissues probably carry pain impulses and non-medullated fine fibers are responsible for the vasomotor impulses. Harold L. Weatherford confirmed Brashear's investigations on the variety and mode of termination of nerve fibers, emphasizing the absence of specialized endings. And the audience carried away a very clear impression that the teeth present a fertile and almost untouched field of investigation.

Present day trends of investigation in the field of gross anatomy. Chairman, Robert J. Terry. Participants: Harold Cummins, Charles H. Danforth, Dudley J. Morton, Gustave J. Noback, Richard E. Scammon, Walter E. Sullivan, I. Maclaren Thompson, T. Wingate Todd.

The wisdom of the president's choice of gross anatomy as a topic for one of the Round Table conferences was fully confirmed by good attendance at the session, and by a programme of pertinent subjects well presented and followed by interesting discussions. This should be the expectation for a field so long cultivated. Research in gross anatomy since the Vesalian reformation has yielded an enormous body of facts that are before us for reflection and interpretation. Those who are inclined to regard gross anatomy as sterile ground for research, unproductive of fruits and exciting no inspiration in the worker, have never really studied the gross structure of man. The great record of observations contributed by our predecessors will always be the subject of research. It will always be the purpose of anatomists to strive to reveal more completely the gross morphology that is now incompletely documented and crudely interpreted. Progress in this endeavor depends chiefly on the invention and application of new methods of approach. Some of these methods, and results obtained through them, were presented at this Round Table conference. If one may judge by the discussions at this session, a degree of interest was manifested that warrants the consideration of including gross anatomy as a special subject for subsequent round tables.

The first subject submitted for discussion, biological applications of dermatoglyphics, by Harold Cummins, brought forth evidence of great interest and value for the interpretation of symmetry and particularly of handedness.

Charles H. Danforth contrasted the earlier point of view in the investigation of variations in man (the search for homologies) and the recent attitude toward their genetic interpretations for which materials may be found to some extent in the dissecting room, citing examples of such studies.

The existence of the transverse metatarsal arch of the textbooks on human anatomy was robbed of its venerable status by Dudley J. Morton's demonstrations of evidence, human and primate, physiologic and evolutionary.

Valuable contributions to the little known subject of infant and fetal gross anatomy were presented by Gustave J. Noback's discussion of the topography of the thorax, dealing specially with the relations of the thymus, lung and the arterial duct.

Richard E. Scammon's comprehensive review and critical evaluation of standard methods of measurement which are applicable in the study of anatomy was a valuable exposition of one of the modern techniques which is uncovering new facts and broadening our understanding of human form and structure.

Time did not permit for the discussion it deserved of Walter E. Sullivan's excellent illustration by lantern pictures and comments of the progress being made in gross anatomy by means of the x-ray, or of experimental methods of investigation exemplified in the ingenious techniques for the study of the cutaneous nerve distribution of I. Maclaren Thompson. For the same reason the important subject of age changes in the growing body, to have been presented by T. Wingate Todd, could not be included.

The structure of neurons and its functional significance. Chairman, D. M. Rioch, Participants: H. S. Gasser, J. C. Hinsey, J. F. Nonidez, Marion Hines, N. L. Hoerr, Leo Alexander, S. W. Ranson.

H. S. Gasser introduced the subject with a critical review of the known functions of neurons. He pointed out that the neuron is distinctive chiefly due to its shape, the many branched processes providing the possibility of great numbers of connections with other cells. He emphasized the functional similarity of the axon and cell body as to latent period, summation time, action current, recovery curve, metabolism, etc.

J. C. Hinsey presented the concept of self-reexciting chains of internuncial neurons and the subject was further discussed by S. W. Ranson. The anatomical basis of the concept was supplied by the studies of R. Lorente de Nó with the Golgi method. The application of the concept to describe the mechanism of long after-discharge and of rhythmical activity, such as that of the respiratory center, was illustrated.

J. F. Nonidez demonstrated splendid examples of synapses in the ganglia attached to the right cardiac nerve of the rabbit, cat and dog with the Cajal method, confirming the view of De Castro, Lawrentjew and Fedorow. In studying nerve terminations on the walls of blood vessels and on the heart muscle, Nonidez found that all terminations of efferent type were epilemmal. He also showed examples of terminations of afferent fibers in these localities. His preparations demonstrated amply that the delicate meshwork stained by the ammoniacal silver solution of the Bielschowsky-Gros technique (compare Boeke, Stöhr, etc.) consists of argyrophile connective tissue fibers.

Marion Hines presented a masterly summary of the classification of motor endings on skeletal muscle from the viewpoint of comparative morphology. The muscles of tailed amphibians, reptiles and certain mammalian muscles not attached to bone (e.g., extra-ocular muscles, tongue, etc.), have several different types of endings, some of which may be either hypo- or epilemmal. Muscles with highly developed sensory end organs, muscle spindles, have a single type of motor ending, the motor end plate. That the latter is fundamentally epilemmal is adduced from the observations of Sarah Tower (abstract 112).

N. L. Hoerr reviewed the studies of neurons made with the Altmann freezing-drying method and emphasized the normal presence of neurofibrillae as clearly defined structures running a straight course through the cell body and axon. No membrane on either axon or cell body is visible. In other studies, using the Cajal method, he was unable to confirm the findings of Hoff with regard to degeneration of terminal knobs on the anterior horn cells after section of descending tracts. A. T. Rasmussen concurred in this conclusion.

Leo Alexander discussed the micro-incineration method as applied to nervous tissue and showed that the axon contains less mineral than the cell body as a whole, but appears to be similar to the cytoplasm between the Nissl granules. He further concluded that various types of neurons differ in their mineral content and that developing neurons have a higher mineral content that mature ones.

Blood capillaries. Chairman, E. V. Cowdry. Participants: B. W. Zweifach, Robert Chambers, Eliot R. Clark, Eleanor L. Clark, James B. Rogers, Richard G. Abell.

The chairman found it impracticable to furnish a summary of this discussion.

AMERICAN ASSOCIATION OF ANATOMISTS

OFFICERS AND LIST OF MEMBERS

Officers

President.....Frederic T. Lewis
First Vice-President.....Harvey E. Jordan
Second Vice-President.....Charles H. Danforth
Secretary-Treasurer.....George W. Corner

Executive Committee

For term expiring 1938.....Andrew T. Rasmussen, Philip E. Smith
For term expiring 1939.....Lewis H. Weed, Richard E. Scammon
For term expiring 1940.....Harold Cummins, George W. Bartelmez
For term expiring 1941.....Wayne J. Atwell, George B. Wislocki

Delegates to the Council of A.A.A.S. for 1937

Ivan E. Wallin
Burton D. Myers

Representative to the National Research Council, 1937–1940

Philip E. Smith

Member of the Commission on Standardization of Biological Stains

Harvey E. Jordan

Delegate to Union of Biological Societies, 1935–1938

Stacy R. Guild

Committee on Nominations for 1938

Robert R. Bensley, *Chairman*
Clarence M. Jackson Warren H. Lewis

Committee on Anatomical Nomenclature

Clarence M. Jackson, *Chairman*
Stephen W. Ranson Robert J. Terry T. Wingate Todd
George W. Corner, *Secretary*

Honorary Member

A. Nicholas.....*Paris, France*

MEMBERS

ABBOTT, MAUDE E., B.A., C.M., M.D., L.R.C.P. & S. (Edin.), F.R.C.P. (Canada), Assistant Professor of Research Medicine and Curator of Medical Historical Museum, McGill University, McGill Medical Museum, *3640 University St., Montreal, Canada.*

ABELL, RICHARD G., Ph.D., Fellow in Anatomy, *University of Pennsylvania School of Medicine, Philadelphia, Pa.*

ABERLE (MRS.) SOPHIE B. D., A.B., A.M., Ph.D., M.D., Superintendent of Pueblo Agency, Research Professor of Anatomy, *University of New Mexico, Albuquerque, New Mexico.*

ADAMS, A. ELIZABETH, A.B., A.M., Ph.D., Professor of Zoölogy, *Mount Holyoke College, South Hadley, Mass.*

ADAMS, L. A., A.B., A.M., Ph.D., Associate Professor of Zoölogy, *University of Illinois, 401 Vermont St., Urbana, Ill.*

ADDISON, WILLIAM HENRY FITZGERALD, B.A., M.D., Professor of Normal Histology and Embryology, *School of Medicine, University of Pennsylvania, Philadelphia, Pa.*

ADELMANN, HOWARD B., B.A., M.A., Ph.D., Assistant Professor of Histology and Embryology, *Cornell University, Stimson Hall, Ithaca, N. Y.*

ALLEN, BENNET MILLS, Ph.D., Professor of Zoölogy, University of California at Los Angeles, *909 Micheltorena St., Los Angeles, Calif.*

ALLEN, EDGAR, A.M., Ph.D., Sc.D., (Vice-Pres. '30–'32), Professor of Anatomy, Yale University School of Medicine, *333 Cedar St., New Haven, Conn.*

ALLEN, EZRA, A.M., Ph.D., Associate Professor of Histology and Embryology, *New York Medical College, 450 East 64th St., New York City.*

ALLEN, LANE H., M.S., Ph.D., Assistant Professor of Anatomy, *University of Georgia School of Medicine, Augusta, Ga.*

ALLEN, WILLARD M., B.S., M.S., M.D., *University of Rochester, School of Medicine and Dentistry, Rochester, N. Y.*

ALLEN, WILLIAM F., A.M., Ph.D., Head of Department of Anatomy, *University of Oregon Medical School, Portland, Ore.*

ALLIS, EDWARD PHELPS, JR., C.E., M.D., LL.D., *Palais de Carnoles, Menton (A.M.), France.*

ANDERSEN, DOROTHY H., Associate in Pathology, Columbia University; Assistant Pathologist, *Babies' Hospital, 167th St. and Broadway, New York City.*

ANDREW, WARREN, M.S., Ph.D., Fellow in Anatomy, *University of Georgia School of Medicine, Augusta, Ga.*

ANGULO Y GONZALEZ, ARMANDO W., A.B., B.S., A.M., Ph.D., Associate Member, *The Wistar Institute of Anatomy, Woodland Ave. and 36th St., Philadelphia, Pa.*

ANSON, BARRY J., A.B., A.M., Ph.D., Associate Professor of Anatomy, *Northwestern University Medical School, 303 East Chicago Ave., Chicago, Ill.*

Appleby, J. I., A.B., M.B., A.M., M.D., Physician and Surgeon, Company Surgeon, N. Y. C. & St. L. R. R. Co., *105½ East Main St., Bellevue, Ohio.*

Arey, Leslie B., Ph.D. (Ex. Com. '30–'34), Robert Laughlin Rea Professor of Anatomy, and Chairman of the Division of Anatomy, *Northwestern University Medical School, 303 East Chicago Ave., Chicago, Ill.*

Armstrong, Philip Brownell, B.S., M.D., Assistant Professor of Anatomy, *Cornell University Medical College, 1300 York Ave., New York City.*

Asdell, Sydney Arthur, M.A., Ph.D., Professor of Animal Physiology, State College of Agriculture, *Cornell University, Ithaca, N. Y.*

Atterbury, Ruth Rand, A.M., Ph.D., *Kings' Point, Great Neck, L. I.*

Atwell, Wayne Jason, A.M., Ph.D., M.D., (Exec. Com. '37–) Professor of Anatomy, University of Buffalo School of Medicine, *24 High St., Buffalo, N. Y.*

Badertscher, Jacob A., Ph.D., Professor of Anatomy, Indiana University School of Medicine, *312 South Fess Ave., Bloomington, Ind.*

Bagley, Charles, Jr., M.D., Assoc. Experimental Neurology, *The Latrobe Apts., Baltimore, Md.*

Bailey, Percival, M.D., Ph.D., Professor of Surgery, *The University of Chicago, 950 East Fifty-ninth St., Chicago, Ill.*

Baitsell, George Alfred, B.S., M.A., Ph.D., Professor of Biology, Yale University, *Osborn Zoölogical Laboratory, New Haven, Conn.*

Baker, Dan D., M.A., M.D., Assistant Professor of Anatomy, *Louisiana State University, Medical Center, New Orleans, La.*

Baker, R. C., A.B., M.A., Ph.D., Professor of Anatomy, *Department of Anatomy, Hamilton Hall, Ohio State University, Columbus, Ohio.*

Baker, Roger D., M.D., Assistant Professor of Pathology, *Duke University, Durham, N. C.*

Baldwin, Wesley Manning, A.B., A.M., M.D., *Stimson Hall, Ithaca, N. Y.*

Barnard, John W., M.S., Ph.D., Instructor in Anatomy, *University of Michigan, Ann Arbor, Mich.*

Barris, Ralph W., Ph.D., Assistant Professor of Anatomy, *George Washington University Medical School, Washington, D. C.*

Barron, Donald H., B.A., M.S., Ph.D., Lecturer in Anatomy, *Department of Anatomy, Cambridge University, England.*

Barta, Edmund, M.D., Adjunct (Em.), Department of Anatomy, Histology and Embryology, *University Medical School, Kisvarda, Szabolcs-m., Hungary.*

Bartelmez, George W., Ph.D. (Vice-Pres. '32–'34, Exec. Com. '36–), Professor of Anatomy, *The University of Chicago, Chicago, Ill.*

Bartsch, Paul, B.S., M.S., Ph.D., Curator of Mollusks and Cenozoic Invertebrates, *U. S. National Museum, Washington, D. C.*

Bast, T. H., B.A., Ph.D., Professor of Anatomy, *University of Wisconsin, 308 Science Hall, Madison, Wisc.*

Batson, O. V., A.M., M.D., Professor of Anatomy, *Department of Anatomy, Graduate School of Medicine, University of Pennsylvania, Philadelphia, Pa.*

Baumgartner, William J., A.B., A.M., Ph.D., Professor of Zoölogy, University of Kansas, *1209 Ohio St., Lawrence, Kans.*

Baxter, James S., B.M., B.Ch., M.Sc., F.R.C.S., University Demonstrator in Anatomy, *Anatomy School, New Museums, Cambridge, England.*

BEAN, ROBERT BENNETT, B.S., M.D., Professor of Anatomy, University of Virginia, *Box 1536, University, Va.*

BEATTIE, JOHN, M.D., D.Sc., Conservator of Museum and Director of Research, *Royal College of Surgeons, Lincoln's Inn Fields, London, W.C.2, England.*

BEGG, ALEXANDER S., B.S., M.D., Waterhouse Professor of Anatomy and Dean, Boston University School of Medicine, *80 East Concord St., Boston, Mass.*

BENOIT, JACQUES, M.D., Professeur Agrégé d'Histologie, *Université de Strasbourg, Strasbourg, France.*

BENSLEY, ROBERT RUSSELL, A.B., M.B., Sc.D. (Second Vice-Pres. '06–'07, Ex. Com. '08–'12, President '18–'20), Professor Emeritus of Anatomy, *The University of Chicago, Chicago, Ill.*

BENSLEY, SYLVIA H., M.D., Instructor in Anatomy, *Department of Anatomy, The University of Chicago, Chicago, Ill.*

BEST, R. RUSSELL, B.Sc., M.D., Assistant Professor of Anatomy, Assistant Professor of Surgery, University of Nebraska, College of Medicine, *527 Medical Arts Building, Omaha, Neb.*

BEVAN, ARTHUR DEAN, M.D. (Ex. Com. '96–'98), Professor of Surgery, The University of Chicago, *122 South Michigan Blvd., Chicago, Ill.*

BIGELOW, ROBERT P., S.B., Ph.D., Professor Emeritus of Zoölogy and Parasitology, Massachusetts Institute of Technology, *72 Blake Rd., Brookline, Mass.*

BISHOP, KATHERINE SCOTT, A.B., M.D., *1508 La Loma Ave., Berkeley, Calif.*

BLAIR, DUNCAN M., M.B., Ch.B., D.Sc., Professor of Anatomy, *University of Glasgow, Glasgow, Scotland.*

BLAIR, VILRAY PAPIN, A.M., M.D., Professor of Clinical Surgery, Washington University School of Medicine, *Metropolitan Building, St. Louis, Mo.*

BLAISDELL, FRANK ELLSWORTH, SR., M.D., Emeritus Professor of Surgery, Medical Department of Stanford University, *Lane Medical Library Building, corner Webster and Sacramento Sts., San Francisco, Calif.*

BLAKE, J. A., A.B., Ph.B., M.A., M.D., F.A.C.S., *R.F.D. 1, Franklin, Maine.*

BLINCOE, HOMER, A.B., M.S., M.D., Professor of Gross Anatomy, *Emory University, Emory, Ga.*

BLOOM, WILLIAM, A.B., M.D., Associate Professor of Anatomy, *Department of Anatomy, The University of Chicago, Chicago, Ill.*

BLOUNT, R. F., M.S., Ph.D., Assistant Professor in Anatomy, *University of Minnesota, Minneapolis, Minn.*

BLUMENFELD, CHARLES M., Ph.D., M.D., Associate Professor of Anatomy, *University of Utah, School of Medicine, Salt Lake City, Utah.*

BODIAN, DAVID, S.B., Ph.D., Assistant in Anatomy, *The University of Chicago, Chicago, Ill.*

VON BONIN, GERHARDT, M.D., Associate Professor of Anatomy, University of Illinois, College of Medicine, *1853 West Polk St., Chicago, Ill.*

BOOK, M. H., M.D., Assistant in Histology, *Department of Anatomy, University of Toronto, Toronto 5, Canada.*

BOWIE, DONALD J., B.Sc., Ph.D., Lecturer in Histology, *McGill University, Montreal, Canada.*

BOYD, EDITH, M.D., Assistant Professor of Anatomy, *University of Minnesota, Minneapolis, Minn.*

Boyden, Edward Allen, A.M., Ph.D. (Ex. Com. '28–'32), Professor of Anatomy, *Institute of Anatomy, University of Minnesota, Minneapolis, Minn.*

Brashear, Alton D., M.S., D.D.S., Instructor in Anatomy, *Louisiana State University, Medical Center, New Orleans, La.*

Bremer, John Lewis, A.B., M.D. (Ex. Com. '15–'18, '33–'37), Hersey Professor of Anatomy, *Harvard Medical School, Boston, Mass.*

Browning, William, Ph.B., M.D., Emeritus Professor of Neurology, Long Island College of Medicine, *54 Lefferts Place, Brooklyn, N. Y.*

Bryce, Thomas H., M.A., M.D., F.R.S., Emeritus Professor of Anatomy, University of Glasgow, *The Loaning, Peebles, Scotland.*

Bullard, H. Hays, A.M., Ph.D., M.D., *St. Vincent's Hospital, Erie, Pa.*

Bunting, Charles Henry, B.S., M.D., Professor of Pathology, *University of Wisconsin, Service Memorial Institute, Madison, Wisc.*

Burns, B. I., A.B., A.M., Ph.D., M.D., Professor of Anatomy, *Louisiana State University Medical Center, New Orleans, La.*

Burns, Robert K., Jr., A.B., Ph.D., Associate Professor of Anatomy, *University of Rochester School of Medicine and Dentistry, Rochester, N. Y.*

Burr, Harold Saxton, Ph.D. (Ex. Com. '29–'33), E. K. Hunt Professor of Anatomy, Head of the Section of Neuro-Anatomy, School of Medicine, Yale University, *333 Cedar St., New Haven, Conn.*

Burrows, Montrose T., A.B., M.D., Physician and Surgeon, Consultant Pathologist, Los Angeles County General Hospital, Member Senior Staff, Pasadena and St. Luke's Hospitals, *201 North El Malino Ave., Pasadena, Calif.*

Butcher, Earl O., A.M., Ph.D., Professor of Biology, *Hamilton College, Griffin Road, College Hill, Clinton, N. Y.*

Butler, Elmer G., A.B., Ph.D., Associate Professor of Biology, *Laboratory of Comparative Anatomy, Princeton University, Princeton, N. J.*

Buyse, Adrian, A.B., Ph.D., Assistant Professor in Zoölogy, *The University of Rochester, Rochester, N. Y.*

Calkins, Leroy A., M.S., M.D., Ph.D., Professor of Obstetrics and Gynecology, *University of Kansas Hospital, Kansas City, Kan.*

Cameron, Angus L., A.B., M.S., M.D., Ph.D., *Northwest Clinic, Minot, N. Dak.*

Campbell, Berry, A.B., Ph.D., National Research Council Fellow, *Department of Anatomy, Western Reserve University, 2109 Adelbert Rd., Cleveland, Ohio.*

Cardwell, John C., M.D., Professor of Physiology, Long Island College of Medicine, Science Laboratory, *112 Pacific St., Brooklyn, N. Y.*

Carey, Eben J., M.S., Sc.D., M.D., Dean and Professor of Anatomy and Director of Anatomy Department, Marquette University School of Medicine, *6119 W. Wisconsin Ave., Wauwatosa, Wisc.*

Carpenter, Russell L., B.S., Ph.D., Assistant Professor of Anatomy, *College of Physicians and Surgeons, Columbia University, 630 West 168th St., New York City.*

Carver, Gail L., A.B., A.M., Professor of Biology, *Mercer University, Macon, Ga.*

Casamajor, Louis, A.M., M.D., Professor of Neurology, *Columbia University, 630 West 168th St., New York City.*

Chambers, Robert, Jr., A.M., Ph.D., Research Professor of Biology, *New York University, New York City.*

Chandler, Simon B., A.B., A.M., M.D., Professor of Anatomy, *West Virginia University School of Medicine, Morgantown, W. Va.*

CHANG, CHUN, M.D., Associate Professor of Anatomy, *National Medical College of Shanghai, 373 Ave. Haig, Shanghai, China.*

CHARIPPER, HARRY A., B.S., M.S., Ph.D., Associate Professor of Biology (Tissue Cytology, Endocrinology and Histology), Chairman of Department, *Washington Square College, New York University, New York City.*

CHARLES, CECIL M., A.B., M.A., Ph.D., M.D., Instructor, Department of Anatomy, *Washington University School of Medicine, St. Louis, Mo.*

CHASE, SAMUEL WOOD, A.B., A.M., Ph.D., Associate Professor of Histology and Embryology, *Western Reserve University, 2109 Adelbert Road, Cleveland, Ohio.*

CHILD, CHARLES MANNING, M.S., Ph.D., D.Sc., Professor Emeritus of Zoölogy, *Zoölogical Laboratory, The University of Chicago, Chicago, Ill.*

CHILLINGWORTH, FELIX P., M.D., Professor of Experimental Pharmacology, Tufts Medical College, *416 Huntington Ave., Boston, Mass.*

CHOUKE, KEHAR SINGH, M.A., M.D., Assistant Professor of Anatomy, *Colorado University Medical School, 4200 East Ninth Ave., Denver, Colo.*

CHRISTENSEN, KERMIT, Ph.D., Instructor in Microanatomy, *St. Louis University School of Medicine, 1402 South Grand Blvd., St. Louis, Mo.*

CLARK, ELEANOR LINTON, A.M., Voluntary Research Worker, Department of Anatomy, *Medical Department, University of Pennsylvania, Philadelphia, Pa.*

CLARK, ELIOT R., A.B., M.D., (Ex. Com. '16–'19), Professor of Anatomy and Director of Department of Anatomy, *Medical Department, University of Pennsylvania, Philadelphia, Pa.*

CLARK, SAM L., M.S., Ph.D., M.D., Associate Professor of Anatomy, *Vanderbilt University School of Medicine, Nashville, Tenn.*

CLEVELAND, RUCKER, Ph.D., Assistant in Anatomy, *Vanderbilt University School of Medicine, Nashville, Tenn.*

COBB, W. MONTAGUE, M.D., Ph.D., Associate Professor of Anatomy, *Howard University, Washington, D. C.*

COE, WESLEY R., Ph.D., Professor of Biology, *Yale University, Osborn Zoölogical Laboratory, New Haven, Conn.*

COGHILL, GEORGE E., A.B., M.S., Ph.D., Sc.D. (Ex. Com. '27–'31, Pres. '32–'34), *409 East Union St., Gainesville, Fla.*

COHN, ALFRED E., A.B., M.D., Member, *Rockefeller Institute for Medical Research, New York City, N. Y.*

COLE, ARCH EVAN, A.B., Ph.D., Assistant Professor, Anatomy Department, *University of Louisville, Louisville, Kentucky.*

COLE, ELBERT C., Ph.D., Professor of Biology, *Williams College, Williamstown, Mass.*

COLE, HAROLD H., Ph.D., Associate Professor of Animal Husbandry, University of California, and Associate Animal Husbandman, *Experiment Station of the College of Agriculture, Davis, Calif.*

COLLINGS, M. RAYMOND, A.B., M.D., Associate Professor of Anatomy, Medical College, Wayne University, *1512 St. Antoine St., Detroit, Mich.*

COLLINS, HENRY HOMER, Ph.D., Professor of Zoölogy, *University of Pittsburgh, Pittsburgh, Pa.*

COMAN, DANA, A.B., A.M., M.D., Assistant in Psychiatry, Johns Hopkins University, *Johns Hopkins Medical School, Baltimore, Md.*

CONEL, JESSE LEROY, A.M., Ph.D., Professor of Anatomy, Boston University School of Medicine, *80 E. Concord St., Boston Mass.*

CONGDON, EDGAR DAVIDSON, Ph.D., Professor of Anatomy, *Long Island College of Medicine, 350 Henry St., Brooklyn, N. Y.*

CONKLIN, EDWIN GRANT, A.M., Ph.D., Sc.D., LL.D., Professor Emeritus of Biology, Princeton University, *139 Broadmead Ave., Princeton, N. J.*

COPENHAVER, WILFRED M., A.B., Ph.D., Assistant Professor of Anatomy, *College of Physicians and Surgeons, Columbia University, 630 West 168th St., New York City.*

COREY, EDWARD LYMAN, A.B., Ph.D., Assistant Professor of Physiology, *University of Virginia School of Medicine, University, Va.*

CORNER, GEORGE W., A.B., M.D. (Ex. Com. '26–'30, Sec.-Treas. '30–), Professor of Anatomy, *University of Rochester, Crittenden Boulevard, Rochester, N. Y.*

CORNING, H. K., M.D., Professor of Anatomy (retired), *University of Bâle, Anatomische Anstalt, Bâle, Pestalozzistr. 20, Switzerland.*

COVELL, W. P., M.S., Ph.D., M.D., Associate Professor of Research Medicine, *George Williams Hooper Foundation, San Francisco, Calif.*

COWDRY, EDMUND V., Ph.D. (Ex. Com. '26–'30, 1st Vice-Pres. '34–'36), Professor of Cytology, *Washington University Medical School, St. Louis, Mo.*

CRAIGIE, E. HORNE, B.A., Ph.D., Associate Professor of Comparative Anatomy and Neurology, *Department of Biology, University of Toronto, Toronto, 5, Canada.*

CRILE, GEORGE W., M.D., F.A.C.S., Professor Emeritus of Surgery, Western Reserve University; Director, Cleveland Clinic Foundation; Surgeon, Cleveland Clinic Hospital; *Cleveland Clinic, 93rd and Euclid, Cleveland, Ohio.*

CROSBY, ELIZABETH CAROLINE, M.S., Ph.D., Professor of Anatomy, University of Michigan, *521 Elizabeth St., Ann Arbor, Mich.*

CROUCH, RICHARD L., Ph.D., Assistant Professor of Anatomy, *University of Missouri, Columbia, Mo.*

CUAJUNCO, FIDEL, M.D., Assistant Professor of Anatomy, College of Medicine, University of the Philippines, *620 Colorado St., Manila, P. I.*

CULLEN, THOMAS S., M.B., D.Sc., LL.D. (Tor.), Professor of Gynecology, Johns Hopkins University, Gynecologist to the Johns Hopkins Hospital, *20 E. Eager St., Baltimore, Md.*

CUMMINS, HAROLD, A.B., Ph.D. (Ex. Com. '36–), Professor and Head of Division of Microscopic Anatomy, *Tulane University Medical School, Department of Anatomy, Sta. 20, New Orleans, La.*

CUNNINGHAM, ROBERT S., B.S., A.M., M.D. (Ex. Com. '32–'36), Professor of Anatomy, *Vanderbilt University School of Medicine, Nashville, Tenn.*

CURTIS, GEORGE M., A.M., Ph.D., M.D., Professor of Surgery and of Surgical Research, *Kinsman Hall, Ohio State University, Columbus, Ohio.*

DANFORTH, CHARLES HASKELL, A.M., Ph.D. (Ex. Com. '27–'31, Second Vice-Pres. '36–), Professor of Anatomy, Stanford University, *607 Cabrillo Ave., Stanford University, Calif.*

DARDINSKI, VINCENT J., M.D., Ph.D., Professor of Anatomy, *Georgetown University, School of Medicine, Washington, D.C.*

DARON, GARMAN H., B.S., Ph.D., Instructor in Anatomy, *New York University, College of Medicine, 477 First Ave., New York City.*

DARRACH, WILLIAM, A.B., A.M., M.D., Sc.D., LL.D., Professor of Clinical Surgery and Dean Emeritus of Faculty of Medicine, College of Physicians and Surgeons, Columbia University, *180 Fort Washington Ave., New York City.*

DART, RAYMOND A., M.D., Ch.M., M.Sc., Professor of Anatomy and Dean of Faculty of Medicine, *University of the Witwatersrand, Johannesburg, Transvaal, South Africa.*

DAVENPORT, H. A., M.D., Associate Professor of Anatomy, *Northwestern University Medical School, Chicago, Ill.*

DAVIS, CARL L., M.D., Professor of Anatomy, University of Maryland School of Medicine, *Lombard and Greene Sts., Baltimore, Md.*

DAVIS, WARREN B., M.D., F.A.C.S., Clinical Professor of Oral Surgery, Jefferson Medical College; Maxillo-Facial Surgeon, Jefferson Hospital; Consulting Maxillo-Facial Surgeon, Kensington Hospital and Frankford Hospital; Consulting Otolaryngologist, St. Agnes Hospital; *135 S. 18th St., Philadelphia, Pa.*

DAWSON, ALDEN B., A.B., Ph.D., Associate Professor of Zoölogy, and Director of the Biological Laboratories, *Biological Laboratories, Harvard University, Cambridge, Mass.*

DAY, CAMERON D., Ph.D., Professor of Zoölogy, *Westminster College, Fulton, Mo.*

DE CARLO, JOHN, M.D., Associate in Topographic and Applied Anatomy, Jefferson Medical College, *1629 S. Broad St., Philadelphia, Pa.*

DEES-MATTINGLY, MARIE, A.B., B.S., M.D., Associate Professor of Anatomy, *Tulane University of Louisiana, New Orleans, La.*

DE GARIS, CHARLES F., A.B., M.D., Ph.D., Professor of Anatomy and Head of the Department, *University of Oklahoma, School of Medicine, Oklahoma City, Okla.*

DEMPSTER, WILFRID TAYLOR, Sc.D., Instructor in Anatomy, *University of Michigan Medical School, Ann Arbor, Mich.*

DETWILER, SAMUEL RANDALL, Ph.B., A.M., Ph.D., M.S. (Hon.), (Ex. Com. '30–'34), Professor of Anatomy, Department of Anatomy, *College of Physicians and Surgeons, Columbia University, 630 West 168th St., New York City.*

DOAN, CHARLES A., B.S., M.D., Professor and Chairman, Department of Medicine, and Director of Medical Research, *Ohio State University, Kinsman Hall, Columbus, Ohio.*

DODDS, GIDEON S., A.M., Ph.D., Professor of Histology and Embryology, *West Virginia University Medical School, Morgantown, W. Va.*

DOMM, LINCOLN V., Ph.D., Research Associate in Zoölogy, Whitman Laboratory for Experimental Zoölogy, *The University of Chicago, Chicago, Ill.*

DONALDSON, HENRY HERBERT, Ph.D., D.Sc. (Ex. Com. '09–'13, Pres. '16–'17), Member of The Wistar Institute, *The Wistar Institute of Anatomy and Biology, Woodland Ave. and 36th St., Philadelphia, Pa.*

DONALDSON, JOHN C., Ph.B., M.D., Professor of Anatomy, *School of Medicine, University of Pittsburgh, Pittsburgh, Pa.*

DOWNEY, HAL, A.M., Ph.D., Professor of Anatomy, *University of Minnesota Medical School, Minneapolis, Minn.*

DUBOIS, FRANKLIN S., A.B., M.S., M.D., Professor of Anatomy, *Department of Anatomy, University of Alabama, University, Ala.*

DUESBERG, JULES, M.D., Professor of Anatomy, *University of Liege, 22 quai Mativa, Liege, Belgium.*

DUNCAN, DONALD, A.B., A.M., Ph.D., Associate Professor of Anatomy, *University of Texas, Galveston, Tex.*

DUNN, H. L., B.A., M.A., M.B., Ph.D., M.D., Director of University Hospital and Professor of Medical Statistics, *University of Minnesota, Minneapolis, Minn.*

EARLE, WILTON R., Ph.D., Cytologist, *National Institute of Health, Washington, D. C.*

EDWARDS, J. GRAHAM, M.A., Ph.D., Assistant Professor of Anatomy, University of Buffalo School of Medicine, *24 High St., Buffalo, N. Y.*

EDWARDS, LINDEN F., B.A., M.S., Ph.D., Associate Professor of Anatomy, Ohio State University College of Medicine, *Hamilton Hall, Columbus, Ohio.*

ELLIOTT, RUSH, Ph.D., Associate Professor of Comparative Anatomy, *Ohio University, Athens, Ohio.*

ELWYN, ADOLPH, A. M., Associate Professor of Neurology, *Columbia University, 630 West 168th St., New York City.*

EMERY, FREDERICK E., Ph.D., Assistant Professor of Physiology, *University of Buffalo, Buffalo, N. Y.*

ENDERS, ROBERT K., Ph.D., Associate Professor of Zoölogy, *Swarthmore College, Swarthmore, Pa.*

ENGLE, EARL THERON, A.B., A.M., Ph.D., Associate Professor of Anatomy, *College of Physicians and Surgeons, Columbia University, 632 West 168th St., New York City.*

ESAKI, SHIRO, M.D., Ph.D., Member of Anatomical Institute, *Keio University, Sasuke 666, Kamakura, Japan.*

ESSENBERG, J. M., Ph.D., Associate Professor of Anatomy, *Loyola University School of Medicine, Chicago, Ill.*

ESSICK, CHARLES RHEIN, B.A., M.D., *439 Oley St., Reading, Pa.*

ETKIN, WILLIAM, Ph.D., Instructor in Comparative Anatomy, *College of the City of New York, New York City.*

ETTINGER, GEORGE H., M.D., C.M., Associate Professor of Physiology, *Queen's University, Kingston, Ontario, Canada.*

EVANS, HERBERT MCLEAN, B.S., M.D., M.D. honoris causa, Freiburg (Ex. Com. '19–'22; Pres. '30–'32), Hertzstein Professor of Biology, Professor of Anatomy and Director of the Institute of Experimental Biology, *University of California, Berkeley, Calif.*

EVANS, THOMAS HORACE, M.D., Associate Professor of Anatomy, Long Island College of Medicine; Research Professor of Anatomy, New York Medical College and Flower-Fifth Ave. Hospital; *350 South Main St., Freeport, N. Y.*

EVERETT, JOHN W., A.B., Ph.D., Associate in Anatomy, *Duke University School of Medicine, Durham, N. C.*

FANKHAUSER, GERHARD, Ph.D., Assistant Professor of Biology, *Princeton University, Princeton, N. J.*

FARIS, HERVEY S., A.B., A.M., Ph.D., M.D., Practicing Physician and Surgeon, *3616 Main St., Riverside, Calif.*

FERRIS, HARRY BURR, A.B., M.D., Professor of Anatomy Emeritus, Medical Department, Yale University, *395 St. Ronan St., New Haven, Conn.*

FIGGE, F. H. J., A.B., Ph.D., Associate Professor of Anatomy, *University of Maryland Medical School, Baltimore, Md.*

FISHER, CHARLES, Ph.D., Instructor in Neurology, *Institute of Neurology, Northwestern University Medical School, Chicago, Ill.*

FLEXNER, LOUIS BARKHOUSE, S.B., M.D., Associate in Anatomy, *Johns Hopkins Medical School, Baltimore, Md.*

FOLEY, JAMES OWEN, M.S., Ph.D., Associate Professor of Anatomy, *University of Alabama School of Medicine, University, Ala.*

FORMAN, JONATHAN, A.B., M.D., Lecturer on Diseases Due to Allergy in the Ohio State University, *394 East Town St., Columbus, Ohio.*

FOUST, H. L., D.V.M., Professor of Veterinary Anatomy, *Iowa State College, Ames, Iowa.*

FRASER, DORIS A., Ph.D., Fellow in Anatomy, *University of Pennsylvania School of Medicine, Philadelphia, Pa.*

FRASSETTO, FABIO, Sc.D., M.D., Director Anthropological Institute, *University of Bologna, Bologna, Italy.*

FRAZER, JOHN ERNEST, D.Sc., F.R.C.S., Professor of Anatomy, University of London, *St. Mary's Hospital Medical School, London, W., England.*

FRENCH, H. E., M.S., M.D., Professor of Anatomy and Dean of the School of Medicine, *University of North Dakota, Grand Forks, N. Dak.*

FREUDENBERGER, CLAY B., Ph.D., Professor of Anatomy, *University of Utah, Salt Lake City, Utah.*

GAGE, SIMON HENRY, B.S. (Ex. Com. '06–'11), Professor of Histology and Embryology, Emeritus, *Stimson Hall, Cornell University, Ithaca, N. Y.*

GAMBLE, DEAN L., B.S., Ph.D., President, Ward's Natural Science Establishment, *302 North Goodman St., Rochester, N. Y.*

GARCIA, ARTURO, A.B., M.D., Professor of Anatomy and Head of Department, College of Medicine, University of the Philippines, *619 Colorado St., Manila, Philippine Islands.*

GARDNER, WILLIAM U., Ph.D., Instructor in Anatomy, *Department of Anatomy, Yale University School of Medicine, 333 Cedar St., New Haven, Conn.*

GAUNT, ROBERT, Ph.D., Assistant Professor of Biology, *New York University, New York City.*

GEIST, FREDERICK D., M.D., Assistant Professor of Anatomy, *University of Wisconsin, Science Hall, Madison, Wisc.*

GEORGE, RUGGLES KERR, B.A., M.B., D.P.H., Assistant Professor of Anatomy, *University of Toronto, Toronto 5, Canada.*

GEORGE, WESLEY CRITZ, A.B., A.M., Ph.D., Professor of Histology and Embryology, *University of North Carolina Medical School, Chapel Hill, N. C.*

GERSCH, ISIDORE, B.S., Ph.D., Instructor in Anatomy, *Johns Hopkins Medical School, Baltimore, Md.*

GEY, GEORGE O., B.S., M.D., In charge of Office of Cooperative Study of Cancer, U.S.P.H.S., Assistant in Surgery, *Johns Hopkins Hospital, Baltimore, Md.*

GILBERT, MARGARET SHEA, B.A., M.A., Ph.D., Department of Zoölogy, *Oberlin College, Oberlin, Ohio.*

GLOBUS, J. H., B.S., M.D., Associate Professor of Neuro-anatomy, New York University and Bellevue Medical College, *1133 Fifth Ave., New York City.*

GODWIN, MELVIN C., B.A., Ph.D., Instructor in Anatomy, *West Virginia University, Morgantown, W. Va.*

GOLDSMITH, JOSEPH B., M.A., Ph.D., Associate Professor of Histology and Embryology, *Oklahoma University School of Medicine, Oklahoma City, Okla.*

GOODRICH, HUBERT BAKER, B.S., M.A., Ph.D., Professor of Biology, *Wesleyan University, Middletown, Conn.*

GOSS, CHARLES MAYO, A.B., M.D., Assistant Professor of Anatomy, College of Physicians and Surgeons, Columbia University, *630 West 168th St., New York City.*

GOULD, HARLEY NATHAN, A.B., A.M., Ph.D., Professor of Biology, *Newcomb College, Tulane University, New Orleans, La.*

GRAFFLIN, ALLAN L., A.B., M.D., Associate in Anatomy, *Harvard Medical School, Boston, Mass.*

GRANT, J. C. BOILEAU, M.B., Ch.B., F.R.C.S. (Edin.), Professor of Anatomy, *University of Toronto, Toronto, Canada.*

GRANT, MADELEINE P., S.B., M.A., Ph.D., Member Teaching Staff in Zoölogy, *Sarah Lawrence College, Bronxville, N. Y.*

GRAVES, WILLIAM W., M.D., Professor and Director, Department of Neuropsychiatry, *St. Louis University School of Medicine, St. Louis, Mo.*

GREENE, CHARLES W., A.M., Ph.D., Research Professor of Physiology, *University of Missouri, 814 Virginia Ave., Columbia, Mo.*

GREENE, EUNICE C., A.M., Research Investigator, *Syracuse University School of Medicine, Syracuse, N. Y.*

GREENE, WALTER FARRAR, A.B., Ph.D., Associate Professor of Anatomy, *Syracuse College of Medicine, 309 South McBride St., Syracuse, N. Y.*

GREENHILL, J. P., B.S., M.D., F.A.C.S., Professor of Gynecology, Loyola University Medical School; Professor of Gynecology, Cook County Graduate School of Medicine; Attending Gynecologist, Cook County Hospital, *Suite 2805–06 Pittsfield Building, 55 East Washington St., Chicago, Ill.*

GREEP, ROY O., M.S., Ph.D., Research Assistant, *Biological Laboratories, Harvard University, Cambridge, Mass.*

GREGORY, WILLIAM KING, A.B., A.M., Ph.D., Professor of Vertebrate Palaeontology, Columbia; Curator Departments of Comparative Anatomy and Ichthyology, Research Associate in Anthropology and Palaeontology, *American Museum of Natural History, New York City.*

GREULICH, WILLIAM W., Ph.D., Assistant Professor of Anatomy, *Yale University School of Medicine, 333 Cedar St., New Haven, Conn.*

GRODINSKY, MANUEL, B.Sc., M.D., Associate Professor of Anatomy, University of Nebraska, College of Medicine, *681 N. 58th St., Omaha, Neb.*

GUDERNATSCH, F., Ph.D., Visiting Professor, Graduate School, *New York University, Washington Square East, New York City.*

GUILD, STACY R., A.M., Ph.D., Associate Professor of Otology and Director of Otological Research Laboratory, Johns Hopkins University, *Johns Hopkins Hospital, Baltimore, Md.*

GURDJIAN, ELISHA STEPHENS, A.B., M.S., M.D., Ph.D., Neuro-Surgeon, Receiving, Grace and Providence Hospitals, *840 David Whitney Bldg., Detroit, Mich.*

GUTHRIE, MARY J., A.B., A.M., Ph.D., Associate Professor of Zoölogy, *University of Missouri, Columbia, Mo.*

GUTTMACHER, ALAN F., A.B., M.D., Associate in Obstetrics, Johns Hopkins University, *511 Cathedral St., Baltimore, Md.*

GUYER, MICHAEL F., Ph.D., LL.D., Professor of Zoölogy, *University of Wisconsin, Madison, Wis.*

HALL, BYRON E., Ph.D., M.D., *Mayo Clinic, Rochester, Minn.*

HALL, EDMUND K., D.Sc., Ph.D., Instructor in Anatomy, *University of Louisville Medical School, Louisville, Ky.*

HALL, E. RAYMOND, Ph.D., Assistant Professor of Vertebrate Zoölogy, Curator of Mammals, *California Museum of Vertebrate Zoölogy, University of California, Berkeley, Calif.*

HALPERT, BELA, M.D., Assistant Professor of Pathology, *Louisiana State University, Medical Center, New Orleans, La.*

HAM, ARTHUR W., M.D., Assistant Professor of Anatomy, *University of Toronto, Toronto, Canada.*

HAMBLEN, E. C., M.D., Associate Professor of Obstetrics and Gynecology, *Duke University School of Medicine, Durham, N. C.*

HAMBURGER, VIKTOR, Ph.D., Assistant Professor of Zoölogy, *Washington University, St. Louis, Mo.*

HAMILTON, JAMES B., Ph.D., Instructor in Physiology, *Albany Medical College, Albany, N. Y.*

HAMLETT, GEORGE W. D., A.B., A.M., Ph.D., Research Agent, *U. S. Biological Survey, Carnegie Laboratory of Embryology, Baltimore, Md.*

HANAN, ERNEST B., A.B., A.M., M.D., Associate Professor in Hygiene and Public Health; Assistant Professor in Anatomy, *University of Buffalo, Buffalo, N. Y.*

HANSON, FRANK BLAIR, A.B., A.M., Ph.D., Associate Director, *The Rockefeller Foundation, 49 West 49th St., New York City.*

HARDESTY, IRVING, A.B., Ph.D., Sc.D. (Ex. Com. '10 and '12–'15, '22–'23), Emeritus Professor of Anatomy and Head of Department of Anatomy, School of Medicine, *Tulane University, P. O. Station 20, New Orleans, La.*

HARGITT, GEORGE T., A.B., A.M., Ph.D., Professor of Zoölogy, *Biology Bldg., Duke University, Durham, N. C.*

HARRIS, HENRY A., M.A., M.D., B.S., M.R.C.P., D.Sc., Professor of Anatomy, *The Anatomy School, The University, Cambridge, England.*

HARRISON, ROSS GRANVILLE, Ph.D., M.D., Sc.D. (Pres. '12–'14), Sterling Professor of Biology and Director of Osborn Zoölogical Laboratory, *Yale University, New Haven, Conn.*

HARTMAN, CARL G., Ph.D. (Ex. Com. '29–'33), Research Associate, *Carnegie Laboratory of Embryology, Johns Hopkins Medical School, Baltimore, Md.*

HARVEY, BASIL COLEMAN HYATT, A.B., M.D., Professor of Anatomy and Dean of Students, Division of Biological Sciences, *The University of Chicago, Chicago, Ill.*

HARWELL, CHARLES W., A.B., M.D., Assistant Professor in Micro-Anatomy, *Emory University, Emory, Ga.*

HATERIUS, HANS OLIVER, A.B., M.S., Ph.D., Assistant Professor of Physiology, *Ohio State University, Columbus, Ohio.*

HATT, ROBERT T., Ph.D., Director, *Cranbrook Institute of Science, Bloomfield Hills, Mich.*

HAUSMAN, LOUIS, A.B., M.D., Associate in Neuro-anatomy, Cornell Medical School; Assistant Professor in Clinical Neurology, New York Hospital, *140 E. 54th St., New York City.*

HAZEN, CHARLES MORSE, A.M., M.D., *Professional Building, Fifth and Franklin Sts., Richmond, Va.*

HEINBECKER, PETER, M.D., Associate Professor of Surgery, *Washington University Medical School, St. Louis, Mo.*

HEISLER, JOHN C., M.D., Emeritus Professor of Anatomy, University of Pennsylvania, *3829 Walnut St., Philadelphia, Pa.*

HELDT, THOMAS J., A.B., A.M., M.D., Physician in Charge of Division of Neuropsychiatry, *Henry Ford Hospital, Detroit, Mich.*

HELFF, O. M., B.S., M.S., Ph.D., Associate Professor of Biology, *New York University, New York City.*

HELLBAUM, ARTHUR A., Ph.D., Assistant Professor of Physiology, *University of Oklahoma, Oklahoma City, Okla.*

HERRICK, CHARLES JUDSON, Ph.D. (Ex. Com. '13–'17), Emeritus Professor of Neurology, The University of Chicago, *Department of Anatomy, The University of Chicago, Chicago, Ill.*

HERTZLER, ARTHUR E., B.S., A.M., Ph.D., M.D., LL.D., F.A.C.S., Professor of Surgery, *University of Kansas, Halstead, Kansas.*

HETHERINGTON, DUNCAN CHARTERIS, A.B., M.A., Ph.D., M.D., Associate Professor of Anatomy, *Duke University Medical School, Durham, N. C.*

HEUSER, CHESTER H., A.M., Ph.D., Research Associate, Department of Embryology, Carnegie Institution, *Johns Hopkins Medical School, Baltimore, Md.*

HEWSON, ADDINELL, A.B., A.M., M.D., F.A.C.S., Emeritus Professor of Anatomy, Graduate School of Medicine, University of Pennsylvania, and Professor of Anatomy and Histology, Temple University Dental School; Emeritus Surgeon, Memorial Hospital; Secretary Anatomical Board of the State of Pennsylvania, *257 South 16th St., Philadelphia, Pa.*

HIGGINS, GEORGE M., A.M., Ph.D., Associate Professor of Experimental Biology, *University of Minnesota, Mayo Foundation, Rochester, Minn.*

HILL, JAMES PETER, D.Sc., F.R.S., Professor of Embryology, University of London, *University College, Gower St., London, W. C. 1, England.*

HILL, ROBERT T., Ph.D., Instructor in Anatomy, *Yale University School of Medicine, 333 Cedar St., New Haven, Conn.*

HILTON, WILLIAM A., B.S., Ph.D., Professor of Zoölogy, Pomona College, Director *Laguna Marine Laboratory, Claremont, Calif.*

HINES, MARION, A.B., Ph.D., Associate Professor of Anatomy, *Johns Hopkins Medical School, Baltimore, Md.*

HINSEY, JOSEPH C., M.S., Ph.D., Professor of Physiology, *Cornell University Medical College, 1300 York Ave., New York City.*

HIRSCH, G. CHRISTIAN, Ph.D., Lector, Head of Department of Experimental Histology, *Zoölogical Laboratory, The University, Utrecht, Janskerkhof 3, Holland.*

HISAW, FREDERICK L., A.B., A.M., Ph.D., Professor of Zoölogy, *Biological Laboratories, Harvard University, Cambridge, Mass.*

HOADLEY, LEIGH, A.B., Ph.D., Professor of Zoölogy, *Harvard University, Cambridge, Mass.*

HOERR, NORMAND L., B.A., Ph.D., M.D., Assistant Professor of Anatomy, *The University of Chicago, Chicago, Ill.*

Hogg, Ira D., B.A., M.A., Ph.D., Assistant Professor of Anatomy, Department of Anatomy, University of Pittsburgh School of Medicine, *617 Hampton Ave., Wilkinsburg, Pa.*

Hogue, Mary J., Ph.D., Instructor in Anatomy, *University of Pennsylvania Medical School, Philadelphia, Pa.*

Hollinshead, William H., A.B., M.S., Ph.D., Associate in Anatomy, *Duke University School of Medicine, Durham, N. C.*

Holt, Caroline M., A.B., A.M., Ph.D., Associate Professor of Biology and Public Health, Simmons College, *38 Ridge Ave., Newton Centre, Mass.*

Hooker, Davenport, M.A., Ph.D. (Ex. Com. '22–'25), Professor of Anatomy, *School of Medicine, University of Pittsburgh, Pittsburgh, Pa.*

Hopkins, Grant Sherman, Sc.D., D.V.M., Emeritus Professor of Comparative Veterinary Anatomy, *Cornell University, Ithaca, N. Y.*

Hoskins, Margaret Morris, Ph.D., Associate Professor of Microscopic Anatomy, *New York University Dental College, 209 East Twenty-third St., New York City.*

Howe, Howard A., M.D., Instructor in Anatomy, *Johns Hopkins University School of Medicine, Baltimore, Md.*

Howell, A. Brazier, Associate Professor of Anatomy, *Department of Anatomy, Johns Hopkins Medical School, Baltimore, Md.*

Howland, Ruth B., Ph.D., Associate Professor of Biology, Washington Square College, *New York University, Washington Square East, New York City.*

Hoy, Wm. E., Jr., A.B., Ph.D., Professor of Biology and Head of the Department of Biology, University of South Carolina, *2318 Wheat St., Columbia, S. C.*

Hrdlička, Aleš, M.D., Sc.D., Curator, Division of Physical Anthropology, *United States National Museum, Smithsonian Institution, Washington, D. C.*

Huber, John F., M.D., Ph.D., Associate Professor of Anatomy, *Temple University, Philadelphia, Pa.*

Hughson, Walter, S.B., M.D., Director Otological Research Laboratory, *Abington Memorial Hospital, Abington, Pa.*

Hummel, Katharine P., Ph.D., Instructor in Animal Nutrition, *Cornell University, Agricultural Experiment Station, Ithaca, N. Y.*

Humphrey, Rufus R., A.B., A.M., Ph.D., Associate Professor of Anatomy, School of Medicine, University of Buffalo, *24 High St., Buffalo, N. Y.*

Humphrey, Tryphena, M.D., Ph.D., Instructor in Anatomy, *University of Michigan Medical School, Ann Arbor, Mich.*

Hunt, Thomas E., Ph.D., Associate Professor of Histology and Embryology, *University of Alabama Medical School, University, Ala.*

Hunter, Oscar B., A.B., A.M., M.D., Assistant Dean and Professor of Pathology and Bacteriology, *1835 Eye St., N.W., Washington, D. C.*

Hunter, Richard Henry, Ph.D., M.D., M.Ch., F.Z.S., M.R.I.A., Senior Lecturer in Anatomy, *Department of Anatomy, Queen's University, Belfast, Ireland.*

Hutchinson, Cranford, Ph.D., Associate, The Wistar Institute, *Morris Biological Farm, Bristol, Pa.*

Ingalls, N. William, B.S., M.D., Associate Professor of Anatomy, School of Medicine, *Western Reserve University, 3526 Edison Road, Cleveland Heights, Ohio.*

INGERSOLL, EVERETT H., Ph.D., Associate Professor of Anatomy, *Medical College of Virginia, Richmond, Va.*

INGRAM, W. R., Ph.D., Assistant Professor of Anatomy, *Department of Anatomy, State University of Iowa, Iowa City, Iowa.*

JACKSON, CLARENCE M., M.S., M.D., LL.D. (Ex. Com. '10–'14, '23–'28, Vice-Pres. '16–'17, Pres. '22–'23), Professor and Director of the Department of Anatomy, *Institute of Anatomy, University of Minnesota, Minneapolis, Minn.*

JACKSON, JOSEPH L., M.A., M.B., Professor of Anatomy, *University of Saskatchewan, Saskatoon, Canada.*

JEFFERS, KATHERINE R., Ph.D., Research Associate in Zoölogy, *University of Missouri, Columbia, Mo.*

JENKINS, GEORGE B., M.D., Professor of Anatomy and Director of Anatomy Department, *George Washington University Medical School, Washington, D. C.*

JOB, THESLE T., A.B., M.S., Ph.D., Professor of Anatomy, *Loyola University School of Medicine, 706 South Lincoln St., Chicago, Ill.*

JOHNSON, FRANKLIN P., A.M., Ph.D., M.D., Associate Professor of Urology, University of Oregon Medical School, *310 Medical Arts Building, Portland, Ore.*

JOHNSON, SYDNEY E., Ph.D., M.D., F.A.C.P., Professor of Gross Anatomy, School of Medicine, University of Louisville, *101 West Chestnut St., Louisville, Ky.*

JOHNSTON, JOHN B., Ph.D., Sc.D. (hon.), Dean of the College of Science, Literature and the Arts, Professor of Comparative Neurology, *University of Minnesota, Minneapolis, Minn.*

JOHNSTON, THOMAS BAILLIE, M.B., Ch.B., Professor of Anatomy, University of London, *Guy's Hospital Medical School, London, S. E. 1, England.*

JOHNSTONE, PAUL N., A.B., M.D., *601 Lathrop Building, Kansas City, Mo.*

JONES, OLIVER P., Ph.D., Instructor in Anatomy, *University of Minnesota, Minneapolis, Minn.*

JORDAN, HARVEY ERNEST, A.M., Ph.D., (Ex. Com. '18–'21, First Vice-Pres. '36–), Professor of Histology and Embryology, *Department of Medicine, University of Virginia, Charlottesville, Va.*

KAAN, HELEN WARTON, Ph.D., Assistant Professor of Zoölogy, *Wellesley College, Wellesley, Mass.*

KABAT, HERMAN, Ph.D., Instructor in Physiology, *University of Minnesota, Minneapolis, Minn.*

KAMPMEIER, OTTO FREDERIC, A.B., Ph.D., M.D., Professor of Anatomy and Head of Department, *College of Medicine, University of Illinois, 1853 W. Polk St., Chicago, Ill.*

KAPPERS, CORNELIUS URBO ARIËNS, M.D., Sc.D., L.D., Director of the Central Institute for Brain Research of Holland; Professor of Comparative Neurology, University of Amsterdam, *Mauritskade 61, Amsterdam, Holland.*

KEEGAN, J. JAY, A.M., M.D., Professor of Surgery, University of Nebraska College of Medicine, *1234 Medical Arts Building, Omaha, Neb.*

KEITH, SIR ARTHUR, M.D., LL.D., F.R.C.S., D.Sc., F.R.S., Master of *Buckston Browne Research Farm, Downe, Kent, England.*

KELLOGG, REMINGTON, Ph.D., Assistant Curator of Mammals, *U. S. National Museum, Washington, D. C.*

KELLY, G. LOMBARD, A.B., B.S., M.D., Dean and Professor of Anatomy, *University of Georgia, School of Medicine, Augusta, Ga.*

KERNAN, JOHN D., JR., A.B., M.D., Associate Professor of Oto-Laryngology, Columbia College of Physicians and Surgeons, *103 East 78th St., New York City.*

KERR, ABRAM T., B.S., M.D., (Ex. Com. '10–'14), Professor of Anatomy and Secretary of Cornell University Medical College, *Cornell University Medical College, Ithaca, N. Y.*

KEY, J. ALBERT, B.S., M.D., Clinical Professor of Orthopedic Surgery, *Washington University, St. Louis, Mo.*

KINDRED, JAMES ERNEST, A.B., A.M., Ph.D., Associate Professor of Histology and Embryology, *University of Virginia Medical School, University, Va.*

KING, HELEN DEAN, A.M., Ph.D., Member of The Wistar Institute (Experimental Zoölogy), *The Wistar Institute of Anatomy, 36th St. and Woodland Ave., Philadelphia, Pa.*

KING, JESSIE L., Ph.D., Professor of Physiology, *Goucher College, Baltimore, Md.*

KINGERY, HUGH MCMILLAN, A.B., A.M., Ph.D., Associate Professor of Anatomy, *School of Medicine, University of Colorado, Denver, Colo.*

KINGSBURY, BENJAMIN F., A.B., Ph.D., M.D., D.Sc. (Ex. Com. '22–'25, Vice-Pres. '32–'34), Professor of Histology and Embryology, Cornell University, *2 South Ave., Ithaca, N. Y.*

KINGSLEY, D. M., M.S., Ph.D., M.D., Assistant Professor of Anatomy, *Louisiana State University, Medical Center, New Orleans, La.*

KIRKHAM, WILLIAM BARRI, Ph.D., Consulting Director, Museum of Natural History, *220 State St., Springfield, Mass.*

KIRSCHBAUM, ARTHUR, Ph.D., Fellow in Anatomy, *University of Minnesota, Minneapolis, Minn.*

KNOUFF, R. A., B.A., M.A., Ph.D., Professor of Anatomy, *Department of Anatomy, Ohio State University, Columbus, Ohio.*

KNOWER, HENRY MCE., A.B., Ph.D. (Johns Hopkins), (Ex. Com. '11–'15, '24–'26), Research Associate in Biology, *Osborn Zoölogical Laboratory, Yale University, New Haven, Conn.*

KOCH, JOHN C., B.S., M.D., *265 Euclid Ave., East, Detroit, Mich.*

KOFOID, CHARLES ATWOOD, A.B., Ph.D., Sc.D., Professor of Zoölogy Emeritus, *Room 5090, Life Sciences Bldg., University of California, Berkeley, Calif.*

KORNHAUSER, S. I., M.A., Ph.D., Professor of Anatomy and Executive Secretary, *University of Louisville, School of Medicine, 101 W. Chestnut St., Louisville, Ky.*

KRAFKA, JOSEPH, JR., Ph.D., M.D., Professor of Microscopic Anatomy, Medical Department, *University of Georgia, Augusta, Ga.*

KRAUSE, ALLEN KRAMER, A.B., A.M., M.D., Litt.D., Editor, American Review of Tuberculosis, *615 North Wolfe St., Baltimore, Md.*

KREHBIEL, ROBERT H., M.S., Ph.D., Instructor in Anatomy, *University of Illinois, College of Medicine, 1853 W. Polk St., Chicago, Ill.*

KRIEG, WENDELL J. S., Ph.D., Instructor in Anatomy, *New York University, College of Medicine, New York City.*

KROGMAN, WILTON M., Ph.D., Associate Professor of Anatomy and Physical Anthropology, *School of Medicine, Western Reserve University, Cleveland, Ohio.*

Kropp, Benjamin, Ph.D., Research Fellow in Anatomy, *Harvard Medical School, Boston, Mass.*

Kudo, Tokuyasu, M.D., Professor of Anatomy and Histology, *Niigata Medical College, Niigata City, Echigo, Japan.*

Kuhlenbeck, Hartwig, M.D., Acting Professor of Anatomy, *Woman's Medical College of Pennsylvania, Philadelphia, Pa.*

Kunkel, Beverly Waugh, Ph.B., Ph.D., Professor of Biology, *Lafayette College, Easton, Pa.*

Kuntz, Albert, Ph.D., M.D., Professor of Micro-anatomy, *St. Louis University Medical School, 1402 South Grand Ave., St. Louis, Mo.*

Kutchin, Mrs. Harriet Lehmann, A.M., *"The Maplewood," Green Lake, Wis.*

Lachmann, Ernst, M.D., Assistant Professor of Anatomy, *University of Oklahoma School of Medicine, Oklahoma City, Okla.*

Lambert, Avery Eldorus, B.S., Ph.D., Professor of Histology, State University of Iowa Medical School, *Room 360, Medical Laboratories Bldg., Iowa City, Iowa.*

Langworthy, Orthello R., A.B., A.M., M.D., Associate Professor of Neurology, Johns Hopkins University, *Johns Hopkins Hospital, Baltimore, Md.*

Larsell, Olof, A.M., Ph.D., Professor of Anatomy, *University of Oregon Medical School, Portland, Oregon.*

Lassek, Arthur M., B.S., M.S., Ph.D., M.D., Professor of Anatomy, *Medical College of the State of South Carolina, Charleston, S. C.*

Latimer, Homer B., A.M., Ph.D., Professor of Anatomy, *Medical School, University of Kansas, Lawrence, Kansas.*

Latta, John S., A.B., Ph.D., Professor of Anatomy, University of Nebraska, College of Medicine, *Forty-second St. and Dewey Ave., Omaha, Neb.*

Lawless, John J., M.A., Ph.D., Assistant Professor of Anatomy, *West Virginia University School of Medicine, Morgantown, W. Va.*

Leblond, C. P., M.D., Assistant in Histology, *University of Paris, Paris, France.*

Leche, Stella M., B.S., M.S., Ph.D., Assistant Professor of Anatomy, *Tulane University School of Medicine, New Orleans, La.*

Lee, Ferdinand Christian, A.B., M.D., Associate Professor of Surgery, *Johns Hopkins Hospital, Baltimore, Md.*

Leonard, Samuel, Ph.D., Assistant Professor of Biology, *Union College, Schenectady, N. Y.*

Levi, Giuseppe, M.D., Professor of Anatomy, *University of Torino, Istituto anatomico, Corso d'Azeglio 52, Torino, Italy.*

Lewis, Dean D., M.D., Sc.D., LL.D., Professor of Surgery, Johns Hopkins University, *Johns Hopkins Hospital, Baltimore, Md.*

Lewis, Frederic T., A.M., M.D. (Ex. Com. '09–'13, Vice-Pres. '14–'16; Pres. '36–), Professor of Comparative Anatomy, *Harvard Medical School, Boston, Mass.*

Lewis, Margaret Reed, M.A., Research Associate, Department of Embryology, Carnegie Institution of Washington, *Johns Hopkins Medical School, Baltimore, Md.*

Lewis, Warren Harmon, B.S., M.D., (Ex. Com. '09–'11, '14–'17, Pres. '34–'36), Research Associate, Department of Embryology, Carnegie Institution of Washington, Professor of Physiological Anatomy, *Johns Hopkins Medical School, Baltimore, Md.*

LILLIE, FRANK RATTRAY, Ph.D., Sc.D., Andrew MacLeish Distinguished Service Professor of Embryology, Department of Zoölogy (Emeritus), The University of Chicago; President of Marine Biological Laboratory, Woods Hole, Mass.; President, National Academy of Sciences, *The University of Chicago, Chicago, Ill.*

LINEBACK, PAUL EUGENE, A.M., M.D., Professor of Micro-anatomy, *Emory Medical School, Emory University, Ga.*

LINELL, ERIC AMBROSE, Ch.B., M.D., Professor of Neuropathology, *Banting Institute, University of Toronto, Canada.*

LIPSCHUTZ, BENJAMIN, M.D., Assistant Professor in Neuro-anatomy, Jefferson Medical College, *1007 Spruce St., Philadelphia, Pa.*

LITTLE, CLARENCE COOK, B.A., M.S., Sc.D., LL.D., Litt.D., *Jackson Memorial Laboratory, Bar Harbor, Me.*

LORD, FREDERIC P., A.B., M.D., Professor of Anatomy, *Dartmouth Medical School, 39 College St., Hanover, N. H.*

LORENTE DE NÓ, RAPHAEL, M.D., Neuroanatomist, *Central Institute for the Deaf, 818 S. Kingshighway, St. Louis, Mo.*

LOTH, EDWARD, M.D., Ph.D., Professor of Anatomy and Director of Anatomical Institute, University of Warsaw, *5 Chalubinski Str., Warsaw, Poland.*

LOWREY, LAWSON GENTRY, A.M., M.D., Director, Institute for Child Guidance, *28 West 54th St., New York City.*

LUCAS, ALFRED M., Ph.D., Associate Professor of Zoölogy, *Iowa State College, Ames, Iowa.*

LUCAS, MIRIAM SCOTT, Ph.D., *Department of Zoölogy, Iowa State College, Ames, Iowa.*

LYONS, WILLIAM R., Ph.D., Instructor in Anatomy, *University of California, Berkeley, Calif.*

MACCALLUM, DANIEL BARTLETT, S.B., Ph.D., M.D., Associate Professor of Anatomy, *University of Southern California Medical School, Los Angeles, Calif.*

MACEWEN, EWEN, B.S., M.S., M.D., Professor of Anatomy, Director of the Anatomical Laboratories, Dean, College of Medicine, *University of Iowa, Iowa City, Iowa.*

MACFALL, CLAUDE M., Ph.D., Head of the Department, and Professor of Anatomy, *University of South Dakota Medical School, Vermillion, S. D.*

MACFARLAND, FRANK MACE, A.M., Ph.D., Emeritus Professor of Histology, Leland Stanford Junior University; President and Acting Director California Academy of Sciences, San Francisco; *775 Santa Ynez St., Stanford University, Calif.*

MCCLENDON, JESSE F., Ph.D., Professor of Physiological Chemistry, University of Minnesota, *212 Millard Hall, University of Minnesota, Minneapolis, Minn.*

MCCLUNG, CLARENCE E., Ph.G., A.B., A.M., Ph.D., Professor of Zoölogy and Director of the Zoölogical Laboratory, *University of Pennsylvania, Philadelphia, Pa.*

MCCLURE, CHARLES FREEMAN WILLIAMS, A.M., Sc.D. (Vice-Pres. '10–'11, Ex. Com. '12–'16, Pres. '20–'21), Professor Emeritus of Comparative Anatomy, *Princeton University, Princeton, N. J.*

McCotter, Rollo E., M.D., Professor of Anatomy, Medical School, University of Michigan, *Lakewood R. R. 1, Ann Arbor, Mich.*

McCrady, Edward, Jr., Ph.D., Associate, *The Wistar Institute of Anatomy and Biology, 36th St. and Woodland Ave., Philadelphia, Pa.*

McGill, Caroline, A.B., A.M., Ph.D., M.D., Physician, *58 W. Quartz, Butte, Mont.*

McKenzie, Fred F., A.M., Ph.D., Assistant Professor of Animal Husbandry, *University of Missouri, Columbia, Mo.*

McKibben, Paul S., Ph.D., Sc.D., LL.D. (Ex. Com. '31–'35), Professor of Anatomy, *University of Southern California, Los Angeles, Calif.*

McKinney, Roscoe L., Ph.D., Professor of Anatomy, *Howard University, Washington, D. C.*

McMurrich, James Playfair, A.M., Ph.D., LL.D. (Ex. Com. '06–'07, '17–'20, Pres. '08–'09), Professor Emeritus of Anatomy, *University of Toronto, Toronto, Canada.*

McNutt, G. W., D.V.M., West Seattle Animal Hospital, *4729 42nd Ave., S.W., Seattle, Wash.*

Macklin, C. C., M.B., M.D., M.A., Ph.D., F.R.S.C. (Ex. Com. '28–'32), Professor of Histology and Embryology, *University of Western Ontario Medical School, London, Ontario, Canada.*

Maclean, Bernice L., A.B., Ph.D., Instructor in Zoölogy, Department of Biological Sciences, *Hunter College, 2 Park Ave., New York City.*

Magath, Thomas Byrd, M.S., Ph.D., M.D., Consulting Physician, Clinical Laboratories, Mayo Clinic, and Professor of Pathology and Parasitology, University of Minnesota, *Mayo Clinic, Rochester, Minn.*

Magoun, H. W., Ph.D., Associate in Neurology, *Institute of Neurology, Northwestern University Medical School, Chicago, Ill.*

Mainland, Donald, M.B., Ch.B., D.Sc., *Department of Anatomy, Dalhousie University, Halifax, Nova Scotia, Canada.*

Malone, Edward F., A.B., M.D. (Ex. Com. '31–'35), Francis Brunning Professor of Anatomy, *University of Cincinnati, College of Medicine, Eden Ave., Cincinnati, Ohio.*

Mangum, Charles S., A.B., M.D., Professor of Anatomy, University of North Carolina, *510 East Franklin St., Chapel Hill, N. C.*

Mark, Edward Laurens, Ph.D., LL.D., Hersey Professor of Anatomy (Emeritus), Harvard University, and Trustee of the Bermuda Biological Station for Research, Inc., *109 Irving St., Cambridge, Mass.*

Markee, J. E., Ph.D., Assistant Professor of Anatomy, *Stanford University, Stanford, Calif.*

Marshall, Clyde, M.D., Assistant Professor in Anatomy, Yale University School of Medicine, *333 Cedar St., New Haven, Conn.*

Martin, Cecil P., A.B., M.B., D.Sc., Professor of Anatomy, *McGill University, Montreal, Canada.*

Mason, Karl E., Ph.D., Associate Professor of Anatomy, *Vanderbilt University Medical School, Nashville, Tenn.*

Mastin, Edward V., M.S., M.D., Instructor in Surgery, *St. Louis University Medical School, St. Louis, Mo.*

Matas, Rudolph, M.D., LL.D., Sc.D., F.R.C.S. Eng. (hon.), Professor of Surgery (1894–1927), Emeritus (1927–), and Demonstrator of Anatomy (1885–1894), Tulane University, *2255 St. Charles Ave., New Orleans, La.*

MATTHEWS, SAMUEL A., M.A., Ph.D., Associate in Anatomy, *University of Pennsylvania, School of Medicine, Philadelphia, Pa.*

MAVOR, JAMES WATT, B.A., M.A., Ph.D., Professor of Biology, *Union College, Schenectady, N. Y.*

MEAD, HAROLD TUPPER, B.A., M.S., Ph.D., Professor of Biology, *Limestone College, Gaffney, S. C.*

MEADER, RALPH G., Ph.D., Instructor in Anatomy, Yale University School of Medicine, *333 Cedar St., New Haven, Conn.*

MEAKER, SAMUEL R., A.B., M.D., M.R.C.S. (Eng.), F.A.C.S., F.C.O.G., Professor of Gynaecology, Boston University School of Medicine, *475 Commonwealth Ave., Boston, Mass.*

MENDELSOHN, WILLIAM, M.S., M.D., Fellow in Medicine, *Johns Hopkins Hospital, Baltimore, Md.*

METTLER, FRED A., A.B., A.M., Ph.D., Associate Professor of Anatomy, *University of Georgia Medical School, Augusta, Ga.*

MEYER, ADOLF, M.D., LL.D., Professor of Psychiatry and Director of the Henry Phipps Psychiatric Clinic, *Johns Hopkins Hospital, Baltimore, Md.*

MEYER, ARTHUR W., S.B., M.D. (Ex. Com. '12–'16, Vice-Pres. '24–'25), Professor of Anatomy, Leland Stanford Junior University, *121 Waverly St., Palo Alto, Calif.*

MEYER, ROLAND K., A.B., Ph.D., Assistant Professor of Zoölogy, *Department of Zoölogy, University of Wisconsin, Madison, Wis.*

MICHELS, NICHOLAS A., M.A., D.Sc., Associate Professor of Anatomy, *The Daniel Baugh Institute of Anatomy, Jefferson Medical College, Philadelphia, Pa.*

MIDLO, CHARLES, M.D., Assistant Professor of Anatomy, *Louisiana State University, Medical Center, New Orleans, La.*

MILLER, RUTH ALEXANDRIA, A.B., Ph.D., Instructor in Anatomy, College of Physicians and Surgeons, Columbia University, *630 W. 168th St., New York City.*

MILLER, SHIRLEY P., A.B., A.M., Ph.D., Assistant Professor of Anatomy, *Anatomical Institute, University of Minnesota, Minneapolis, Minn.*

MILLER, WILLIAM SNOW, M.D., Sc.D. (Vice-Pres. '08–'09), Professor of Anatomy (Emeritus), University of Wisconsin, *2001 Jefferson St., Madison, Wis.*

MOODY, ROBERT ORTON, B.S., M.D., Emeritus Professor of Anatomy, University of California, *2826 Garber St., Berkeley, Calif.*

MOORE, CARL R., A.M., Ph.D., Professor of Zoölogy, *Hull Zoölogical Laboratory, The University of Chicago, Chicago, Ill.*

MORGAN, LAWRENCE ONIS, A.B., A.M., Ph.D., Associate Professor of Anatomy, *University of Cincinnati, College of Medicine, Eden Ave., Cincinnati, Ohio.*

MORRILL, CHARLES V., A.M., Ph.D., Associate Professor of Anatomy, *Cornell University Medical College, 1300 York Ave., New York City.*

MORTENSEN, OTTO A., B.S., M.D., Assistant Professor of Anatomy, *University of Wisconsin, Madison, Wis.*

MORTON, DUDLEY JOY, M.D., Associate Professor, Department of Anatomy, *College of Physicians and Surgeons, Columbia University, 630 West 168th St., New York City.*

MOSSMAN, HARLAND W., Ph.D., Assistant Professor of Anatomy, *Science Hall, University of Wisconsin, Madison, Wis.*

Mull, Philip L., B.S., M.D., Dean, Professor of Anatomy, *University of Mississippi Medical School, University, Miss.*

Myers, Burton D., A.M., M.D., Professor of Anatomy and Dean of the Indiana University School of Medicine, *424 N. Walnut St., Bloomington, Ind.*

Myers, J. Arthur, M.S., Ph.D., M.D., Professor of Preventive Medicine and Chief of Chest Clinic, *University of Minnesota Medical School, Minneapolis, Minn.*

Nachtrieb, Henry Francis, B.S., Professor Emeritus, Animal Biology, University of Minnesota, *2448 Cedar St., Berkeley, Calif.*

Nañagas, Juan Cancio, M.D., Professor of Anatomy, College of Medicine, University of the Philippines, *719 Florida St., Manila, Philippine Islands.*

Neal, Herbert Vincent, A.M., Ph.D., Sc.D., Professor of Zoölogy, Tufts College, *Tufts College, 57, Mass.*

Nelson, Warren O., A.B., Sc.M., Ph.D., Professor and Head of the Department of Anatomy, *Wayne University, School of Medicine, 1512 St. Antoine St., Detroit, Mich.*

Nicholas, John Spangler, M.S., Ph.D., Bronson Professor of Comparative Anatomy, *Osborn Zoölogical Laboratory, Yale University, New Haven, Conn.*

Noback, Gustave J., B.S., M.A., Ph.D., Professor of Anatomy, New York University, *477 First Ave., New York City.*

Noble, Gladwyn K., A.B., M.A., Ph.D., Curator, Departments of Herpetology and Experimental Biology, *American Museum of Natural History, 77th St. and Central Park West, New York City.*

Nonidez, José F., M.S., Sc.D., Assistant Professor of Anatomy, Cornell University Medical College, *1300 York Ave., New York City.*

Norris, H. W., A.B., Sc.D., Research Professor of Zoölogy, *Grinnell College, Grinnell, Iowa.*

Obenchain, Jeanette B., Ph.D., Research Associate, Department of Anatomy, *The University of Chicago, Chicago, Ill.*

O'Donoghue, Charles H., D.Sc., F.Z.S., F.R.S.E., Reader, *Department of Zoölogy, University of Edinburgh, Scotland.*

O'Leary, James L., Ph.D., M.D., Assistant Professor of Cytology, *Washington University School of Medicine, St. Louis, Mo.*

Osterud, Hjalmar L., A.B., A.M., Ph.D., Professor of Anatomy, *Medical College of Virginia, Richmond, Va.*

Overholser, Milton D., A.B., A.M., Ph.D., M.D., Professor of Anatomy, and Chairman of Department, *University of Missouri, Columbia, Mo.*

Paff, George H., Ph.D., Assistant Professor of Anatomy, *Long Island College of Medicine, 350 Henry St., Brooklyn, N. Y.*

Painter, Theophilus S., Ph.D., Professor of Zoölogy, Department of Zoölogy, *University of Texas, Austin, Texas.*

Palmer, Carroll E., M.A., Ph.D., M.D., Medical Officer in Charge, Office of Child Hygiene, *U. S. Public Health Service, Washington, D. C.*

Palmer, Dwight M., B.Sc. M.Sc., M.D., Assistant Professor of Anatomy, *Ohio State University, Columbus, Ohio.*

Pankratz, David S., A.B., A.M., Ph.D., Assistant Professor of Anatomy, *University of Tennessee, Memphis, Tenn.*

Papanicolaou, George N., Ph.D., M.D., Assistant Professor of Anatomy, *Cornell University Medical College, 1300 York Ave., New York City.*

PAPEZ, JAMES WENCESLAS, B.A., M.D., Assistant Professor of Anatomy and Neurology, *Cornell University Medical College, Ithaca, N. Y.*

PARKER, ALICE E., Ph.D., Fellow in Anatomy, *University of Colorado School of Medicine, Denver, Colo.*

PARKER, GEORGE HOWARD, D.Sc., Professor of Zoölogy, Emeritus, *Harvard University, 16 Berkeley St., Cambridge, Mass.*

PARKER, RAYMOND C., B.A., Ph.D., Associate of the Rockefeller Institute, *66th St. and York Ave., New York City.*

PARKES, A. S., D.Sc., Member, *National Institute for Medical Research, Hampstead, London, N.W. 3, England.*

PATTEN, BRADLEY MERRILL, A.M., Ph.D. (Second Vice-Pres. '34–'36), Professor of Anatomy, *University of Michigan, Ann Arbor, Mich.*

PATTERSON, JOHN THOMAS, B.S., Ph.D., Professor of Zoölogy, University of Texas, *1908 Cliff St., Austin, Texas.*

PEARSON, ANTHONY A., M.A., Ph.D., Instructor in Anatomy, *The University of Chicago, Chicago, Ill.*

PENCHARZ, RICHARD I., Ph.D., Research Associate, *Institute of Experimental Biology, University of California, Berkeley, Calif.*

PERKINS, ORMAN C., A.B., A.M., M.D., F.A.C.P., Professor of Neurology, Long Island College of Medicine, *829 Carroll St., Brooklyn, N. Y.*

PIERSOL, WILLIAM HUNTER, B.A., M.B., Professor of Histology and Embryology, University of Toronto, *35 Dunvegan Road, Toronto, Canada.*

POHLMAN, AUGUSTUS G., M.D. (Ex. Com. '32–'36), Professor of Anatomy, *Creighton University, Omaha, Neb.*

POLYAK, STEPHEN, M.D., Associate Professor of Neurology, Department of Medicine, *The University of Chicago, Chicago, Ill.*

POTTER, PETER, M.S., M.D., Oculist and Aurist, *Motor Clinic Bldg., Butte, Montana.*

POYNTER, CHARLES W. M., B.S., M.D. (Ex. Com. '19–'22), Professor of Anatomy, and Dean of the College of Medicine, University of Nebraska, *Forty-second and Dewey Ave., Omaha, Neb.*

PRATT, JEAN PAUL, M.D., Surgeon in Charge of Division of Gynecology and Obstetrics, *Henry Ford Hospital, Detroit, Mich.*

PRYOR, JOSEPH WILLIAM, M.D., Emeritus Professor of Anatomy and Physiology, University of Kentucky, *417 West Second St., Lexington, Ky.*

PUCKETT, WILLIAM O., M.A., Ph.D., Instructor in Biology, *Princeton University, Princeton, N. J.*

QUIRING, D. P., M.A., Ph.D., Instructor in Biology, *Western Reserve University, Cleveland, Ohio.*

RADASCH, HENRY E., M.S., M.D., Professor of Histology and Embryology, Jefferson Medical College, *Daniel Baugh Institute of Anatomy, Eleventh and Clinton Sts., Philadelphia, Pa.*

RAMSAY, ANDREW J., Ph.D., Associate in Histology and Embryology, *Jefferson Medical College, Philadelphia, Pa.*

RANSON, STEPHEN W., M.D., Ph.D. (Ex. Com. '21–'24, Vice-Pres. '26–'28), Professor and Director of Neurological Institute, Northwestern University Medical School, *303 East Chicago Ave., Chicago, Ill.*

RASMUSSEN, ANDREW T., Ph.D. (Ex. Com. '34–), Professor of Neurology, *Institute of Anatomy, University of Minnesota, Minneapolis, Minn.*

Raven, Henry C., Associate Curator, Department of Comparative and Human Anatomy, *American Museum of Natural History, 77th St. and Central Park West, New York City.*

Rawlinson, Herbert E., M.B., M.D., M.Sc., Ph.D., Assistant Professor of Histology and Embryology, *McGill University, Montreal, Canada.*

Reagan, Franklin P., Ph.D., Associate Professor of Anatomy, Medical School, University of Illinois, *1853 West Polk St., Chicago, Ill.*

Reed, Hugh D., B.S., Ph.D., Professor of Zoölogy, Cornell University, *McGraw Hall, Ithaca, N. Y.*

de Rényi, George St., M.D., Associate Professor of Anatomy, University of Pennsylvania, School of Medicine, *212 S. 39th St., Philadelphia, Pa.*

Revell, Daniel Graisberry, A.B., M.B., Professor of Anatomy, *University of Alberta, Edmonton, Alberta, Canada.*

Reynolds, Samuel R. M., M.A., Ph.D., Assistant Professor of Physiology, *Long Island College of Medicine, 350 Henry St., Brooklyn, N. Y.*

Rhinehart, D. A., A.M., M.D., Professor of Applied Anatomy, University of Arkansas, *4 Armistead Rd., Little Rock, Ark.*

Rice, Edward Loranus, A.B., Ph.D., Sc.D., Professor of Zoölogy, *Ohio Wesleyan University, Delaware, Ohio.*

Rienhoff, William F., Jr., A.B., M.D., Associate Professor of Surgery, Johns Hopkins Hospital, *1201 North Calvert St., Baltimore, Md.*

Ringoen, Adolph R., A.M., Ph.D., Associate Professor of Zoölogy, *Department of Zoölogy, University of Minnesota, Minneapolis, Minn.*

Rioch, David McK., A.B., M.D., Assistant Professor of Anatomy, *Harvard Medical School, Boston, Mass.*

Robertson, W. R. B., A.B., A.M., Ph.D., Associate in Anatomy, *University of Iowa, Iowa City, Ia.*

Robinson, Byron L., M.A., M.D., Professor of Anatomy, *University of Arkansas Medical School, Little Rock, Ark.*

Rogers, James B., A.M., M.D., Associate Professor of Anatomy, *University of Louisville, School of Medicine, Louisville, Kentucky.*

Rogers, William Mitchell, B.S., Ph.D., Assistant Professor of Anatomy, *College of Physicians and Surgeons, Columbia University, 630 West 168th St., New York City.*

Romer, Alfred S., B.A., Ph.D., Professor of Zoölogy and Curator of Vertebrate Paleontology, *Biological Laboratories, Harvard University, Cambridge, Mass.*

Roofe, Paul Gibbons, B.S., Ph.D., Instructor in Anatomy, Department of Anatomy, *University of Louisville, School of Medicine, Louisville, Ky.*

Rubinstein, Hyman S., M.D., Ph.D., Associate in Neuro-endocrine Research, *Surgical Division, Sinai Hospital, Baltimore, Md.*

Rudnick, Dorothea, Ph.B., Ph.D., Fellow in Zoölogy, *University of Rochester, Rochester, N. Y.*

Rugh, Roberts, B.A., M.A., Ph.D., Instructor in Zoölogy, *Hunter College, 2 Park Ave., New York City.*

Ruth, Edward S., M.D., F.A.C.S., *1680 North Vine St., Hollywood, Calif.*

Ruth, Elbert B., A.B., A.M., Ph.D., Assistant Professor of Anatomy, *University of Rochester, Crittenden Boulevard, Rochester, N. Y.*

SABIN, FLORENCE R., B.S., M.D., Sc.D., LL.D. (Second Vice-Pres. '08–'09, Pres. '24–'26), Member of Rockefeller Institute, *Rockefeller Institute for Medical Research, 66th St. and York Ave., New York City.*

SANDSTROM, CARL J., Ph.D., Assistant Professor of Biology, *New York University, New York City.*

SANTEE, HARRIS E., A.M., Ph.D., M.D., Neurologist, *R.F.D. No. 2, Box 29, West Chicago, Ill.*

SCAMMON, RICHARD E., Ph.D., LL.D. (Ex. Com. '23–'26, '35–, Vice-Pres. '28–'30), Distinguished Service Professor of the Graduate Faculty, *University of Minnesota, Minneapolis, Minn.*

SCHAEFFER, JACOB PARSONS, A.M., M.D., Ph.D., Sc.D. (Ex. Com. '24–'29), Professor of Anatomy and Director of the Daniel Baugh Institute of Anatomy, Jefferson Medical College, *4634 Spruce St., Philadelphia, Pa.*

SCHMIDT, IDA GENTHER, B.A., M.A., Ph.D., Assistant Professor in Anatomy, *University of Cincinnati, College of Medicine, Eden Ave., Cincinnati, Ohio.*

SCHOCHET, SYDNEY S., M.D., Surgeon, *55 East Washington St., Chicago, Ill.*

SCHOEMAKER, DANIEL M., B.S., M.D., Professor of Anatomy, School of Medicine, St. Louis University, *1402 S. Grand Ave., St. Louis, Mo.*

SCHOUR, ISAAC, B.S., D.D.S., M.S., Ph.D., Professor of Histology, University of Illinois College of Dentistry, *1838 W. Harrison St., Chicago, Ill.*

SCHULTZ, ADOLPH H., Ph.D., Associate Professor of Physical Anthropology, Department of Anatomy, *Johns Hopkins Medical School, Baltimore, Md.*

SCHWARTZ, HENRY G., M.D., Fellow in Neurological Surgery, Washington University Medical School, *Barnes Hospital, St. Louis, Mo.*

SCHWIND, JOSEPH L., A.B., A.M., Ph.D., Assistant Professor of Anatomy, *Albany Medical College, Albany, N. Y.*

SCOTT, GORDON H., Ph.D., Associate Professor of Cytology, *Washington University School of Medicine, St. Louis, Mo.*

SCOTT, JOHN W., A.B., A.M., Ph.D., Professor of Zoölogy and Director of Pre-Medical Curriculum, *University of Wyoming, Laramie, Wyoming.*

SEDWICK, H. JOBE, D.D.S., Associate in Pediatrics, University of Rochester, *School of Medicine and Dentistry, Rochester, N. Y.*

SEIB, GEORGE A., A.B., M.D., Assistant Professor of Anatomy, Washington University, *2323 Lafayette Ave., St. Louis, Mo.*

SELLING, LAURENCE, A.B., M.D., Clinical Professor of Medicine and Head of Department of Medicine, University of Oregon Medical School, *Mayer Building, Portland, Ore.*

SENIOR, H. D., M.D., D.Sc., F.R.C.S. (Vice-Pres. '22–'23, Ex. Com. '33–'37), Professor Emeritus of Anatomy, College of Medicine, New York University, *Salisbury Cove, Maine.*

SEVERINGHAUS, AURA E., B.S., M.A., Ph.D., Assistant Professor of Anatomy, *College of Physicians and Surgeons, Columbia University, New York City.*

SHANER, RALPH FAUST, Ph.D., Professor of Anatomy, *University of Alberta, Edmonton, Alberta, Canada.*

SHARP, CLAYTON, M.D., Assistant Professor of Anatomy, *Long Island College of Medicine, 350 Henry St., Brooklyn, N. Y.*

SHEARER, EDWIN M., Ph.D., Assistant Professor of Anatomy, New York University and Bellevue Hospital Medical College, *477 First Ave., New York City.*

SHEININ, JOHN J., B.S., M.S., Ph.D., M.B., Dean and Chairman Department of Anatomy, *Chicago Medical School, 710 South Lincoln St., Chicago, Ill.*

SHIELDS, RANDOLPH TUCKER, A.B., M.D., Associate Dean and Professor of Histology and Embryology, School of Medicine, *Shantung Christian University, Tsinan, Shantung, China.*

SHUMWAY, WALDO, A.B., A.M., Ph.D., Professor of Zoölogy, *University of Illinois, Urbana, Ill.*

SIMER, PARKE H., Ph.D., Assistant Professor of Anatomy, *University of Illinois, 1853 W. Polk St., Chicago, Ill.*

SIMKINS, CLEVELAND S., A.B., Ph.D., Associate Professor of Anatomy and Embryology, University of Tennessee Medical School, *875 Monroe Ave., Memphis, Tenn.*

SIMPSON, MIRIAM ELIZABETH, A.B., M.A., Ph.D., M.D., Associate Professor of Anatomy, *University of California, Berkeley, Calif.*

SINGER, EDWARD, M.D., Associate Director, St. Clare's Hospital, *1175 Park Ave., New York City.*

SMITH, BERTRAM GARNER, A.B., Ph.D., Professor of Anatomy, College of Medicine, New York University, *477 First Ave., New York City.*

SMITH, CARL G., M.D., Ph.D., Lecturer in Anatomy, *University of Toronto, Toronto 5, Canada.*

SMITH, CHRISTIANNA, A.M., Ph.D., Professor of Zoölogy, *Mount Holyoke College, South Hadley, Mass.*

SMITH, DAVID T., A.B., M.D., Associate Professor of Medicine and Professor of Bacteriology, Duke University, *Duke Hospital, Durham, N. C.*

SMITH, GEORGE MILTON, A.B., M.D., Research Associate in Anatomy, Yale University School of Medicine, *Pine Orchard, Conn.*

SMITH, PHILIP EDWARD, M.S., Ph.D. (Ex. Com. '34–), Professor of Anatomy, College of Physicians and Surgeons, Columbia University, *632 West 168th St., New York City.*

SMITH, WILBUR CLEVELAND, M.D., Head of the Department of Gross Anatomy, *Tulane University, New Orleans, La.*

SMITH, WILBUR K., A.B., M.D., Associate Professor of Anatomy, *University of Rochester School of Medicine and Dentistry, Rochester, N. Y.*

SNODGRASS, L. E., M.D., Instructor in Surgery, *University of Pennsylvania School of Medicine, Philadelphia, Pa.*

SNYDER, FRANKLIN FAUST, M.D., Associate Professor, Department of Obstetrics, *Johns Hopkins Hospital, Baltimore, Md.*

SPAULDING, M. H., A.B., A.M., Professor of Zoölogy, University of Montana, *122 North Bozeman Ave., Bozeman, Montana.*

SPECTOR, BENJAMIN, M.D., Professor of Anatomy, *Tufts College Medical School, 416 Huntington Ave., Boston, Mass.*

SPEIDEL, CARL C., Ph.B., Ph.D., Professor of Anatomy, University of Virginia Medical School, *University, Va.*

STARK, MARY B., Ph.B., M.A., Ph.D., Professor of Histology and Embryology, New York Homeopathic Medical College and Flower Hospital, *450 East Sixty-fourth St., New York City.*

STEIN, KATHRYN F., M.A., Ph.D., Assistant Professor of Zoölogy, *Mount Holyoke College, South Hadley, Mass.*

STEVENSON, PAUL HUSTON, B.S., M.A., M.D., Associate Professor of Anatomy, *Peiping Union Medical College, Peiping, China.*

STILES, HENRY WILSON, M.D., Professor of Anatomy, College of Medicine, Syracuse University, *309 S. McBride St., Syracuse, N. Y.*

STOCKARD, CHARLES RUPERT, B.S., M.S., M.D., Ph.D., Sc.D. (Sec.-Treas. '14–'21, Ex. Com. '23–'28, Pres. '28–'30), Professor of Anatomy, Cornell University Medical College, *1300 York Ave., New York City.*

STONE, LEON STANSFIELD, Ph.B., Ph.D., Associate Professor of Anatomy, Yale School of Medicine, *Sterling Hall of Medicine, Anatomy Department, Cedar St., New Haven, Conn.*

STONE, ROBERT S., B.A., M.A., M.B., M.D., Associate Professor of Roentgenology, University of California Medical School, University Hospital, *Parnassus and Third Aves., San Francisco, Calif.*

STOPFORD, JOHN SEBASTIAN B., M.D., F.R.S., Vice-Chancellor, *University of Manchester, Manchester, England.*

STRAUS, WILLIAM L., JR., Ph.D., Associate in Anatomy, *Johns Hopkins Medical School, Baltimore, Md.*

STREETER, GEORGE L., A.M., M.D., Sc.D., LL.D. (Ex. Com. '18–'20, Pres. '26–'28), Chairman Division of Animal Biology; Director, Department of Embryology, *Carnegie Institution of Washington, Wolfe and Madison Sts., Baltimore, Md.*

STROMSTEN, FRANK ALBERT, B.S., M.S., D.Sc., Associate Professor of Zoölogy, State University of Iowa, *318 Zoölogy Building, Iowa City, Iowa.*

STRONG, LEON H., A.B., B.S., Ph.D., Assistant Professor of Anatomy, Medical School, University of Michigan, *1008 E. Medical Building, University of Michigan, Ann Arbor, Mich.*

STRONG, OLIVER S., A.B., A.M., Ph.D., Professor of Neurology and Neurohistology, Columbia University, *College of Physicians and Surgeons, 630 West 168th St., New York City.*

STRONG, REUBEN MYRON, A.B., A.M., Ph.D. (Ex. Com. '16–'19), Professor of Anatomy, *Loyola University School of Medicine, 706 South Lincoln St., Chicago, Ill.*

STULTZ, WALTER A., B.A., Ph.D., Instructor in Anatomy, *Medical College of the State of South Carolina, Charleston, S. C.*

STUNKARD, H. W., Ph.D., Professor of Biology, *New York University, New York City.*

SULLIVAN, WALTER EDWARD, A.M., Ph.D., Professor of Anatomy, University of Wisconsin, *Science Hall, Madison, Wis.*

SWANK, ROY L., B.S., M.B., M.D., Ph.D., *Peter Bent Brigham Hospital, Boston, Mass.*

SWENSON, E. A., A.B., A.M., Ph.D., Associate in Anatomy, *Medical Department, University of Pennsylvania, Philadelphia, Pa.*

SWETT, FRANCIS HUNTINGTON, A.B., A.M., Ph.D., Professor of Anatomy, Duke University School of Medicine, *Box 3710, Durham, N. C.*

SWIFT, CHARLES H., M.D., Ph.D., Associate Professor of Anatomy, *The University of Chicago, Chicago, Ill.*

SWINGLE, W. W., A.B., A.M., Ph.D., Professor of Biology, *Princeton University, Princeton, N. J.*

SYKES, GEORGE F., Ph.B., M.A., Assistant Professor of Anatomy, Tufts College Medical School, *416 Huntington Ave., Boston, Mass.*

TEITELBAUM, HARRY A., M.D., *Montefiore Hospital, Gun Hill Rd., New York City.*

TERRY, ROBERT JAMES, A.B., M.D. (Ex. Com. '08–'12, '21–'24), Professor of Anatomy, *Washington University School of Medicine, St. Louis, Mo.*

THARALDSEN, CONRAD E., B.S., M.A., Ph.D., Professor of Anatomy, *New York Medical College, 450 East 64th St., New York City.*

THOMPSON, IAN MACLAREN, B.Sc., M.B., Ch.B., Professor of Anatomy and Director of the Department, *Medical College, University of Manitoba, Winnipeg, Canada.*

THORKELSON, JACOB, M.D., *Butte Clinic, Inc., Butte, Mont.*

THRO, WILLIAM C., B.S., A.M., M.D., Associate Professor of Medicine (Clinical Pathology), *Cornell University Medical College, 1300 York Ave., New York City.*

THURINGER, JOSEPH M., M.D., Professor of Histology and Embryology and Head of Department, University of Oklahoma, School of Medicine, *East 13th and Phillips Sts., Oklahoma City, Okla.*

TILNEY, FREDERICK, A.B., M.D., Ph.D., D.Sc., Professor of Neurology and Neuro-Anatomy, Medical Director, Neurological Institute, Columbia University; Consultant in Neurology, Presbyterian, Babies, Roosevelt, Brooklyn, Methodist, Episcopal, and Greenwich Hospitals; *Neurological Institute, Medical Center, New York City.*

TODD, T. WINGATE, M.B., Ch.B. (Manc.), F.R.C.S. (Eng.), (Vice-Pres. '20–'21, Ex. Com. '24–'29), Director Developmental Health Inquiry, Professor of Anatomy, Director of the Hamann Museum of Comparative Anthropology, and Anatomy, School of Medicine, *Western Reserve University, 2109 Adelbert Road, Cleveland, Ohio.*

TOMPKINS, EDNA H., M.D., Assistant Professor of Anatomy, *Vanderbilt University Medical School, Nashville, Tenn.*

TOWER, SARAH SHELDON, B.S., Ph.D., M.D., Associate in Anatomy, *Johns Hopkins Medical School, Baltimore, Md.*

TRACY, HENRY C., A.B., A.M., Ph.D., Professor of Anatomy, *University of Kansas, Lawrence, Kansas.*

TROTTER, MILDRED, A.B., M.S., Ph.D., Associate Professor of Anatomy, *Washington University School of Medicine, St. Louis, Mo.*

TURNER, CHARLES W., B.S., A.M., Ph.D., Associate Professor of Dairy Husbandry, *University of Missouri, Columbia, Mo.*

TURNER, CLARENCE L., M.A., Ph.D., Professor of Zoölogy, *Northwestern University, Evanston, Ill.*

UHLENHUTH, EDUARD, Ph.D., Professor of Anatomy, *University of Maryland Medical School, Baltimore, Md.*

VAN CAMPENHOUT, ERNEST, M.D., Ph.D., Professor of Anatomy, *Université de Louvain, Louvain, Belgium.*

VAN CLEAVE, C. D., Ph.D., Instructor in Anatomy, *University of Pennsylvania Medical School, Philadelphia, Pa.*

VAN DER HORST, C. J., D.Sc., Professor, Head of the Department of Zoölogy, University of the Witwatersrand, *P. O. Box 1176, Johannesburg, South Africa.*

VAN WAGENEN, GERTRUDE, A.B., Ph.D., Research Assistant in Obstetrics and Gynecology, Assistant Professor's rank, Yale University, *New Haven Hospital, New Haven, Conn.*

VICARI, EMILIA, M.A., Associate in Anatomy, *Cornell University Medical College, 1300 York Ave., New York City.*

VONDERAHE, A. R., A.B., B.Sc., M.D., Assistant Professor of Anatomy, *University of Cincinnati, College of Medicine, Eden Ave., Cincinnati, Ohio.*

WAITE, FREDERICK CLAYTON, A.M., Ph.D., Professor of Histology and Embryology, Western Reserve University School of Medicine, *2109 Adelbert Road, Cleveland, Ohio.*

WALLER, WILLIAM H., Ph.D., Department of Anatomy, *George Washington University School of Medicine, Washington, D. C.*

WALLIN, IVAN E., M.A., D.Sc., Professor of Anatomy and Head of Department, Secretary of Faculty, *University of Colorado, School of Medicine, Denver, Colo.*

WALMSLEY, THOMAS, M.D., F.R.S.E., Professor of Anatomy, *Queen's University of Belfast, Belfast, Ireland.*

WARBRITTON, VIRGENE, M.A., Ph.D., Instructor in Animal Husbandry, *University of Missouri, College of Agriculture, Columbia, Mo.*

WARD, JAMES W., Ph.D., National Research Council Fellow in Anatomy, *Johns Hopkins Medical School, Baltimore, Md.*

WARREN, A. EMERSON, Ph.D., Assistant Professor of Biology, *McMaster University, Hamilton, Ontario, Canada.*

WATKINS, RICHARD WATKIN, S.B., M.D., Instructor in Otolaryngology, Rush Medical College, *5608 Kenwood Ave., Chicago, Ill.*

WATT, JAMES CRAWFORD, M.A., M.D., Professor of Anatomy, University of Toronto, *20 Hawthorne Ave., Toronto, Canada.*

WEATHERFORD, HAROLD LORRAINE, A.B., A.M., Ph.D., Assistant Professor of Anatomy, *Harvard Medical School, Boston, Mass.*

WEBB, RICHARD L., A.B., M.S., Ph.D., Assistant Professor of Anatomy, *College of Medicine, University of Illinois, 1853 W. Polk St., Chicago, Ill.*

WEED, LEWIS HILL, A.B., A.M., M.D., Sc.D. (Ex. Com. '20–'21; '35–, Sec.-Treas. '22–'30), Professor of Anatomy and Director, *Johns Hopkins Medical School, Baltimore, Md.*

WEISS, PAUL, Ph.D., Associate Professor of Zoölogy, *The University of Chicago, Chicago, Ill.*

WELLS, LEMEN J., Ph.D., Instructor in Anatomy, *University of Missouri, Columbia, Mo.*

WESTON, JEAN K., M.S., Ph.D., Instructor in Anatomy, *University of Michigan, Ann Arbor, Mich.*

WHEELER, THEODORA, A.B., M.D., Clinical Associate in Neurology, *Willoughby Tower, 8 South Michigan Ave., Chicago, Ill.*

WHITESIDE-HARVEL, BEATRICE, B.A., Ph.D., Voluntary Research Worker, *c/o Guaranty Trust Co., 140 Broadway, New York City.*

WIEMAN, H. L., Ph.D., Professor of Zoölogy, *University of Cincinnati, Cincinnati, Ohio.*

WILLARD, WILLIAM A., A.M., Ph.D., Professor of Anatomy, University of Nebraska, *College of Medicine, Forty-second St. and Dewey Ave., Omaha, Neb.*

WILLIAMS, GEORGE D., A.B., A.M., M.D., Ph.D., Assistant Professor of Anatomy, *Washington University School of Medicine, St. Louis, Mo.*

WILLIAMS, ROY GRIFFIN, A.B., A.M., M.D., Assistant Professor of Anatomy, *University of Pennsylvania School of Medicine, Philadelphia, Pa.*

WILLIAMS, STEPHEN CULVER, Ph.D., Associate in Anatomy, *Medical Department, University of Pennsylvania, Philadelphia, Pa.*

WILLIER, BENJAMIN HARRISON, Ph.D., Professor of Zoölogy, *University of Rochester, Rochester, N. Y.*

WILSON, JAMES THOMAS, M.A., M.B., LL.D., F.R.S., Professor of Anatomy, *University of Cambridge, Anatomy School, New Museums, Cambridge, England.*

WINDLE, WILLIAM F., B.S., M.S., Ph.D., Professor of Anatomy, Northwestern University Medical School, *303 East Chicago Ave., Chicago, Ill.*

WISLOCKI, GEORGE B., A.B., M.D. (Ex. Com. '37–), Parkman Professor of Anatomy, *Harvard Medical School, Boston, Mass.*

WITHERSPOON, THOMAS CASEY, M.D., F.A.C.S., *15375 Via de las Olas, Pacific Palisades, Calif.*

WITSCHI, EMIL, Ph.D., Professor of Zoölogy, *State University of Iowa, Iowa City, Iowa.*

WITTENBORG, A. H., M.D., Professor of Anatomy, *College of Medicine, University of Tennessee, Memphis, Tenn.*

WOLFE, J. M., Ph.D., Assistant Professor of Anatomy, *Vanderbilt University School of Medicine, Nashville, Tenn.*

WOODBURNE, RUSSELL T., M.A., Ph.D., Instructor in Anatomy, *University of Michigan, Ann Arbor, Mich.*

WOODMAN, ALICE S., M.D., Associate Professor of Histology and Embryology, *Boston University School of Medicine, 80 East Concord St., Boston, Mass.*

WOOLLARD, HERBERT H., M.D., D.Sc., Professor of Anatomy, *University College, London, England.*

WORCESTER, JOHN LOCKE, M.D., Professor of Anatomy, University of Washington, *5211 Twenty-first Ave., N. E., Seattle, Wash.*

YNTEMA, C. L., Ph.D., Instructor in Anatomy, *Cornell University Medical College, New York City.*

YOUNG, M. WHARTON, M.D., Ph.D., Assistant Professor of Anatomy, *Howard University, Washington, D. C.*

YOUNG, WILLIAM C., Ph.D., Assistant Professor of Biology, *Brown University, Providence, R. I.*

ZECHEL, GUSTAV, M.D., F.A.C.S., Assistant Professor in Anatomy, and Associate in Surgery, University of Illinois College of Medicine, *1853 W. Polk St., Chicago, Ill.*

ZIMMERMANN, ARNOLD, Lic.Sc., D.Sc. (Geneva, Switzerland), Associate Professor of Anatomy, University of Illinois College of Medicine, *1853 W. Polk St., Chicago, Ill.*

ZWEMER, RAYMUND L., A.B., Ph.D., Assistant Professor of Anatomy, College of Physicians and Surgeons, Columbia University, *630 West 168th St., New York City.*

THE EFFECT OF CONTINUED THEELIN INJECTIONS ON THE BODY GROWTH AND ORGAN WEIGHTS OF YOUNG FEMALE RATS

CLAY B. FREUDENBERGER AND FRED W. CLAUSEN
Department of Anatomy, University of Utah, Salt Lake City

ONE FIGURE

Moore and Price ('30) demonstrated that gonadal hormones inhibit the hypophysis in its production of gonad stimulating hormone. Spencer, D'Amour and Gustavson ('31, '32) found that injection of 20 rat units of estrin per day into immature rats inhibited growth and gonadal development. Their animals were injected for 54 days. They found that their injected animals had shorter bones than the controls.

Zondek ('36 a, '36 c) has recently studied the inhibitory effect of the follicular hormone given over long periods in amounts much larger than those ordinarily produced in the body. Zondek used infantile rats and found that in doses of 100 mouse units twice a week folliculin had no effect on body growth. On the other hand, when 1000 mouse units were injected subcutaneously twice a week, definite inhibition of growth was seen in $4\frac{1}{2}$ weeks. He found that the larger the amount of hormone, the greater the inhibition of growth. He stated that the effect was very obvious if 5000 to 10,000 mouse units dimenformon were applied twice a week. Zondek reported the finding of small ovaries, a shorter tail, shorter and lighter bones, and smaller and lighter 'inner organs' in the rats injected with large amounts of follicular hormone. He reported the average weights of the kidneys, pancreas, heart, liver, brain, and thymus in eight controls and eight experimental animals.

THE ANATOMICAL RECORD, VOL. 68, NO. 2
MAY, 1937

In this paper the effects of long-continued injections of large dosages of theelin into immature rats is to be reported. Modern biometrical methods are used in interpreting the results. As far as we are aware no former workers on this problem have used these methods.

MATERIALS AND METHODS

The rats used in our work were of the Wistar strain. Injections were begun at 3 weeks of age. Whenever possible, as was the case in most instances, a test animal was controlled by one of the same litter of approximately the same weight. The average weight at the time the injections were begun was 42 gm., being the same for the test animals as for the controls. All animals used were females. A constant water and food supply was furnished. Twenty-five test animals were given subcutaneous injections of theelin in oil (Parke, Davis and Co.) every other day while twenty-five control animals were injected with an equal amount of olive oil. Two-tenths cubic centimeter of theelin in oil was given at each injection. The theelin in oil was so made up that each cubic centimeter contained 1000 international units. Therefore, each test rat received 200 international units of theelin every other day or an average of 100 units daily. Each rat was weighed each time it received an injection.

At an average age of 99 days (range = 96 to 100 days) all rats were killed with ether and completely autopsied. The general care, diet, and method of autopsy were the same as described in a previous paper by Freudenberger and Billeter ('35).

To test the reliability of the differences obtained, the difference between the two means was divided by the probable error of the difference, thus obtaining the significance ratio. A significance ratio of 3 or above is usually interpreted as constituting a significant change not due to chance, a ratio between 2 and 3 as being of doubtful significance, and one below 2 as more likely being insignificant.

OBSERVATIONS AND DISCUSSION

Growth in body weight

A significant difference in the growth rates (fig. 1) of the two groups was observed. On the day the injections were begun the control animals average 42 gm. in weight while those animals to be injected with theelin averaged 41.56 gm. This difference was not significant. Two days later the control

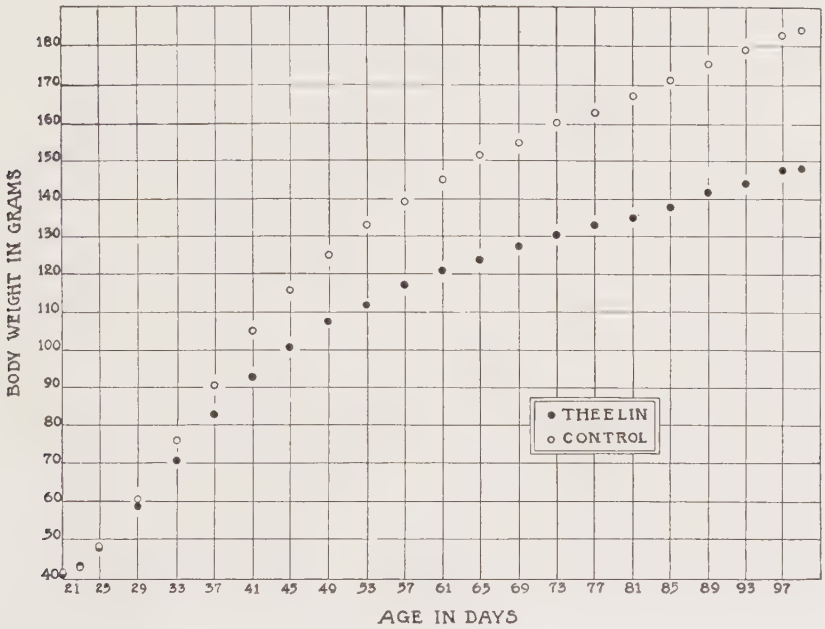

Fig. 1 Average body weight in grams according to age in days.

animals averaged 43.08 gm. in weight while the theelin-injected animals averaged 43.24 gm. Thereafter, the control animals were always found to be heavier than the theelin-injected ones. This difference increased until at 35 days of age the difference became significant (significance ratio = 3.1). At that time the controls averaged 82.96 gm. in weight while the test animals averaged 76.52 gm. On the day of autopsy the average weight of the control animals was 184.8 gm. and that of the test animals was 148.64 gm. The theelin-injected rats were therefore

smaller than the controls. The significance ratio for this difference was found to be 11.6.

Spencer, D'Amour and Gustavson ('31, '32) found the rate of increase in body weight to be substantially less in estrin-injected rats than in normal controls. They found that the growth rates were consistent, in no case did any injected animal grow as rapidly as any control animal. This was not found to be true in our series. Our theelin-injected rats at the time of autopsy ranged in weight from 119 to 196 gm. and our control rats ranged in weight from 155 to 212 gm. Nine of our test rats weighed more than 155 gm., the minimum weight for the controls. The body weights of the test animals were more variable than those of the controls, as expressed by the coefficients of variation, amounting to 11.18 for the tests and 8.75 for the controls.

Korenchevsky and Dennison ('34) found that large daily doses of oestrone decreased the appetite and gain in body weight without any definite change in the fat deposition. Cramer and Horning ('36) found in mice after the prolonged administration of oestrin the complete disappearance of fat, in fact a condition of cachexia. In our theelin-injected rats abundant fat was present both subcutaneously and abdominally. However, there was probably not as much fat present in the tests as in the controls as will be discussed later in this paper.

As mentioned previously, Zondek ('36 a, '36 c) found that growth was definitely inhibited in the infantile rat by the follicular hormone. Leonard, Meyer and Hisaw ('31) injected 2 rat units of estrin daily into infantile rats and after 41 to 66 days noted no great depression of body weight. Shumacker and Lamont ('35) found that continued administration of estrin (9 rat units daily for 67 days) did not influence growth.

Body and tail lengths

The theelin-injected rats had a shorter body length than the controls, the significance ratio for the difference being 10.3. The tail was also shorter in the test rats. The significance

ratio for the difference was 12.1. The test rats were, therefore, not only lighter in weight but were smaller animals than the controls. Zondek ('36 a, '36 c) found that rats treated with follicular hormone for 3 to 4 months were about 13% shorter than the controls.

Age at which the vagina opens

Each rat was examined each time an injection was made to determine the time at which the vagina opened. The vagina was found to be open in most of the theelin-injected rats at the age of 25 days. In a few of these the vagina was not found to be open until 27 days of age. The control rats had attained an average age of 39 days when the vagina opened.

Occurrence of infections

No difference in the incidence of infection in the nasal and middle ear cavities was found between the two groups. Pus was found to be present in one or both tympanic cavities in nine test animals and in nine control animals. A small amount of solidification was found in the lungs of six control animals and in four of the theelin-injected animals. No signs of infection could be detected at the site where injections were made.

No mammary gland or other type of tumors were found in any of our rats. Such tumors have been reported in estrin-treated animals by Cramer and Horning ('36).

Weight and length of individual organs

Head. The head (table 1) was significantly lighter in the test than in the control rats, the significance ratio being 12.5. No other reports of the weight of the head in theelin-injected animals have been found. However, Zondek ('36 c) stated that the head was narrower and shorter in rats treated with follicular hormone.

Integument. The integument (table 1) of the test rats weighed only 70% as much as that of the controls. The difference in the organ weights between the two groups was not

nearly that great in most cases. The significance ratio for the difference in the weight of the integument was 17.9. We would judge from this great difference in integument weight that the test animals were not as fat as the controls even though fat was abundant in the test animals in most cases.

TABLE 1

Organ weights, significance ratios and coefficients of variation

ORGAN	MEAN TESTS	MEAN CONTROLS	SIGNIFICANCE RATIO	COEFFICIENTS OF VARIATION	
				Tests	Controls
Body weight	148.64	184.80	11.6	11.18	8.75
Body length	18.38	19.55	10.3	3.47	2.81
Tail length	16.88	18.45	12.1	4.29	3.37
Head	14.7	17.2	12.5	6.96	6.19
Integument	19.5	27.7	17.9	13.50	7.83
Humerus weight	0.2263	0.2625	9.1	8.40	8.55
Humerus length	2.30	2.43	10.8	2.71	2.57
Femur weight	0.4754	0.5666	9.5	9.90	9.41
Femur length	2.91	3.11	12.9	3.17	2.38
Hypophysis	0.0101	0.0111	3.4	16.22	13.80
Thyroid	0.0139	0.0171	5.9	15.12	19.48
Suprarenal glands	0.0402	0.0421	1.7	15.23	13.55
Thymus	0.3698	0.5099	9.7	20.08	15.22
Brain	1.7258	1.7967	4.5	5.14	4.19
Spinal cord	0.4716	0.5076	7.6	5.63	4.49
Eyeballs	0.2306	0.2371	4.0	3.30	3.99
Heart	0.7317	0.7817	2.3	17.69	13.07
Lungs	1.2318	1.5547	5.1	20.67	25.12
Submaxillary glands	0.3462	0.3971	8.4	9.10	8.14
Alimentary group	13.980	15.268	3.3	14.21	14.02
Stomach	0.7480	0.8185	3.9	13.71	10.71
Intestines	3.5358	3.7041	1.9	14.95	11.12
Liver	7.5156	7.5672	0.3	15.10	12.75
Spleen	0.3786	0.4610	9.1	14.02	8.89
Kidneys	1.4851	1.5764	3.0	11.27	9.31
Ovaries	0.0270	0.0589	15.1	48.25	14.62
Uterus	0.3547	0.4088	4.0	12.55	21.89

Zondek ('36 a) reported that the hair was rough and shaggy in his rats treated with follicular hormone, and showed a tendency to fall out, particularly in the gluteal region. The fur appeared normal in both our groups of rats.

Skeletal system. The humerus and femur (table 1) were found to be both lighter and shorter in the test animals than in the controls, the significance ratios varying from 9.1 for the difference in humerus weight to 12.9 for the difference in femur length. Spencer, D'Amour and Gustavson ('32) made measurements on the skull and leg bone of estrin-injected rats and found them to have consistently shorter bones than the controls. Zondek ('36 a, '36 c) found that the inhibitory effect of the follicular hormone affected the skeleton. He found that the epiphyseal junctions were usually open in the experimental animals, whereas they were already closed in the controls. He also found a definite reduction in the weights and lengths of the femur and tibia.

Hypophysis. The average weight of the hypophysis (table 1) of the test animals was 91% of that of the controls. This difference can be considered significant since the significance ratio for the difference was 3.4. All of the hypophyses appeared normal grossly. Zondek ('36 b) found no marked difference in the weight of the pituitary of infantile female rats which had been injected for 15 weeks with 5000 mouse units of folliculin twice weekly. He noted a very large tumor of the pituitary in one of his experimental female rats. Cramer and Horning ('36) produced large pituitary tumors in estrin-treated mice. Korenchevsky and Dennison ('34) produced hypertrophy of the hypophysis in normal male rats with large doses of oestrone. Zondek ('36 b) also noted such an hypertrophy in the male.

Thyroid. The average weight of the thyroid gland (table 1) of the test animals was only 82% of that of the controls. The significance ratio for this difference was 5.9. Leonard, Meyer and Hisaw ('31) injected rats from 22 to 39 days of age with 2 to 4 rat units of estrin daily for periods of time varying from 22 to 60 days and reported that the weight of the thyroid remained unchanged. Pincus and Werthessen ('33) found an increase in weight of the thyroid gland in young rats due to continued injection of estrin.

Suprarenal glands. The suprarenal glands (table 1) of the test animals weighed only 5% less than those of the controls. The significance ratio for this difference was only 1.7 so the difference may not be a significant one. Since body weight was reduced 20% in the test animals, the suprarenal glands were actually relatively heavier in the tests than in the controls. Leonard, Meyer and Hisaw ('31) reported that the weight of the suprarenal glands remained practically unchanged in immature rats treated with estrin. Korenchevsky and Dennison ('34) produced hypertrophy of the suprarenal glands with oestrone. Zondek ('36 c) stated that the suprarenal glands were smaller in estrin-treated females than in the controls.

Thymus. The average weight of the thymus gland (table 1) of the test animals was only 72.5% of that of the controls. The significance ratio for this large difference was 9.7. Golding and Ramirez ('28) injected follicular hormone into young rats daily for from 20 to 36 days and found that the weights of the thymus glands of injected rats were about half of those of the controls. Leonard, Meyer and Hisaw ('31) found no difference in the weights of the thymus glands of test and control animals which they regarded as significant. Korenchevsky and Dennison ('34) found only small and indefinite changes in the weight of the thymus as a result of estrin injections in rats. Cramer and Horning ('36) found an atrophied thymus in mice subjected to the prolonged influence of estrin. Zondek ('36 c) reported a reduction of 12% in the weight of the thymus of rats subjected to prolonged injections of the follicular hormone.

Brain and spinal cord. The average weight of the brain (table 1) was 4% less in the test animals than in the controls and the average weight of the spinal cord (table 1) was 7% less in the tests. Both these differences can be regarded as significant, since the significance ratio for the difference in the brain weights was 4.5 while that for the spinal cord was 7.6. Zondek ('36 c) found the brain weight to be 12% less in animals treated with follicular hormone than in controls.

Eyeballs. The average weight of the eyeballs (table 1) was 3% less in the test animals than in the controls. Since the significance ratio was 4, the difference was considered as significant.

Heart. The average weight of the heart (table 1) of the test animals was 94% of that of the controls. The significance ratio for this difference was only 2.3, so the difference may not be significant. Korenchevsky and Dennison ('34) found that the actual weight of the heart was slightly decreased in male rats treated with oestrone. Zondek ('36 c) found a 23% decrease in the weight of the heart of rats which received large amounts of follicular hormone.

Lungs. The average weight of the lungs (table 1) of the test rats was 21% less than that of the controls, the significance ratio for this difference being 5.1. No other investigators of this problem have reported on the lung weights so far as we know.

Submaxillary glands. The average weight of the submaxillary glands (table 1) of the test rats was 87% of that of the controls, the significance ratio for this difference being 8.4.

Alimentary group, stomach and intestines. The 'alimentary group' consists of the stomach and intestines with their contents, mesentery and pancreas. Its average weight (table 1) was 8% less in the tests than in the controls, the significance ratio for the difference being 3.3. The average weight of the empty stomach (table 1) was also 8% less in the tests than in the controls. The significance ratio for this difference was 3.9. Even though the average weight of the empty intestines (table 1) was 4% less in the tests than in the controls, the difference may not be significant since the significance ratio for the difference was only 1.9.

Liver. The average weight of the liver (table 1) was less than 1% less in the tests than in the controls. The difference was not significant since the significance ratio was only 0.3. Korenchevsky and Dennison ('34) found a slight decrease in the actual weight of the liver in male rats treated with oestrone. Zondek ('36 c) found the liver to weigh 21% less in

eight rats treated with follicular hormone than in eight controls.

Spleen. The average weight of the spleen (table 1) was 18% less in the test animals than in the controls. The significance ratio for the difference was 9.1. Korenchevsky and Dennison ('34) found that the spleen tended to be slightly heavier in male rats treated with oestrone than in the controls. Cramer and Horning ('36) stated that the spleen was sometimes reduced to a thin red ribbon in their mice treated with estrin. Zondek ('36 c) found the spleen to weigh 10% less in rats treated with follicular hormone than in controls.

Kidneys. The average weight of the kidneys (table 1) was 6% less in the test animals than in the controls, the significance ratio for this difference being 3.0. Korenchevsky and Dennison ('34) found a slight decrease in the weight of the kidneys of their oestrone treated male rats. Zondek ('36 c) found the kidneys to weigh 31% less in rats treated with follicular hormone than in controls.

Ovaries. The average weight of the ovaries (table 1) of the tests was only 46% of that of the controls. The significance ratio for this difference was 15.1. Practically all authors agree that the development of the ovaries is retarded by the prolonged application of follicular hormone. The ovaries of the test animals ranged in weight from 0.0129 to 0.0694 gm., while those of the controls ranged from 0.0411 to 0.0750 gm. The ovaries of four of the test rats weighed more than 0.0411 gm., the minimum weight of the ovaries of the controls. The extreme variability of the weights of the ovaries of the test animals was indicated by the coefficient of variation which was found to be 48.3. The coefficient of variation for the controls was only 14.6.

Uterus. The average weight of the uterus (table 1) of the test animals was 87% of that of the controls, the significance ratio of this difference being 4.0. The coefficient of variation for the weights of the uterus of the control animals was 21.9 while that for the test animals was only 12.6. Spencer, D'Amour and Gustavson ('32) found that the uteri weighed

only 53% as much in their estrin-injected rats as those of the controls. Zondek ('36 a) found that the uterus showed much enlargement in rats treated with follicular hormone.

SUMMARY AND CONCLUSIONS

This article analyzes the effect of large dosages of theelin upon the body growth and organ weights of immature female rats. The treatment was extended over a period of approximately 11 weeks. Twenty-five rats were injected subcutaneously every other day with theelin in oil (200 international units) and the same number of controls were injected with an equal quantity of olive oil. The injections were begun when the rats were 3 weeks of age. At the end of the period of treatment all animals were killed, completely autopsied, and the organs weighed. Modern biometrical methods were used in interpreting the results.

The growth in body weight was definitely inhibited in the theelin-treated rats. Beginning with the fourth day after treatment was begun, the average weight of the test animals was less than that of the controls. The difference became significant on the fourteenth day and continued to be so thereafter. On the day of autopsy the average body weight of the theelin-treated rats was 80% of that of the controls. The test rats appeared normal with the exception of the fact that they were small.

The average body and tail lengths were significantly smaller in the test rats. The following parts and organs were found to weigh significantly less in the test rats than in the controls: head, integument, humerus, femur, hypophysis, thyroid, thymus, brain, spinal cord, eyeballs, lungs, submaxillary glands, alimentary group, stomach, spleen, kidneys, ovaries, and uterus. The average lengths of the humerus and femur were significantly less in the test animals. The average weights of suprarenal glands, heart, and intestines were also less in the test animals, but the differences may not be significant. Practically no difference in the average weight of the liver was found between the tests and controls.

LITERATURE CITED

Cramer, W. and E. S. Horning 1936 Experimental production by oestrin of pituitary tumours with hypopituitarism and of mammary cancer. The Lancet, vol. 230, pp. 247–249.

Freudenberger, C. B. and O. A. Billeter 1935 The effect of spaying on body growth and the organ weights of the albino rat. Endocrinology, vol. 19, pp. 347–355.

Golding, G. T. and F. T. Ramirez 1928 Ovarian and placental hormone effects in normal, immature albino rats. Endocrinology, vol. 12, pp. 804–812.

Korenchevsky, V. and M. Dennison 1934 The effect of oestrone on normal and castrated male rats. Biochem. J., vol. 28, pp. 1474–1485.

Leonard, S. L., R. K. Meyer and F. L. Hisaw 1931 The effect of oestrin on development of the ovary in immature female rats. Endocrinology, vol. 15, pp. 17–24.

Moore, C. R. and D. Price 1930 The question of sex hormone antagonism. Proc. Soc. Exp. Biol. and Med., vol. 28, pp. 38–40.

Pincus, G. and N. Werthessen 1933 The continued injection of oestrin into young rats. Am. J. Physiol., vol. 103, pp. 631–636.

Shumacker, H. B., Jr. and A. Lamont 1935 Lack of effect of theelin upon somatogenic, thyreotropic, and adrenotropic activity of the hypophysis. Proc. Soc. Exp. Biol. and Med., vol. 32, pp. 1568–1570.

Spencer, J., R. G. Gustavson and F. E. D'Amour 1931 Effects of estrin injections on the growth curve of young rats. Proc. Soc. Exp. Biol. and Med., vol. 28, pp. 500–501.

Spencer, J., F. E. D'Amour and R. G. Gustavson 1932 Effects of continued estrin injections on young rats. Am. J. Anat., vol. 50, pp. 129–139.

Zondek, B. 1936 a The inhibitory effect of follicular hormone on the anterior lobe of the pituitary gland. The Lancet, vol. 230, pp. 10–12.

——— 1936 b Tumour of the pituitary induced with follicular hormone. The Lancet, vol. 230, pp. 776–778.

——— 1936 c Impairment of anterior pituitary functions by follicular hormone. The Lancet, vol. 231, pp. 842–847.

THE STRUCTURE OF THE NEPHRON IN THE SCULPIN, MYOXOCEPHALUS OCTODECIMSPINOSUS

ALLAN L. GRAFFLIN

Department of Anatomy, Harvard Medical School

THREE TEXT FIGURES AND TWO PLATES (TWENTY-SIX FIGURES)

Previous work has demonstrated a wide diversity in the structure of the nephron in teleosts, the most striking finding being the complete absence of glomeruli (see the most recent paper of Edwards, '35, and the review of Marshall, '34). Under the circumstances, it is necessary to have a thorough knowledge of the morphology of the nephron in any species used for functional studies upon the kidney. This statement applies with particular force in the case of the sculpin (Myoxocephalus octodecimspinosus), which has been rather extensively employed for physiological work (Marshall, '30; Smith, '30; Grafflin, '31, '35, '36 a, b, and c; Marshall and Grafflin, '32; Defrise, '32; Clarke, '34, '36; Pitts, '34; Grafflin and Ennis, '34; Grafflin and Eisenberg, '34; Grafflin and Gould, '36). A considerable amount of information upon the nephron of this species is already available in the literature, and this information will be summarized as briefly as possible before proceeding with a description of the findings in the present study.

The sculpin kidney was first mentioned by Marshall ('30), who described the nephron as glomerular. Marshall and Smith ('30), in their extensive survey, grouped the sculpin with the fishes showing excellent glomerular development, and gave the average diameter of the glomerulus as 81 μ. Nash ('31) reported complete glomerular counts in three sculpins, and in maceration material found no aglomerular

nephrons, "in spite of a quite extensive search." He supplied drawings of two macerated nephrons, and in their accompanying measurements gave 50 μ as the approximate length of the 'neck segment.' Marshall and Grafflin ('32) diagrammed the sculpin nephron as having the following structure: 1) glomerulus, 2) proximal convoluted segment (brush border segment), 3) initial collecting segment. No mention of a specialized neck segment was made, and they concluded, erroneously, that the proximal convoluted segment exhibits only one type of cell. Defrise ('32) subsequently showed that this segment contains two types of cells:

> The nephron of the sculpin is morphologically unisegmental, but from a strictly cytological point of view is composed of two types of cells, different in the shape of the Golgi substance . . . . The substance O of the Golgi complex . . . . may be either in the basal part of the cell (scattered, as rods) or in the supranuclear zone (as masses). These differences in the shape and position of the Golgi substance cannot be interpreted as functional changes, because cells with rods and cells with masses are regularly disposed in two different portions of the tubule: rods in the proximal, and masses in the distal.[1]

In terms of Golgi substance, Defrise found a rather long intermediate zone of transition between the two distinct cell types (Grafflin, '33, footnote 7, p. 71). From his illustration of the proximal part of the nephron, the Golgi rods are predominantly in the paranuclear and supranuclear zones (apical two-thirds of the cell) rather than in the basal region proper. With respect to the chondriome, Defrise states simply that in the sculpin nephron (compared to the toadfish) it is 'more similar' to that of the mammalian proximal convoluted segment. In his illustrations of isolated cells, which include both cell types in terms of Golgi substance, the mitochondria are rather long, coarse filaments, for the most part vertically oriented, but no clear-cut difference between the two cell types is apparent.[2] Defrise makes no mention of a neck segment in the nephron, but identified the initial collecting segment. He illustrated one isolated ciliated cell without further comment.

[1] This statement, taken from Defrise's text, is correct. There is an error in his plate legends; for figure 6 'distal part' should be changed to 'proximal part,' and the reverse change should be made for figure 8.

[2] Defrise reports the presence of a flagellated diplosome for the cells of the proximal convoluted segment, and comments upon the variations in the appearance of the brush border.

In his study of the closely related daddy sculpin (Myoxocephalus scorpius) Grafflin ('33) reported the presence of two histologically distinct portions in the proximal convoluted segment, the transition between them being abrupt. This finding is in sharp contrast to the gradual transition, in terms of Golgi substance, between the two-cell types in the sculpin, as noted by Defrise.

Marshall ('34), in his diagram of the sculpin nephron, included a neck segment; it is clear that he considered it to be ciliated, and Grafflin and Eisenberg ('34) definitely state it to be so. Edwards ('35) described the sculpin nephron as follows:

> The kidney . . . . is composed of trisegmental, glomerular tubules. . . . The neck segment is long and its narrow, low columnar, basophilic cells lack cilia . . . . The next two segments, of which the proximal one is the shorter, differ from each other as follows: the cells of the proximal segment are generally lower, narrower, more lightly staining and basophilic. The cytoplasm between the nuclei and the lumen is homogeneous and does not stain appreciably with eosin. Elsewhere it is less homogeneous. The brush border is taller. . . . A short segment, cytologically similar to the small, terminal ducts, connects the tubule with the duct system except where the nephron joins a large branch of the collecting duct system.

In summary, there is general agreement that the nephron of the sculpin is typically constituted as follows: 1) glomerulus, 2) neck segment, 3) proximal convoluted segment (brush border segment), 4) initial collecting segment. It is further evident that the proximal convoluted segment is differentiated into two portions. Points at issue are: 1) The glomerular status of the sculpin. This is important for two reasons: a) the sculpin has regularly been considered in physiological studies as a typical glomerular marine teleost; b) the kidney of the closely related daddy sculpin (Myoxocephalus scorpius) exhibits pronounced degenerative changes in the glomeruli, so that some specimens are functionally entirely aglomerular (Grafflin, '33). 2) The neck segment. Grafflin and Eisenberg state that this segment is ciliated, Edwards that it is devoid of cilia. 3) The nature of the transition between the two differentiated portions of the proximal convoluted segment.

On the basis of Golgi substance Defrise found the transition to be a gradual one. In his account Edwards nowhere states whether the transition is abrupt or gradual. In his figure (fig. 6) the transition is shown as abrupt, but the figure has clearly been pieced at this point. Nevertheless, one may infer that Edwards considered the transition to be histologically abrupt. Grafflin ('33) reported an abrupt transition, on histological grounds, between the two portions of the proximal convoluted segment in the daddy sculpin.

An account of the present observations will now be given. These observations were made upon material from the posterior kidney of six specimens of the following weights: 40, 121, 153, 189, 259 and 295 gm. Fixation was in Zenker-formol, Zenker's and Bouin's fluids. Serial sections at 5 μ were prepared from all specimens, and were stained with hematoxylin and eosin, iron hematoxylin and orange G, and Heidenhain-azan. The specimens were collected at the Mt. Desert Island Biological Laboratory, Salsbury Cove, Maine.

General morphology of the nephron

The general morphology of the sculpin nephron, as observed in maceration material, is illustrated in figure 1 (B, C and D). As seen in situ in this material each nephron comprises a rather tightly coiled mass attached to the collecting duct tree. The picture is entirely similar to that of the eel nephron as shown by wax reconstruction (Grafflin, '37 a). For the purpose of making the drawings each nephron was carefully uncoiled in a small dish of water and its outline traced directly. No attempt to mount the isolated tubules on slides was made. All of the nephrons show a glomerulus, the size of which is quite variable. No aglomerular nephrons were observed. The degree of constriction in the region of the neck segment shows marked variations, and in these preparations it is impossible to measure, with even a semblance of accuracy, the length of the neck segment. The remainder of the nephron, to the point of junction with a collecting duct, shows no evidence of subdivision into differentiated portions or segments.

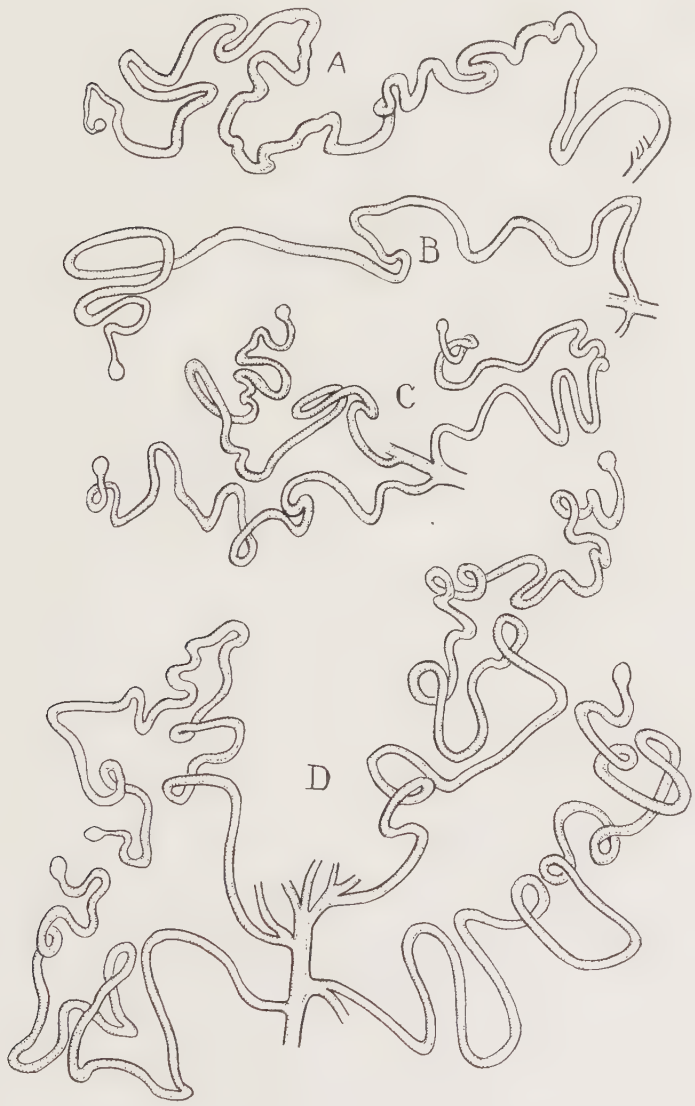

Fig. 1 Renal tubules isolated from hydrochloric acid maceration material. B, C and D, Myoxocephalus octodecimspinosus, weight 180 gm. A, Myoxocephalus scorpius, weight 775 gm. Camera lucida drawings at × 30. As reproduced, × 22½.

For the sake of completeness the total length of the nephrons, as determined with a simple 'map measurer,' is as follows: B, 6.67 mm.; C (read clockwise) 4.33, 4.67 and 4.40 mm.; D (read clockwise), 6.73, 7.03, 9.33 and 10.00 mm.; average of eight nephrons, 6.65 mm. The high degree of swelling regularly observed in the maceration material makes these measurements, as well as those of Nash ('31) and Marshall ('34), almost valueless for direct comparison with those obtained from wax reconstruction. Unfortunately no such reconstruction of the sculpin nephron is available.

A single glomerular nephron of the closely related daddy sculpin (Myoxocephalus scorpius) is illustrated in figure 1 (A). As described elsewhere (Grafflin, '33), the glomeruli of the latter species exhibit marked degenerative changes (see below).

Glomeruli

In each of the specimens, all of which fall within the range of weight usually employed for physiological experimentation, the glomeruli exhibit a wide variation in size, vascularity, lobulation and cellularity (presence of connective tissue elements). The majority of the glomeruli fall within the range of size illustrated in figures 8 to 13. These glomeruli are usually quite well vascularized, and the glomerular membrane is rather delicate. Connective tissue elements may or may not form a prominent component of the tuft; they tend to be diffusely distributed, and no instance has been observed of a well-defined central cellular core such as characterizes the glomeruli of birds and reptiles (Vilter, '35; also, see Bargmann, '36). Lobulation is much more extensive in some cases than in others. Very small glomeruli (figs. 4 to 7) are relatively few in number, but are regularly present. In these the vascularization may be quite poor, and an avascular central cellular core may occur. Also, the visceral epithelium may be appreciably, even markedly, thickened. At the other extreme are the very large glomeruli of the type illustrated in figure 14. While comparatively rare, such glomeruli have been observed in all specimens. The tuft is abundantly

vascularized, but usually shows scattered connective tissue cells in fair numbers, as in the instance pictured.

Some glomerular tufts, of varying sizes, show the presence of well-defined central cysts, entirely analogous to those previously described in M. scorpius (Grafflin, '33). These cystic glomeruli are of quite infrequent occurrence in all specimens but one. In the latter case, in one restricted portion of the kidney, such cystic glomeruli comprise almost one-third of the total glomeruli. This aspect of the problem is discussed in more detail elsewhere (Grafflin, '37 b). Occasionally one finds a glomerulus which exhibits a markedly enlarged, irregular and cystic intracapsular space (figs. 15 and 16). In such instances the capsule is without outlet, the abortive neck segment, where it persists, ending blindly. Strangely enough, the intracapsular space may be almost, or entirely, free of coagulum.

Neck segment

A differentiated neck segment is regularly present in the sculpin nephron. It is highly variable in length and in the degree of ciliation. In many nephrons the segment is fully ciliated; in others the cilia are moderately or markedly reduced in numbers; and in still others they are completely absent. The latter condition exists in only a small minority of cases. Some of the variations encountered are illustrated in figures 17 to 23. Figure 17 is interesting to show the far greater extent of the cells of the neck segment on one side of the tubule (to the right) than on the other. Figures 18, 19 and 21 illustrate an arrangement frequently observed: while the more distal portion of the segment is heavily ciliated, the first portion is almost, or entirely, devoid of cilia. Figure 23 represents a long and fully ciliated segment with an unusually wide lumen; despite the abnormal dilatation of the lumen, the passage into the proximal convoluted segment is entirely unobstructed.

Proximal convoluted segment

The proximal convoluted segment, comprising that entire portion of the nephron lined by epithelium provided with brush border, may be subdivided, on histological grounds, into two distinct parts, which will be referred to simply as the first and second portions of the segment.

First portion. The transition from the neck segment to the first portion of the proximal convoluted segment is typically abrupt, though the transition may be at different levels on the two sides of the tubule as seen in section (figs. 17, 19, 21). The picture in this region is somewhat complicated by the fact that scattered isolated ciliated cells, which occur along the entire first portion of the proximal convoluted segment, are usually present in fair numbers just distal to the transition from the neck segment (figs. 19, 20, 21), and may be particularly abundant when the associated neck segment is entirely unciliated.

The cells of this first portion of the proximal convoluted segment have the following histological structure. The nuclei, usually oval or elongated but sometimes spherical, are as a rule located approximately in the center of the cell (fig. 24), but may be basal in position. The brush border is characteristically rather high (figs. 24 and 25); however, on individual cells, all degrees of reduction of the brush border, down to complete absence, have been noted. Between the nuclei and the brush border the delicate cytoplasm is very faintly eosinophilic. In the infranuclear and to some extent the paranuclear zones the cytoplasm is considerably denser than in the apical region and stains better with eosin. The basal cytoplasm exhibits, in varying degree, a distinctly filamentous structure. The filaments are rather long and moderately thick, and are regularly oriented in the vertical direction.

Transition from first to second portion. In a majority of the instances which have been observed, the transition from the first to the second portion of the proximal convoluted segment is histologically abrupt (fig. 26), though the transition may be at different levels on the two sides of the tubule

as seen in section. The high brush border persists to the point of transition, and there is no increase in the number of isolated ciliated cells in this region, as has been noted in the eel (Grafflin, '37 a). In some nephrons a small nest of cells (up to about 15 cells in length) typical of the second portion has been observed among the cells of the first portion in the zone just preceding an abrupt transition. In occasional nephrons, in this zone, cells of the second portion are found scattered about, singly or in small groups, among the cells of the first portion for a short distance. This is true in the instance photographed in figure 27. A single cell of the second portion is indicated by the arrow, and several others occur in adjacent sections. Beyond the point of transition, cells of the first portion have not as yet been observed.

Second portion. The second portion of the proximal convoluted segment is readily distinguished from all other portions of the nephron by its high degree of eosinophilia (fig. 28). The nuclei are spherical or oval, and tend to be located apical to the center of the cell; they are in general smaller than those of the first portion. The brush border is as a rule considerably lower than that found typically in the first portion. On individual cells, all degrees of reduction of the brush border, down to complete absence, have been noted. The cytoplasm in the infranuclear and paranuclear zones is very dense and highly eosinophilic. In the apical region the cytoplasm is far less dense and only very faintly eosinophilic. The basal cytoplasm shows a coarse filamentous structure, the filaments being oriented vertically. In favorable preparations of Zenker-formol material, stained with iron hematoxylin, the mitochondria are very well demonstrated. They are seen to be predominantly rather coarse and fairly long filaments, with a striking vertical orientation, and giving a distinct picture of batonnets in the basal portion of the cell. The apical cytoplasm shows only very few mitochondria, in the form of short rods and granules. Isolated ciliated cells regularly occur in this second portion, and are scattered at random throughout its length.

Cell boundaries are quite clearly defined in both portions of the proximal convoluted segment, and, in tangential sections through the apices, it is seen that the cell outlines are quite regular in shape, usually hexagonal. The most interesting pattern observed in the present study is illustrated in figure 2. Accessory nuclei, of varying shapes, occur among the epithelial cells of both portions of the segment, and are interpreted to represent in wandering leucocytic elements.[3]

Initial collecting segment

An initial collecting segment, of variable length but always relatively short, is usually present. Edwards ('35) has already reported the exceptional absence of such a segment, in

Fig. 2 An interesting and unusual pattern of the luminal cell outlines in the second portion of the proximal convoluted segment. Camera lucida drawing. × 867.

cases where the nephron joins a large branch of the cellecting duct system. The transition from the second portion of the proximal convoluted segment to the initial collecting segment is typically abrupt, giving the picture shown to the left of figure 29. The transition, though abrupt, is frequently at different levels on the two sides of the tubule as seen in section. The following variations in the zone of transition

[3] In all of the specimens small unicellular parasites have been observed which are identical with those previously reported, and designated as 'group 1,' in the daddy sculpin (M. scorpius) (Grafflin, '33). These parasites have been found in both portions of the proximal convoluted segment, in the initial collecting segment, and in all orders of the collecting tubules, but never in the glomerulus or neck segment. None of the parasites designated as 'group 2' in the previous paper have been observed in the present material. Though identification has as yet been impossible, it seems quite clear that these unicellular structures must be considered as parasites. They bear no relation morphologically to the 'intercalated cells' reported in the nephrons of certain fishes by Policard and Mawas ('06), or to any of the formed elements of the blood and connective tissue.

have been observed: 1) one or more small nests of cells typical of the initial collecting segment interposed among the cells of the second portion of the proximal convoluted segment prior to a typical abrupt transition (as, for example, in fig. 3, above and to the left); 2) one or more small nests of cells of the second portion in the initial collecting segment, distal to the transition; 3) cells of the second portion, singly or in very small groups, scattered irregularly among the cells of the initial collecting segment, distal to an abrupt transition; 4) a

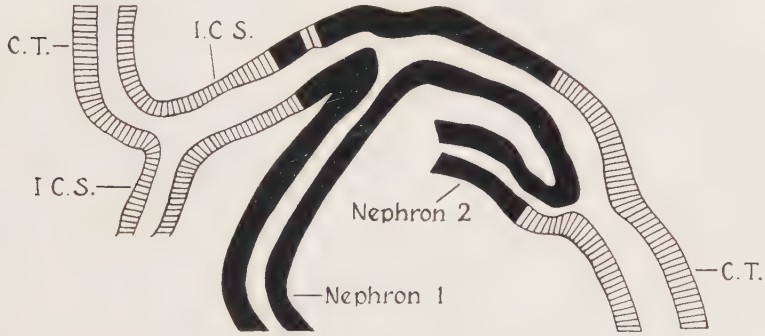

Fig. 3 Schematic representation (prepared with the aid of camera lucida sketches) of an anomalous arrangement, with a single nephron (nephron 1) draining into two entirely separate collecting tubules. Epithelium characteristic of the second portion of the proximal convoluted segment is represented in solid black; epithelium characteristic of the initial collecting segment (I. C. S.) and collecting tubules (C. T.) is lined.

rather intimate admixture of the two cell types in the zone of transition, so that the transition is in no sense histologically abrupt. Such an admixture of cell types in this region has previously been reported for the nephrons of certain fishes by Policard and Mawas ('06).

One striking anomalous arrangement was observed, with a single nephron draining into two entirely separate collecting tubules (figs. 3 and 29). To my knowledge, this finding is unique for the vertebrate kidney.

DISCUSSION

As mentioned above, it has been assumed in physiological studies that the sculpin could be considered as a typical glomerular marine teleost. The data of the present histological study fully establish the validity of this assumption. Although they exhibit considerable variability in their size and vascularization, the glomeruli are in the main well developed, and are in no sense the seat of the extensive degenerative changes which characterize the closely related daddy sculpin, M. scorpius (Grafflin, '33). The neck segments are likewise free from such changes, and no aglomerular nephrons have been observed.[4]

The degree of ciliation in the neck segment is highly variable, and in some cases this segment is entirely unciliated. However, such instances are in the minority, and this segment is to be regarded as typically ciliated.

The transition between the first and second portions of the proximal convoluted segment is usually histologically abrupt. In some nephrons cells typical of the second portion are found among the cells of the first portion for a short distance proximal to the point of transition. As discussed above, Defrise ('32) found a rather long zone of transition, in terms of Golgi substance, between the two portions. In view of the present findings, it is concluded that Defrise's observations probably indicate a variation in the morphology of the Golgi substance in this region which is independent of the two histologically distinct cell types. Unfortunately Defrise does not describe his observations in sufficient detail to make the matter clear. However, in favor of this interpretation are Defrise's ('34) subsequent findings in the common eel. In terms of Golgi substance, the transition between the first and second portions of the proximal convoluted segment is likewise gradual in this latter species. Histologically, on the other hand, the transition is invariably abrupt, and no admixture of the two cell types in this region ever occurs (Grafflin, '37 a).

[4] In every specimen examined, markedly atrophic and basophilic nephrons occasionally occur. However, such degenerate nephrons are present in such small numbers, and have been observed in the kidneys of so many fishes, that they may be neglected for the purpose of this discussion.

SUMMARY

The nephron of the sculpin (Myoxocephalus octodecimspinosus) is typically constituted as follows: 1) glomerulus, 2) ciliated neck segment, 3) proximal convoluted segment (brush border segment), and 4) initial collecting segment. The proximal convoluted segment is further subdivided into two histologically distinct portions, the transition between them being typically abrupt; scattered isolated ciliated cells are present along both portions. Although they exhibit considerable variability in their size and vascularization, the glomeruli are in the main well developed, and do not show the extensive degenerative changes which characterize the closely related Myoxocephalus scorpius. For physiological work upon the kidney, the sculpin is to be considered as a typical glomerular marine teleost.

LITERATURE CITED

Bargmann, W. 1936 Über den Bau der Nierenglomerulus der Reptilien. Zeit. f. Zellforsch. u. mikr. Anat., Bd. 25, S. 335.

Clarke, R. W. 1934 The xylose clearance of Myoxocephalus octodecimspinosus under normal and diuretic conditions. J. Cell and Comp. Physiol., vol. 5, p. 73.

——— 1936 Simultaneous xylose and inulin clearances in the sculpin. Bull. Mt. Desert Island Biol. Lab., p. 25.

Defrise, A. 1932 Cytophysiological studies of the nephrocytes of unisegmental aglomerular and glomerular nephrons. Anat. Rec., vol. 54, p. 185.

——— 1934 Ricerche di citofisiologia renale. Il nefrone bisegmentale. Arch. Ital. di Anat. e di Embriol., T. 33, p. 693.

Edwards, J. G. 1935 The epithelium of the renal tubule in bony fish. Anat. Rec., vol. 63, p. 263.

Grafflin, A. L. 1931 Urine flow and diuresis in marine teleosts. Am. J. Physiol., vol. 97, p. 602.

——— 1933 Glomerular degeneration in the kidney of the daddy sculpin (Myoxocephalus scorpius). Anat. Rec., vol. 57, p. 59.

——— 1935 Renal function in marine teleosts. I. Urine flow and urinary chloride. Biol. Bull., vol. 69, p. 391.

——— 1936 a Renal excretion of cyanol in the sculpin. Proc. Soc. Exp. Biol. and Med., vol. 34, p. 178.

——— 1936 b Renal function in marine teleosts. III. The excretion of urea. Biol. Bull., vol. 70, p. 228.

——— 1936 c Renal function in marine teleosts. IV. The excretion of inorganic phosphate in the sculpin. Biol. Bull., vol. 71, p. 360.

Grafflin, A. L. 1937 a Observations upon the structure of the nephron in the common eel. Am. J. Anat., vol. 61, pp. 21–62.

——— 1937 b Cyst formation in the glomerular tufts of certain fish kidneys. Biol. Bull., April.

Grafflin, A. L. and M. J. Eisenberg 1934 A microfluoroscopic study of teleostean kidneys. Anat. Rec., vol. 59, p. 449.

Grafflin, A. L. and D. Ennis 1934 The effect of blockage of the gastro-intestinal tract upon urine formation in a marine teleost, Myoxocephalus octodecimspinosus. J. Cell. and Comp. Physiol., vol. 4, p. 283.

Grafflin, A. L. and R. G. Gould, Jr. 1936 Renal function in marine teleosts. II. The nitrogenous constituents of the urine of sculpin and flounder, with particular reference to trimethylamine oxide. Biol. Bull., vol. 70, p. 16.

Marshall, E. K., Jr. 1930 A comparison of the function of the glomerular and aglomerular kidney. Am. J. Physiol., vol. 94, p. 1.

——— 1934 The comparative physiology of the kidney in relation to theories of renal secretion. Physiol. Rev., vol. 14, p. 133.

Marshall, E. K., Jr. and A. L. Grafflin 1932 The function of the proximal convoluted segment of the renal tubule. J. Cell. and Comp. Physiol., vol. 1, p. 161.

Marshall, E. K., Jr. and H. W. Smith 1930 The glomerular development of the vertebrate kidney in relation to habitat. Biol. Bull., vol. 59, p. 135.

Nash, J. 1931 The number and size of glomeruli in the kidneys of fishes, with observations on the morphology of the renal tubules of fishes. Am. J. Anat., vol. 47, p. 425.

Pitts, R. F. 1934 Urinary composition in marine fish. J. Cell. and Comp. Physiol., vol. 4, p. 389.

Policard, A. and J. Mawas 1906 Le canalicule urinaire des téléostéens. Bibl. Anat., vol. 15, p. 215.

Smith, H. W. 1930 The absorption and excretion of water and salts by marine teleosts. Am. J. Physiol., vol. 93, p. 480.

Vilter, R. W. 1935 The morphology and development of the metanephric glomerulus in the pigeon. Anat. Rec., vol. 63, p. 371.

PLATES

PLATE 1

EXPLANATION OF FIGURES

4 to 7 Four examples of the small, poorly vascularized glomerular tufts not infrequently encountered in all specimens examined.

8 to 13 Glomeruli in this range of size comprise the majority of the glomerular tufts in the specimens examined. Note the variations in vascularity, lobulation and cellularity.

14 An example of the very large glomeruli encountered in small numbers in all specimens examined.

15, 16 Two examples of glomeruli with markedly irregular, cystic capsules. In figure 16 all of the cavities interconnect. See text.

Figures 4 through 14 at same magnification (× 480) for direct comparison. Figures 15 and 16, × 255. Figures 4, 6, 8, 9, 10, 12, 14, fixation Zenker-formol; other figures, Zenker's. Figures 8, 9, 13, 15, Heidenhain-azan; figure 10, iron hematoxylin and orange G; other figures, hematoxylin and eosin.

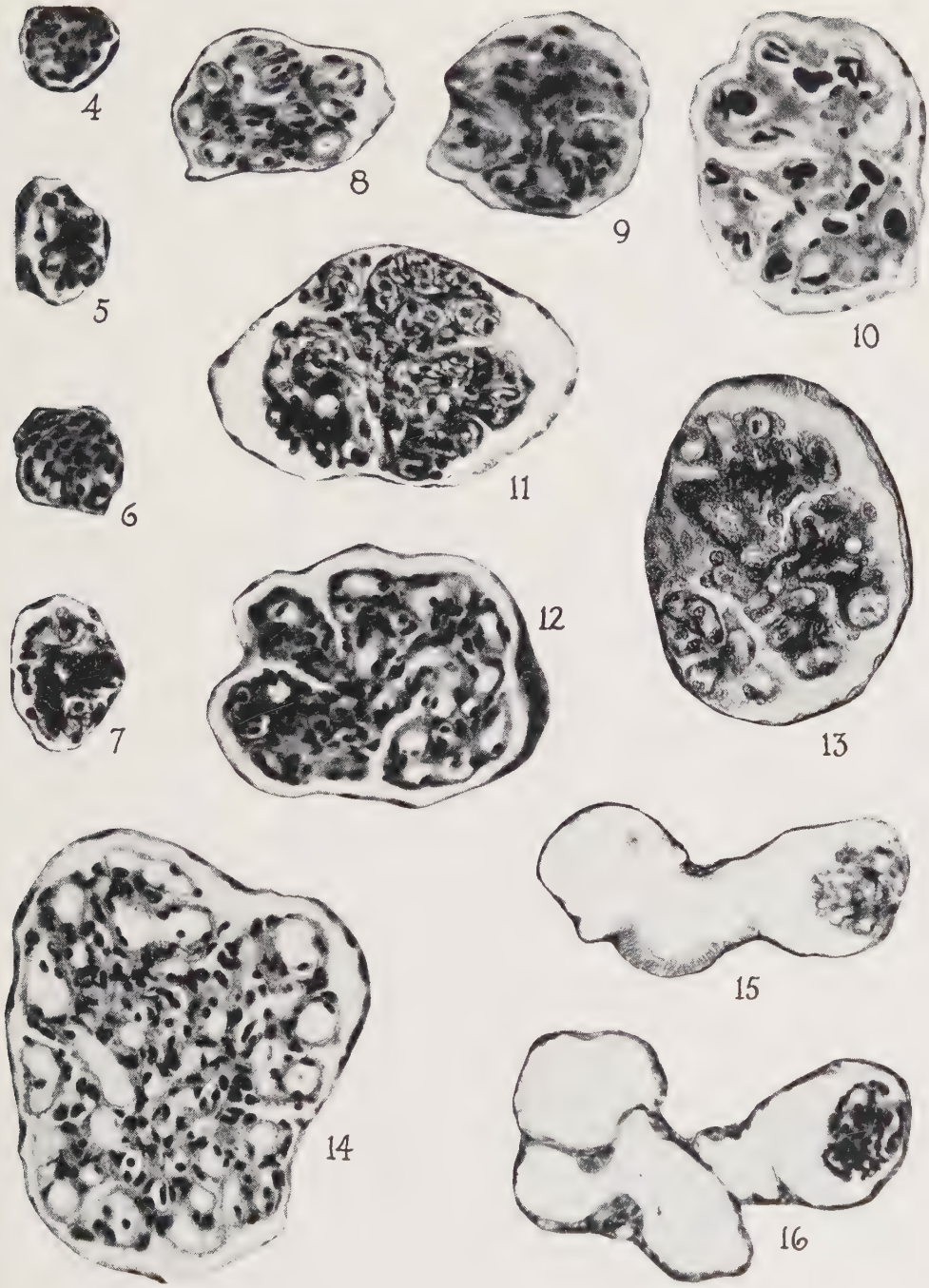
4
8
9
10
5
11
6
12
13
7
15
14
16

PLATE 2

EXPLANATION OF FIGURES

17 to 21 Longitudinal sections through the neck segment, to show some of the variations in the degree of ciliation encountered. Note particularly the abrupt transition to the epithelium of the first portion of the proximal convoluted segment in figures 19 and 21 (to the right). For further explanation see text.

22 Cross section of ciliated neck segment.

23 Longitudinal section of large ciliated neck segment, with unusually wide lumen. The lumen continues without obstruction into the first portion of the proximal convoluted segment.

24 Cross section of first portion of proximal convoluted segment.

25 Longitudinal section of first portion of proximal convoluted segment to show well-developed brush border.

26 Longitudinal section showing point of abrupt transition from the first to the second portion (below and to the right) of the proximal convoluted segment.

27 A similar abrupt transition from the first to the second portion (above) of the proximal convoluted segment.

28 Cross section of second portion of proximal convoluted segment. The microphotographs for figures 24 and 28 were made with the same filter, illumination, exposure and method of printing for direct comparison.

29 Documentary photograph for figure 3, oriented in the same manner. Nephron 1 can be seen entering from below, and the transition to the initial collecting segment is well shown to the left. The few cells of the initial collecting segment type, illustrated diagrammatically in figure 3 (above and to left of entrance of nephron 1) as intercalated between cells typical of the second portion of the proximal convoluted segment, are not well shown.

Figures 17 through 23, × 630; figures 24, 25 and 28, × 850; figures 26, 27 and 29, × 410. Figures 22, 27, 28, 29, fixation Zenker's; other figures, Bouin's. Figures 17, 21, Heidenhain-azan; figures 19, 20, 22, 25, iron hematoxylin and orange G; other figures, hematoxylin and eosin.

17
18
19
20
21
22
23
24
25
26
27
28
29

TWO RECONSTRUCTIONS EXPLAINING THE DEVELOPMENT OF THE VEINS OF THE LIVER

J. L. BREMER
Department of Anatomy, Harvard Medical School

TWO FIGURES

The figures usually found in the textbooks to explain the developmental changes that lead to the rearrangement of the large veins in relation with the fetal liver—the diagrams by Hochstetter and by Ingalls and even the beautiful drawings by Mall—lack a certain degree of clarity for the student, chiefly because they do not show enough of the general anatomy of the embryos in question, and therefore cannot stress sufficiently the advantages of the new courses of the vessels. The liver, as is well known, develops by invading the vitelline veins, giving rise to the liver cords and liver sinusoids, and later extends to and fuses with the body wall both ventrally and dorsally, allowing the anastomoses of the liver sinusoids with the umbilical and subcardinal veins respectively, thus offering more direct pathways for the blood to the heart through the liver. The present two reconstruction drawings, somewhat diagrammatic in certain details considered unimportant for their main purpose, are offered in the hope that they may be of some value in showing the directness of the new courses.

The first figure represents a median view of the left side of a pig embryo of 5.5 mm. The intestinal tract shows the pharynx, lung bud, stomach, hepatic diverticulum, and the intestinal loop connecting with the yolk stalk and continuing as the hind gut. Below the diaphragm it is represented as

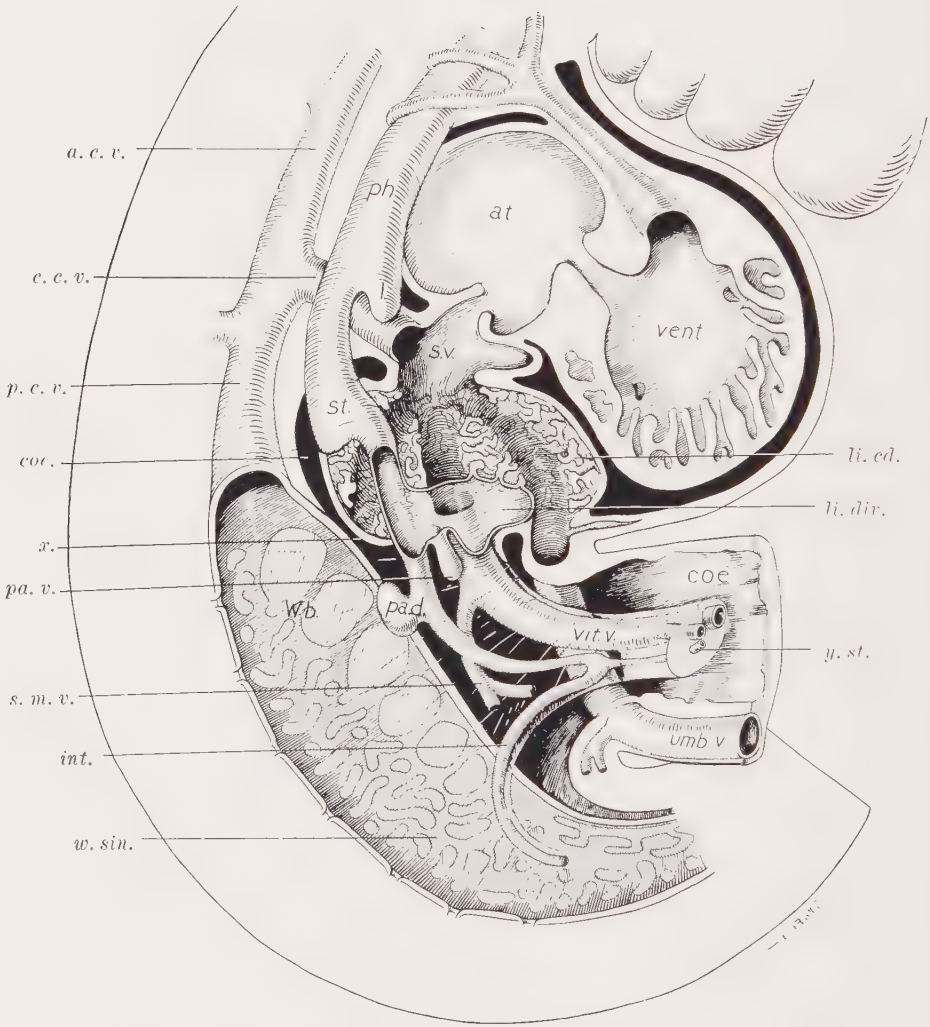

Fig. 1 Sagittal reconstruction of pig embryo of 5.5 mm., to show course of veins through the liver, and at 'x' future course of vena cava inferior on right side.

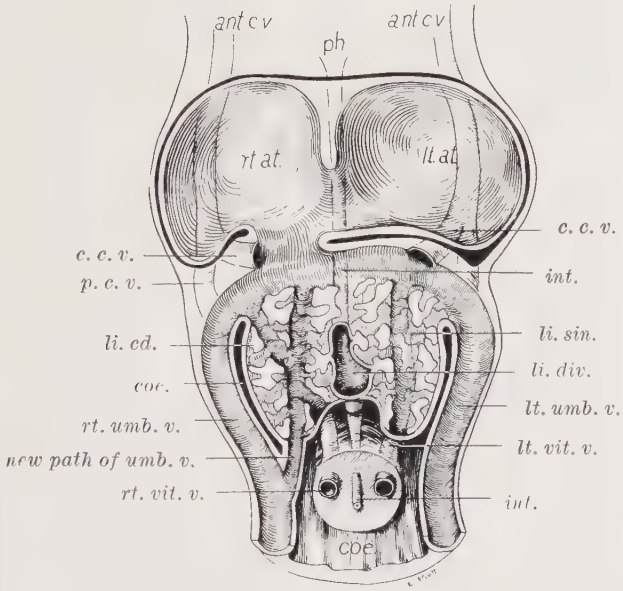

Fig. 2 Obliquely frontal reconstruction of pig embryo of 4.4 mm., to show connection of umbilical vein and liver sinusoids, present on right side, not yet on left.

ABBREVIATIONS FOR FIGURES

a. c. v., anterior cardinal vein
at., atrium
c. c. v., common cardinal vein
coe., coelom, body cavity
int., intestine
l., lung bud
li. cd., liver cord
li. div., hepatic diverticulum
li. sin., liver sinusoid
pa. d., dorsal pancreas
pa. v., ventral pancreas
p. c. v., posterior cardinal vein
ph., pharynx
s. m. v., superior mesenteric vein
st., stomach
s. v., sinus venosus
umb. v., umbilical vein
vent., ventricle
vit. v., vitelline vein
W. b., wolffian body (schematized)
w. sin., wolffian sinusoid
x., approximation of liver to dorsal wall
y. st., yolk stalk

covered by the mesentery or within the cavity of the umbilical cord, and accompanied by the left vitelline vein and its superior mesenteric branch. This vitelline system passes directly through the liver to the sinus venosus by a passage from which the liver cords have been swept aside. Ventrally the left umbilical vein runs from its position in the caudal wall of the umbilical cord, around the curved root of the cord, where it joins the body wall to the ventral tip of the expanded liver. Branches from this vein to the body wall prove that this circulation belongs to that structure. Its course through the liver is explained in the second figure.

The surface of the second reconstruction, from a pig embryo of 4.4 mm., is in an obliquely frontal plane roughly parallel with the main course of the umbilical vein as shown in figure 1, and extends from the umbilical cord to the atria of the heart. The intestinal tract is in the mid line and behind other structures, whereas the projecting liver diverticulum is shown as cut through and open. The two vitelline veins within the mesentery enter the liver and have made pathways between the liver cords to several openings into the sinus venosus, into which open also the two common cardinal veins and the two umbilical veins. On the right side the new anastomosis of the umbilical vein with the liver sinusoids is shown, and the advantage of the new route indicated.

In the first figure the wolffian body has been schematized to show the posterior cardinal vein dorsally and the subcardinal vein ventrally, the two interconnected by the mesonephric sinusoids. The dorsal lobe of the liver has grown into close proximity with the latter vein (at 'x'), and the future bridging of the abdominal cavity at this point with the consequent anastomosis of the vein and the liver sinusoids on the similar right side of the body can be readily visualized. In both right and left dorsal lobes the liver cords are sparse. The advantage of the new course, forming the upper portion of the vena cava inferior, is made obvious.

CHANGES IN THE ALIMENTARY CANAL OF URODELE LARVAE ASSOCIATED WITH AN EXCESS OR ABSENCE OF HYPOPHYSEAL TISSUE

NORMAN D. SCHOFIELD AND RAYMOND F. BLOUNT
Department of Anatomy, University of Minnesota

EIGHT FIGURES

INTRODUCTION

An altered digestive system may be a factor in the growth changes associated with pituitary disturbances. Modification of this system would give rise to metabolic changes in the organism and thus interfere with growth aside from any direct hormonal effects of the pituitary itself.

The literature upon the interrelationship between the digestive tract as a whole and the hypophysis is limited. Certain clinical observations such as those of Barker ('22) and Cushing and Davidoff ('27) and others have associated splanchnomegaly with acromegaly. Riddle and Flemion ('28) and Riddle and Nussmann ('33) relate the large pituitary of the female pigeon to her longer intestine. The general contraction of the gut with posterior lobe preparations is discussed by Melville and Stehle ('34 a and b).

The pharmacological action of pituitary extracts upon the individual structural elements of the gut is better known. Waddell ('16), Macht ('26) and others have described the stimulation of smooth muscle of the canal. Selective vasoconstriction of splanchnic vessels has been reported by Clark ('30) and Holtz ('32). Alterations in the physiological activity of the intestine as indicated by reduced absorption after injections of posterior lobe extract is reported by Thienes and Hockett ('30, '31).

The above experimental work has certain disadvantages. The extracts may not be satisfactory, and a constant hormone level cannot be maintained by injection or feeding since at the time of administration there is a sharp rise followed by a gradual decrease. All of the above work has been done upon the adult as these methods are not applicable to the study of pituitary effects during developmental stages. At older ages many organ systems may well have reached a point beyond which the effects of the hypophysis on their development cannot be demonstrated, as recently emphasized by Smith and Engle ('34).

The general effect of the pituitary upon the alimentary canal can be shown best where an excess or absence of its secretion has persisted throughout the formative period. These conditions may be obtained in the amphibian. Absence is satisfactorily accomplished by extirpation as first described by Adler ('14), Allen ('16) and Smith ('16). Animals with extra pituitary tissue may be produced by the transplantation of additional anlagen in the embryo (Blount, '32). In these two types of animals the altered pituitary relationship is indicated by pigment response and by vasoconstriction or dilation (Blount, '32, '33 a, '35 b). The present study has been on animals in which the alimentary canals have differentiated and functioned under the influence of pituitary absence or excess. An abstract of results was reported earlier (Schofield and Blount, '34).

The authors wish to express their appreciation of the suggestions and criticism given by Dr. A. T. Rasmussen.

MATERIALS AND METHODS

The alimentary canal of Ambystoma maculatum (Amblystoma punctatum)[1] larvae with altered pituitary relationships was studied. The ablation, or the transplantation of additional pituitary anlagen, had been performed in the late tail

[1] This species has generally been called Amblystoma punctatum by the experimentalists but it seems best to call it Ambystoma maculatum as is done by the herpetologists who are primarily responsible for naming species.

bud stages (Harrison's stages 28 to 31) as previously described (Blount, '32). Each 'set' of animals consists of hypophysectomized donors (those from which the hypophysis was removed), the control animal (one with the normal amount of pituitary tissue) and the triple pituitary host (an animal with two additional pituitaries). Incomplete sets consisting of control and host or donor were also used. In all, seven hypophysectomized donors, twelve control animals and thirteen triple pituitary hosts were studied in detail. Twenty-five living animals were also observed less thoroughly. During early life the ventral body wall is semitransparent, and the abdominal contents were observed microscopically on living animals under chlorotone anesthesia.

In the study it was necessary that certain landmarks in the alimentary canal be established. The opening of the esophagus from the mouth is not a definite anatomical point so the last branchial cleft was used. The alimentary canal has been considered to end at the midpoint of the external surface of the cloaca. Since the pyloric constriction is the only definite demarcation in the larval gut, it was used as a division point. All of the digestive tract cranial to the pylorus will be termed the 'upper gut' and the part caudal to it the 'lower gut.' With advance in age the cranial part of the lower gut becomes coiled.

Since variations in the amount of pituitary tissue result in marked alteration in total growth and body proportions (Blount, '33 b, '35 a and fig. 1), to make the measurements comparable it is necessary to give them in relative rather than numerical values. As there are fourteen myotomes between the pectoral and pelvic girdles of A. maculatum, the lengths of the parts of the digestive tract of the living animal have been reported in respect to the number of myotomes traversed.

Individuals were killed at various ages from beginning feeding to metamorphosis to obtain a representative series. Bouin's fluid was usually used followed by the paraffin technique. The animals were serially sectioned entire at 10 μ and stained with Mallory's triple connective tissue stain.

A quantitative study was made upon the sectioned animals. First the exact linear lengths of the various parts of the gut were determined by counting sections. The volume of the tissue of the alimentary canal wall and its component layers (mucosa, submucosa and muscularis) was determined by the paperweight method. For this, sections at equal intervals were projected onto paper and the outline drawings cut out and weighed. From the weight of the paper the area was

Fig. 1 A 'set' of Ambystoma late in larval life consisting of a) hypophysectomized donor, b) control animal, c) triple pituitary host. Magnification $\times 2\frac{1}{2}$. The small size of the test animals in comparison to the control, and the body proportion alterations are evident. The grafts on the side of the trunk in the host are visible at g. Further illustrations of this set of animals are shown in figures 5, 6, 7 and 8.

determined and the volume of the organ computed. The vascular plexuses lying between the outer longitudinal and inner circular layers of muscle were included with the submucosa. In finding the volume of the gut wall sections were taken at 100 μ intervals at a magnification of 75 diameters. For the percentage of each layer ten levels for each part of the gut were drawn at a magnification of 150. Since the animals are of different sizes a unit of comparison is necessary to make the measurements comparable. For the length of the gut the trunk length was used and for volumes the body volume was used as a standard. The latter was also determined by the paper cut-out method at a magnification of 25, using twenty-five levels for each individual.

Other methods employed will be considered later, including the determination of the absorptive areas of the gut, and the counts of the cellular elements in the muscularis.

RESULTS

Length determinations

Observations of alimentary canal length were made on both living and sectioned material. The work on the living animals was limited to larval individuals shortly after stage 46 which is the time of beginning feeding. This stage was advantageous because of the visibility of the gut although it showed the beginning but not the peak of the change. Length and diameter of the guts were taken. At this time the gastrointestinal tract is an S-shaped tube. The stomach lies anteriorly on the left and terminates in a well marked pyloric constriction. The intestine turns cranially and runs along the right side where it receives the bile and dorsal pancreatic ducts (Kingsbury, 1894; Bates, '04; Noble, '31). The ventral pancreatic duct enters farther on. After the entrance of these ducts the gut turns caudally and runs straight to the cloaca. Later in life coiling develops in this lower gut. The normal position of the tract at this time is shown schematically in figure 2 b.

In these studies of the living, due to differences in size of the test and control animals, the length of the canal is expressed in respect to the myotomes of the body. Since the esophagus and cranial end of the stomach are not visible, the

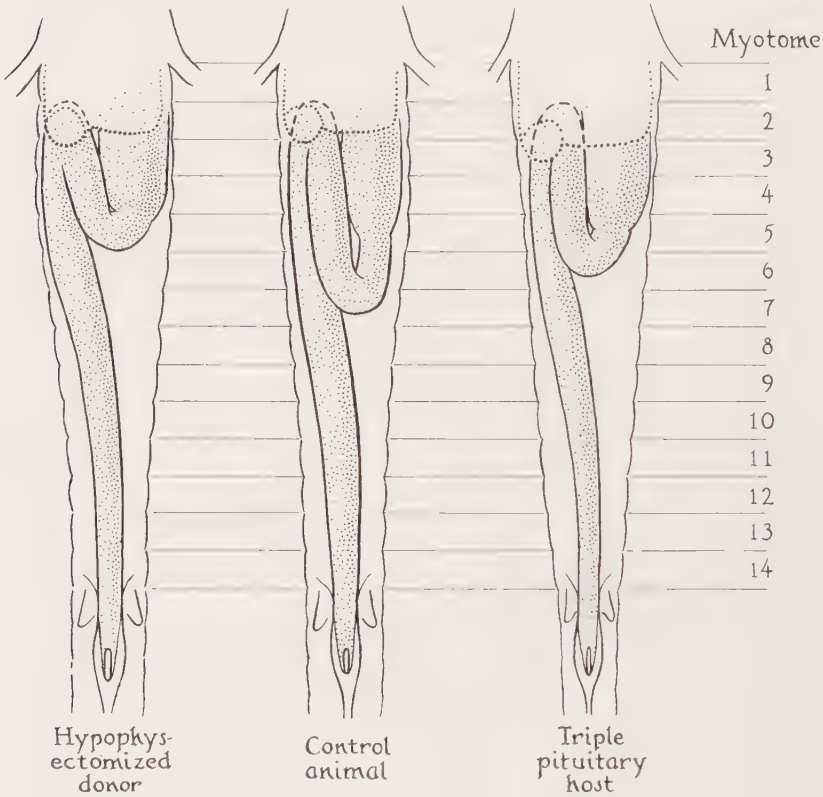

Fig. 2 Schematic representation of the gut length in twenty-five living animals just previous to feeding (stage 46), a) hypophysectomized donor, b) control animal, c) triple pituitary host. The trunk length is held constant and the fourteen myotomes are represented. The position and lengths of the gut are indicated. The length is related to the number of myotomes traversed as given in table 1.

number of myotomes traversed by the upper gut to the pyloric level, although not a measurement of upper gut length, forms a basis for comparison. In figure 2 the schema shows the altered guts of these animals when the trunk lengths are held constant, and a summary of alimentary canal lengths for

twenty-five living animals (seven hypophysectomized donors, ten control animals, and eight triple pituitary hosts) is given in table 1. The alimentary canal of the test animals is proportionally shorter than that of the controls. The diameter

TABLE 1

Gut length of the living animal at the end of embryonic life (stage 46) expressed in myotomes traversed. Averages for seven hypophysectomized donors, ten control animals, and eight triple pituitary hosts

	NUMBER OF MYOTOMES TRAVERSED		
	Hypophysectomized donors	Control animals	Triple pituitary hosts
Lower gut	4.1	4.6	4.4
Upper gut	17.8	20.7	19.0
Total gut	21.9	25.3	23.4

Fig. 3 Ventral view of a set (P1707) in midlarval life with body wall removed to show relative position, length, size and coiling of the alimentary canal. Magnification × 3. The arrow marks the division between the upper and lower gut at the pylorus. a) Hypophysectomized donor showing shorter gut with less coiling than normal, b) control animal with normal gut relationships, c) triple pituitary host showing extreme shortening, lack of coiling and small diameter.

of the gut in the triple pituitary host is definitely reduced in comparison to the control, but this dimension in the hypophysectomized individuals is not much changed.

The general alteration in the alimentary canal of the test animals in midlarval life can be seen in the photographs (fig. 3)

of dissected individuals. A reduction of gut length and the reduced coiling of the lower gut is shown by the hypophysectomized donor. A decrease in both length and diameter together with an absence of coiling is found in the triple pituitary host.

The length of the alimentary canal has been determined precisely from the serial sections of thirty-two animals (seven hypophysectomized donors, twelve control animals and thirteen triple pituitary hosts). The lengths for upper, lower and total gut, are recorded as averages in table 2. This is a

TABLE 2

Gut length of larval animals obtained from counting serial sections for seven hypophysectomized donors, twelve control animals and thirteen triple pituitary hosts

ANIMAL TYPE	TRUNK LENGTH	GUT PART	GUT LENGTH	TRUNK LENGTH	CHANGE
	mm.		*mm.*	%	%
Hypophysectomized donor	10.7	Upper gut	5.43	50.7	— 6.8
		Lower gut	8.99	84.1	— 21.3
		Total gut	14.42	134.8	— 16.4
Control animal	13.4	Upper gut	7.29	54.4	....
		Lower gut	14.30	106.7	....
		Total gut	21.59	161.1	....
Triple pituitary host	8.7	Upper gut	2.95	33.9	— 37.7
		Lower gut	6.44	74.1	— 30.6
		Total gut	9.39	108.0	— 33.0

heterogeneous group in respect to size and age, so the figures given do not represent any individuals but serve as a basis for comparison between groups.

The proportion of upper to lower gut has not changed much in the hypophysectomized animal since here as in the control the ratio is 34 to 64. However, it becomes 45 to 55 in the triple pituitary host. A graphic representation of the actual values of gut length is given in figure 4.

In order to make these figures comparable they are also expressed as a function of the trunk length of each individual and recorded as a percentage (table 2). By this method it

can be shown that there is a relatively greater reduction of both the upper and lower gut in the triple pituitary host as compared to the control than there is in the hypophysectomized donor. The reduction in the hypophysectomized individuals

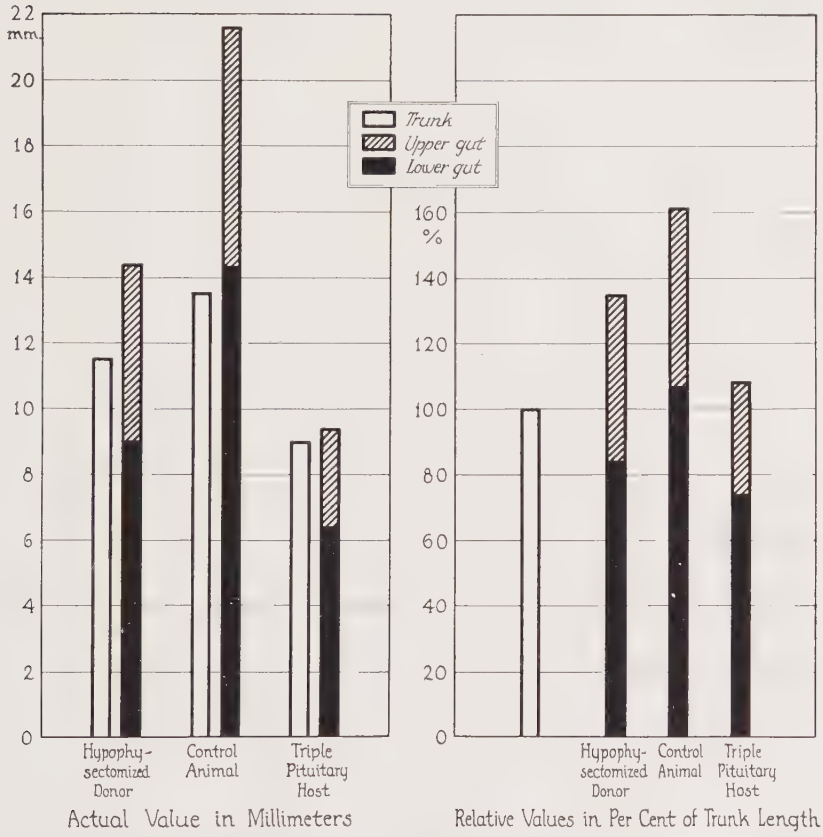

Fig. 4 Graphic representation of the lengths of the alimentary canal segments as secured from serial sections of thirty-two animals. First, the actual values are shown for trunk length and upper and lower gut. Second, the relative values are given in respect to trunk length which is held constant.

is most marked in the lower gut. These changes are graphically shown in figure 4.

In this heterogeneous group a clearer means of comparison is the difference from the control which has been determined

for each individual as a percentage change. By this each animal is compared directly with its own individual control. The averages of these found in table 2 show a consistent loss in length in all parts of the gastrointestinal tract in the test animals. The percentage difference of total gut is a minus 16% in the donor and a minus 33% for the host.

TABLE 3

Volumes of the component layers of the gut wall for the upper, lower and total gut based upon seven hypophysectomized donors, twelve control animals and thirteen triple pituitary hosts

ANIMAL TYPE	BODY VOLUME	GUT WALL COMPONENTS	VOLUME, CU.MM.			PER CENT BODY VOLUME			PER CENT DIFFERENCE FROM CONTROL		
			U.G.	L.G.	T.G.	U.G.	L.G.	T.G.	U.G.	L.G.	T.G.
	cu.mm.										
Hypophysectomized donor	109	Mucosa	0.64	1.49	2.13	0.59	1.32	1.91	—40	—19	—20
		Submucosa	0.75	0.32	1.07	0.71	0.33	1.03	—48	+ 6	—38
		Muscularis	0.23	0.19	0.42	0.21	0.19	0.40	—55	—25	—45
		Total	1.62	2.01	3.63	1.51	1.84	3.34	—46	—16	—33
Control animal	201	Mucosa	1.97	3.26	5.22	0.98	1.62	2.60	....	....	....
		Submucosa	2.73	0.62	3.34	1.36	0.31	1.66	....	....	....
		Muscularis	0.95	0.51	1.45	0.47	0.25	0.72	....	....	....
		Total	5.64	4.38	10.02	2.80	2.18	4.98	....	....	....
Triple pituitary host	47	Mucosa	0.34	0.55	0.89	0.73	1.16	1.89	—26	—28	—27
		Submucosa	0.43	0.15	0.58	0.92	0.32	1.24	—32	+ 4	—26
		Muscularis	0.28	0.15	0.42	0.59	0.31	0.90	+23	+24	+24
		Total	1.05	0.84	1.89	2.24	1.79	4.03	—31	18	—20

Volume determinations

A simple measurement of length could not show the diverse changes in the alimentary canal of animals with altered amounts of hypophyseal tissue which would be apparent in a volumetric determination of its mass.

Volume of the entire gut wall. The volume of the wall of the gastrointestinal tract was determined for the thirty-two individuals. The lumen was not taken into consideration. The average gut volumes of all of the animals is given in table 3. Here again the figures have value only as a medium of comparison.

There is a much slower increase in gut mass in the test animals than in the controls. On an average the control gut wall has an actual volume two and one-half times that of the donor and five times that of the host.

The disparity in size of control and test animals makes a comparison of actual volumes misleading. To avoid this the volume has been expressed as a percentage of body volume. Seen in this way the total alimentary canal volume is 5% of the body volume in the control, 3.3% in the donors, and 4% in the host although the length here is less than in the donors. When the gut is divided into an upper and lower segment the hypophysectomized donor has a gut volume cranial to the pylorus equal to 1.5% of its body volume and caudal to this region a volume equal to 1.8% of body volume. Corresponding figures for the control are 2.8 and 2.2%; while the host animal has an upper gut which is 2.2% and a lower gut 1.8% of the body volume. Expressed as a percentage of change from the control, the hypophysectomized donor has lost 35% in the upper, 31% in the lower gut with an average of 33%; these losses in the triple pituitary host are 31, 18 and 20, respectively.

A graphic representation of these changes for a representative set (P664) is seen in figure 6. Here the control gut volume is 10.4 cu.mm. while that of the hypophysectomized donor is 4.4 and that of the triple pituitary host 1.0.

Volume of layers of gut wall. An analysis of the volumes of the component layers of the gut wall makes the changes undergone in the test animals somewhat clearer. The arrangement of the mucosa, submucosa and muscularis in typical cross sections may be seen in figure 5. The percentage of the total gut volume contributed by the separate layers is given in table 4. The most obvious difference is a relative increase of muscularis in the host group. This increase is most marked in the upper gut where the muscular layer is normally thickest. However, an increase of 55% in both gut segments indicates a generalized increase of muscle volume.

These changes are seen in figure 6 which was constructed from the data obtained from the set P664. The total volume

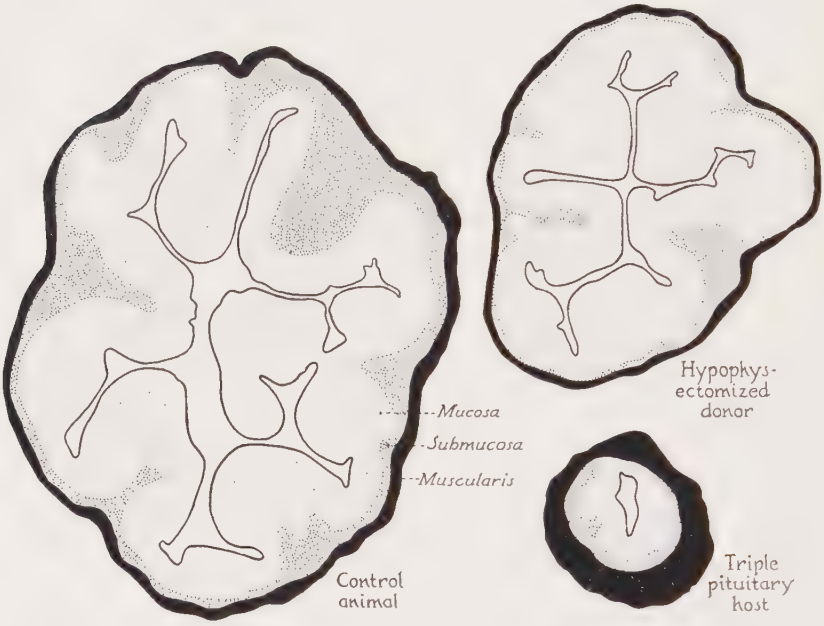

Fig. 5 Cross sections of lower gut at comparable levels of 'set' P664 showing the arrangement and proportions of the component layers of the gut wall. The increase in the muscularis in the host is the most striking change while the decrease of this layer in the donor is somewhat less apparent.

TABLE 4

The layers of the gut wall expressed as percentages of the volume of the gut wall for seven hypophysectomized, twelve control animals, and thirteen triple pituitary hosts

ANIMAL TYPE	COMPONENT LAYERS AS PERCENTAGES OF TOTAL WALL VOLUME OF THE SEGMENTS								
	Mucosa			Submucosa			Muscularis		
	U.G.	L.G.	T.G.	U.G.	L.G.	T.G.	U.G.	L.G.	T.G.
Hypophys-ectomized donor	39.7	74.2	58.9	46.3	16.2	29.6	13.9	9.6	11.5
Control animal	34.9	74.4	52.2	48.3	14.1	33.2	16.7	11.5	14.6
Triple pituitary host	32.4	64.8	47.1	41.4	17.7	30.7	26.1	17.5	22.2

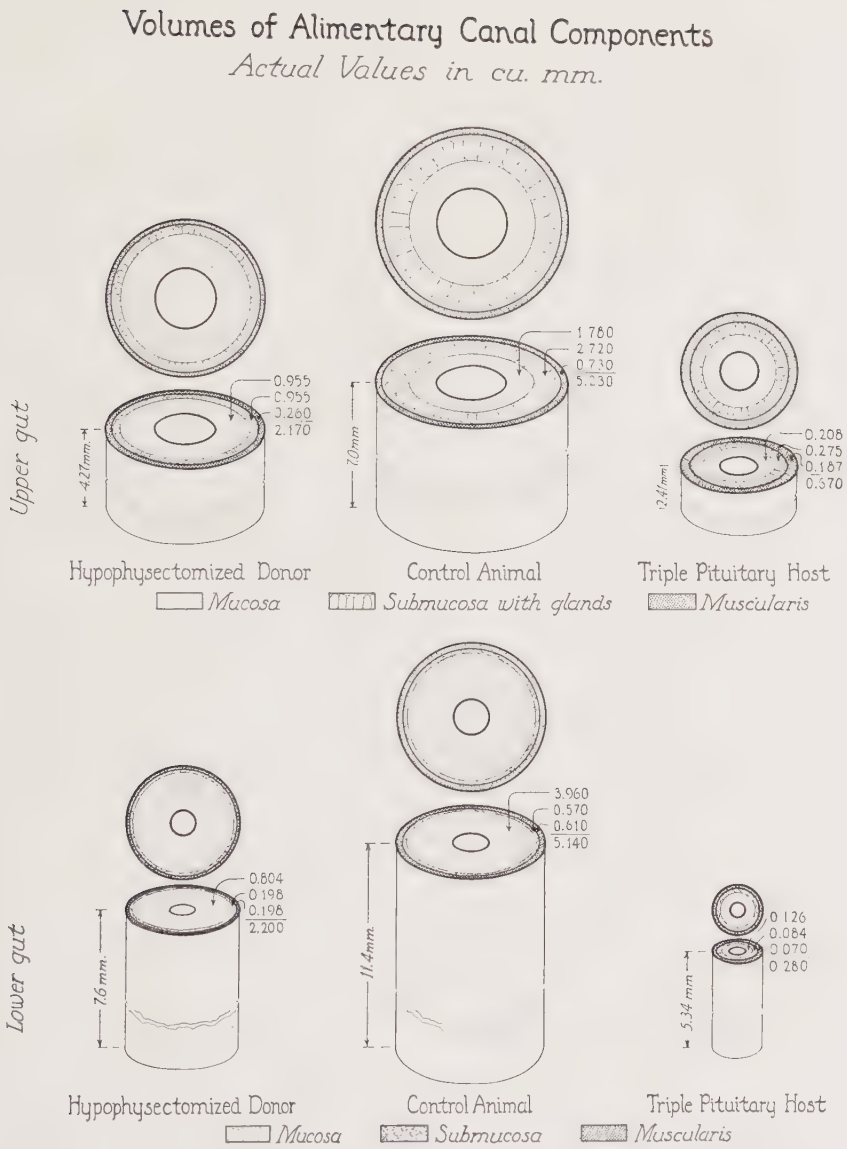

Fig. 6 Graphic representation of actual volumes of the component layers of the gut wall of set P664 in cubic millimeters. These are first shown for the upper gut and then for the lower. The lengths are the actual lengths, and the circumferences of the gut lumina (absorptive surface, here circles) are in proportion; then the thicknesses are such as to give the correct volumes of the layers. The reduced total volumes of the hypophysectomized donor and the extreme small size of the triple pituitary host's gut are shown. There is no significant change in the mucosa and submucosa. The heavy muscular coat of the triple pituitary host and the slight reduction in the donor may be seen.

of the upper gut wall of the control is 5.23 sq.mm. while in the hypophysectomized donor it is 2.17 and in the triple pituitary host only 0.67. The muscular coat, however, is not in this proportion but 0.73, 0.26 and 0.19, respectively, which indicates a loss in the hypophysectomized donor and an increase in the triple pituitary host. Similar changes are seen in the lower gut.

The volumes of the wall components are expressed as a function of body volume (table 3). The volume of the muscularis is in the control 0.7%, in the hypophysectomized donor 0.4% and in the triple pituitary host 0.9% of the body volume. The total gut volumes were 5.0, 3.5 and 4.0%, respectively. The relative amount of muscularis in the upper gut is 0.47, 0.21 and 0.56% and in the lower gut 0.23, 0.19 and 0.34%, respectively. Here again it is seen that the greatest increase is in the upper gut where the muscle mass is normally greatest and the greatest decrease in the hypophysectomized donor is also here. In general the mucosa and submucosa follow the general trend of reduction in the test animals except in the lower gut of the triple pituitary hosts where a slight edema of the submucosa in older animals increases the volume somewhat. This is an apparent rather than a real change. The percentage change in the muscularis given in table 3 shows the striking volume decrease of 45% in the hypophysectomized donor in contrast to an increase of 24% in the triple pituitary host.

The example shown in figure 7 (set P664) reflects this general trend. The differences between the test and control animals are made more obvious by holding body volume constant. Here again the most striking change is the muscular hypoplasia in the hypophysectomized donor and the marked hyperplasia in the triple pituitary host. These changes are evident in both upper and lower gut to the same degree.

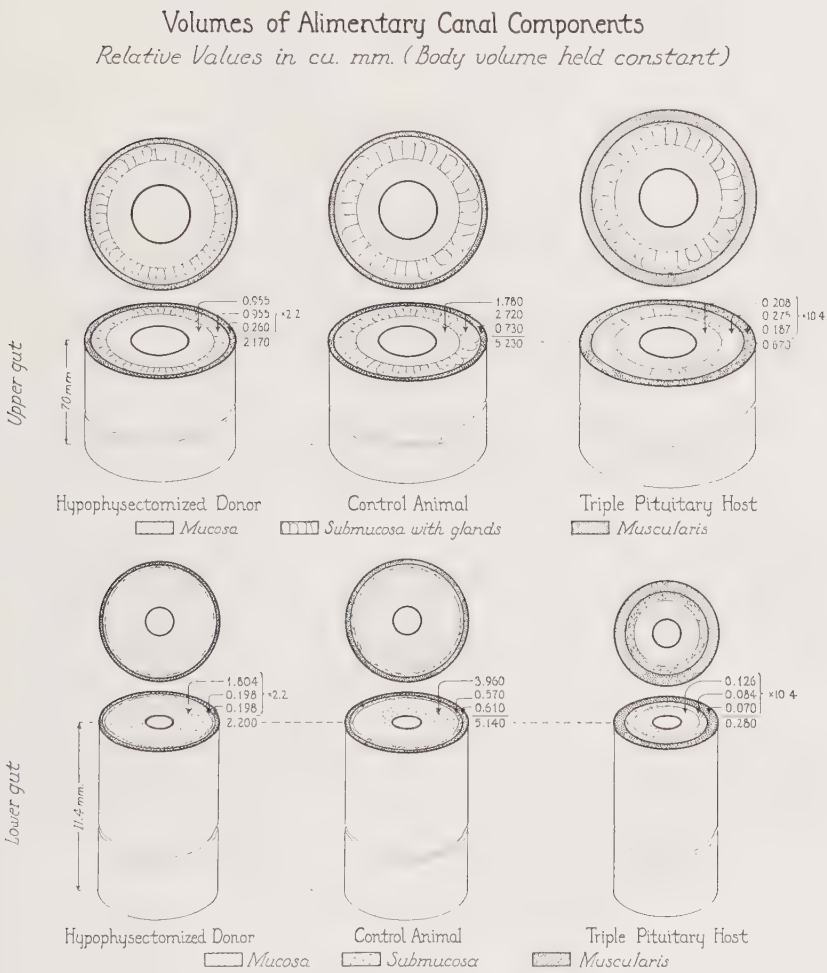

Fig. 7 Graphic representation of the relative volumes of the component layers of the gut as for figure 6. Here, however, the lengths and lumina are held constant at the control values. The figures for the volumes of the test animals are multiplied by a factor (donor — 2.2; host — 10.4) to make these comparable to the control body volume. Here the muscular hyperplasia in the host and the hypoplasia in the donor are best illustrated.

Muscularis

The striking differences in the muscular coats of the test and control animals are well seen in the photomicrographs of figure 8. The increase in muscularis in the host animal could be due to a hypertrophy or a hyperplasia. However,

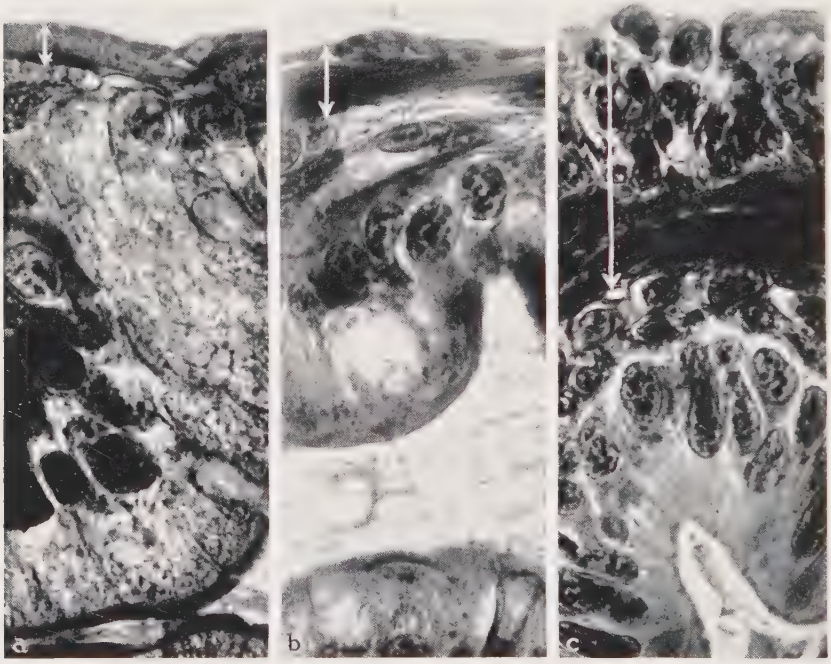

Fig. 8 Sections of comparable levels of the lower gut in set P664. The arrows indicate muscular coats. Photomicrograph × 540. For fiber count ratios see page 185. a) Hypophysectomized donor. Shows reduction in muscularis. b) Control animal. The normal number of muscle fibers is shown. c) Triple pituitary host. The increase of gut musculature is apparent.

there was the possibility of an apparent change due to contraction or relaxation and to size differences. To check the hyperplasia cell counts were made. Five equally spaced levels in the lower gut were used. The extreme folding of the mucosa in the upper gut with the resulting oblique sectioning of the epithelial cells complicates greatly any attempt at cell counting in this region. Nuclei were counted in the circular

and longitudinal muscle layers. Because of varying degrees of distention, the number of epithelial cells lining the lumen of the section were used as the standard for comparison. Johnson ('12) has shown that cell number in the lining epithelium is relatively constant with distension. These counts are found in table 5. The ratio of the muscle cell nuclei to the epithelial cell nuclei is, in the control animal 0.53 to 1, in the hypophysectomized donor 0.49 to 1, while in the triple pituitary host they are 2.1 to 1. This, associated with the

TABLE 5

Muscle fiber number (nuclear counts) in respect to the cells of the mucosa, for five sets of animals

ANIMAL TYPE	NUCLEAR NUMBER			NUCLEAR RATIOS		
	Cir. mus.	Long. mus.	Inner. epith.	Epith. to Cir. M.	Epith. to Long. M.	Epith. to Total M.
Hypophysectomized donor	29	20	100	0.290	0.200	0.490
Control animal	72	40	208	0.346	0.192	0.538
Triple pituitary host	69	39	50	1.380	0.780	2.160

relative volume change, shows a slight hypoplasia of muscularis in the donor in contrast to a marked hyperplasia of the host.

Absorptive area

It may be assumed that with maximal feeding the amount of food assimilated by an animal will depend in part upon the available area offered by the gut for absorption. The determination of the relative absorptive areas available in the lower gut was made. The perimeter of the lumen of the lower gut at five levels was made by measurement of sections drawn at a magnification of 300. The average perimeter was multiplied by the length of the gut and thus an approximation of

area was obtained. This was found for seven 'sets' of animals. For a comparison this is expressed as square millimeters of surface per cubic millimeter of body volume. The control has 0.273 sq.mm. of gut surface for every cubic millimeter of body volume. This figure is 0.230 in the hypophysectomized donor and 0.170 in the triple pituitary host. The range varies from 0.408 in a rapidly growing young control to 0.074 sq.mm. in a slowly growing relatively old and extreme triple pituitary host. That the absorptive area is apparently correlated with retarded growth is shown by normal animals just before metamorphosis when the rate of growth is very slow. An example of this is P611C where body volume is 345 cu.mm. and the absorptive area is 0.190 sq.mm.

DISCUSSION

A change in the amount of hypophyseal tissue sustained by an Ambystoma larva is reflected in the alimentary canal as a decrease in length and in tissue volume.

This is the cumulative effect of a variety of factors among which are a general hormonal growth effect, a specific hormonal influence on some of the tissue elements of the gut, and vascular alterations.

The time when hypophyseal function is established must be considered in any exposition of changes associated with this gland. All components of the pituitary body do not become active simultaneously. This has been shown for the mammal by the work of McCord ('15), Maurer and Lewis ('22), Rumph and Smith ('26), Snyder ('28), Smith and Dortzbach ('29), Nelson ('30), and Smith and MacDowell ('30). In the Ambystoma the situation is the same as in the mammal. We have (Blount, '32) found, in test animals, pigmentation changes at stage 41, a definite constriction of capillaries by stage 43 (Blount, '33 a, '35 b) and still later growth retardation (Blount, '33 b, '35 a). Here then, physiological indications of progressively increasing function of the posterior lobe are observable before indications of anterior lobe activity are apparent. Posterior lobe function is established in the Am-

bystoma embryo early in the differentiation of the gut. Although the pancreas may contain fuchsinophil granules at stage 40 (Dorris, '35) the alimentary canal in general is still a yolk mass. The yolk is not lost until stage 46 when feeding begins. In these experiments a constant marked hyperpituitarism or a pituitariless state is maintained during the tender age of gut differentiation and rapid growth, which is the time of greatest vulnerability (Jansen, '21) to any extrinsic stimulus.

A more general hormonal effect of the hypophysis is best seen in the hypophysectomized donor. Smith ('20) and Smith and Engle ('34), refer to a slowing of growth of such individuals as being due to the loss of a 'growth-maintaining' factor, in distinction to one of 'growth stimulation.' This is a factor in altering the length of the alimentary canal, especially caudal to the pyloric sphincter, so that it falls behind that of the control both relatively and actually. The converse of this is seen in the pigeons studied by Riddle and Flemion ('28) and Riddle and Nussmann ('33), where hypertrophy of the pars anterior is accompanied by increase in intestinal length. Cushing and Davidoff ('27) and Trendelenberg ('29) find a similar splanchnomegaly in acromegaly. This has been produced experimentally in dogs by Putnam, Benedict and Teel ('29). In our donors there is also a decrease of 33% in respect to the control in the tissue volume of the gut wall.

One of the more specific effects of the hypophysis on the alimentary canal is its effect on the muscular coat. This is best seen in the host where a marked muscular hyperplasia is evident. The converse or hypoplasia is seen in the hypophysectomized donors. Cushing and Davidoff ('27) found an increase of this layer in the lower gut of the acromegalic. The muscularis change in the host does not follow, and somewhat masks, the general trend of reduction in the gut tissue. The relative and actual decrease in length of the gastrointestinal tract is in part due to a chronically contractive state. This thickening is not due to a metamorphic change, as described for the frog by Janes ('34) and others, precociously

produced by the experiment since no accompanying changes are present. The relationship of the continuous contraction to the hyperplasia of the muscularis is not clear. The work concerning the effect of posterior lobe preparations on smooth muscle (Waddell, '16; Macht, '26; Krogh, '28; Clark, '30; Holtz, '32) shows a direct stimulation but no mention of specific cellular changes is made. This result suggests that the question of hyperplasia of striated muscle with activity might best be studied in differentiating tissue.

A more generalized effect of hypophyseal alteration on the gastrointestinal tract is through the vascular system. In hypophysectomy, owing to vasodilation, and in multiple pituitary animals, owing to vasoconstriction, the minute flow of blood through any organ is reduced. This anemia, while not severe enough to produce changes in adult tissues could be a factor in an embryonic tissue where cell activity approaches a maximum. Clark ('30) and Holtz ('32) demonstrate a selective vasoconstrictive action of posterior lobe preparation, with the splancnic vessels contracting more strongly than vessels in other areas. This reduction in blood supply in our animals is in effect during differentiation of the gut and becomes progressively more acute as this system goes on in development.

The hypoplasia of the gut in the test animals may be a factor in the general nutrition. The available area for absorption in the lower gut of a young rapidly growing control animal is 0.408 sq.mm. for each cubic millimeter of body volume (P362C). This area in an advanced and stunted host may fall to 0.074 sq.mm. (P664TP). The donor does not show as great a reduction as the host, 0.174 sq.mm. being found in P664E P per unit volume. While we do not know the extent of intestinal reduction comfortably sustained by an Ambystoma, a loss of 75% certainly has significance.

In the host animal any unfavorable effect due to intestinal hypoplasia is further aggravated by the ever-present excess of posterior lobe hormones. Thienes and Hockett ('30, '31) have demonstrated a reduced absorption from the intestine

of many types of substances in the presence of posterior lobe preparations. Even if the hypoplasia in itself were not critical, the intestinal hypoplasia abetted by a local anemia with the resulting reduced absorptive rate is distressing.

CONCLUSIONS

1. An absence or an excess amount of pituitary tissue in Ambystoma larvae causes a reduction in the length of the alimentary canal and in the volume of its wall.

2. In the hypophysectomized animal the reduction in the volume of the alimentary canal is largely due to the retarded growth in length.

3. In the triple pituitary animal the reduction in length of the alimentary canal is due to general reduced growth of this structure and also to the contractile state caused by the excess posterior lobe hormone.

4. The muscular coat in the alimentary canal in the triple pituitary animal is hypertrophied. It is suggested that this may be the result of continuous activity of the muscle cells produced by excess posterior lobe extract. Cell counts show a hyperplasia. This change masks to some extent the reduced growth of this structure.

5. From the data available a slight reduction in the muscularis of the hypophysectomized animal is seen.

6. The absorptive area of the intestine is reduced in both hypophysectomized and triple pituitary animals.

7. In the triple pituitary animal the posterior lobe hormones may further inhibit absorption from the intestine.

8. The reduction in relative absorptive area in the intestine of the Ambystoma larva is associated with a diminution of growth. This is followed in the hypophysectomized donor and more especially in the triple pituitary host and also becomes apparent in the control animal in the period just before metamorphosis.

LITERATURE CITED

ADLER, L. 1914 Metamorphosenstudien an Batrachierlarven. I. Extirpation endokriner Drüsen. A. Extirpation der Hypophyse. Arch. f. Entwmech., Bd. 39, S. 21–45.

ALLEN, B. M. 1916 The results of extirpation of the anterior lobe of the hypophysis and of the thyroid of Rana pipiens larvae. Science, N.S., vol. 44, pp. 755–757.

BARKER, L. F. 1922 Endocrinology and Metabolism, vol. 2. Appleton Company.

BATES, G. A. 1904 The histology of the digestive tract of Amblystoma punctatum. Tufts College Studies, no. 8, pp. 411–435.

BLOUNT, R. F. 1932 Transplantation and extirpation of the pituitary rudiment and the effects upon pigmentation in the urodele embryo. J. Exp. Zoöl., vol. 63, pp. 113–141.

——— 1933 a The circulatory system of urodele larvae as altered by pituitary rudiment implants. Anat. Rec., vol. 55, supplement, p. 7.

——— 1933 b Total growth proportions as influenced by pituitary rudiment implantation and extirpation in urodele embryos. Anat. Rec., vol. 55, supplement, p. 46.

——— 1935 a Size relationships as influenced by pituitary rudiment implantation and extirpation in the urodele embryo. J. Exp. Zoöl., vol. 70, pp. 131–185.

——— 1935 b The influence of additional pituitary anlagen upon the circulatory system of the developing urodele. A condition paralleling hypertension in the mammal. J. Exp. Zoöl., vol. 71, pp. 421–448.

CLARK, G. A. 1930 The selective vaso-constrictor action of pituitary pressor extract. Am. J. Physiol., vol. 70, pp. 53–59.

CUSHING, H. AND L. M. DAVIDOFF 1927 The pathological findings in four autopsied cases of acromegaly with a discussion of their significance. Monograph of the Rockefeller Institute for Medical Research, no. 22.

DORRIS, FRANCES 1935 The development of structure and function in the digestive tract of Amblystoma punctatum. J. Exp. Zoöl., vol. 70, pp. 491–527.

HOLTZ, P. 1932 The action of the pituitary posterior lobe extracts on different parts of the circulatory system. J. Physiol., vol. 76, pp. 149–169.

JANES, RALPH GORDON 1934 Studies on the amphibian digestive system. I. Histological changes in the alimentary tract of anuran larvae during involution. J. Exp. Zoöl., vol. 67, pp. 73–88.

JANSEN, MURK 1921 Feebleness of growth and congenital dwarfism. Oxford Medical Publications.

JOHNSON, F. P. 1912 The effects of distention of the intestine upon the shape of the villi and glands. Am. J. Anat., vol. 14, pp. 235–250.

KINGSBURY, B. F. 1894 The histological structure of the enteron of Necturus maculatus. Proc. Am. Mic. Soc., vol. 16, pp. 19–65.

KROGH, AUGUST 1928 The anatomy and physiology of capillaries. Yale University Press.

MACHT, D. 1926 Concerning the point of attack of pituitary extract and histamine on smooth muscle. J. Phar. Exp. Ther., vol. 27, pp. 389–393.

MAURER, C. AND D. LEWIS 1922 The structure and differentiation of the specific cellular elements of the pars intermedia of the hypophysis of the domestic pig. J. Exp. Med., vol. 36, pp. 141–156 .

MCCORD, C. P. 1915 The occurrence of pituitrin and epinephrine in the foetal pituitary and suprarenal glands. J. Biol. Chem., vol. 23, pp. 435–437.

MELVILLE, K. I. AND R. L. STEHLE 1934 a The actions of pituitary preparations (posterior lobe) upon the intestines of the dog. J. Phar. Exp. Ther., vol. 50, pp. 165–173.

——— 1934 b The actions of pituitary preparations (posterior lobe) upon the intestines of the rabbit. J. Phar. Exp. Ther., vol. 50, pp. 174–179.

NELSON, W. O. 1930 Histology of the anterior pituitary of the foetal pig with reference to growth and maturity. Proc. Soc. Exp. Biol. Med., vol. 27, pp. 596–597.

NOBLE, G. K. 1931 The biology of Amphibia. McGraw-Hill Book Co.

PUTNAM, T. J., E. B. BENEDICT AND H. M. TEEL 1929 Studies in acromegaly. VIII. Experimental canine acromegaly produced by injection of anterior lobe pituitary extract. Arch. Surgery, vol. 18, pp. 1708–1736.

RIDDLE, O. AND F. FLEMION 1928 A sex difference in intestinal length and its relation to pituitary size. Endocrinology, vol. 12, pp. 203–208.

RIDDLE, O. AND T. C. NUSSMANN 1933 A sex difference in pituitary size and intestinal length in doves and pigeons. Anat. Rec., vol. 57, pp. 197–204.

RUMPH, PAUL AND P. E. SMITH 1926 The first occurrence of secretory products of a specific structural differentiation in the thyroid and anterior pituitary during the development of the pig fetus. Anat. Rec., vol. 33, pp. 289–298.

SCHOFIELD, NORMAN D. AND RAYMOND F. BLOUNT 1934 The relationship between the pituitary and the alimentary canal in urodele larvae with increased or decreased pituitary tissue. Anat. Rec., vol. 58, no. 4, supplement, p. 85.

SMITH, P. E. 1916 The effects of hypophysectomy upon the subsequent growth and development of Rana boylei. Anat. Rec., vol. 11, pp. 57–64.

——— 1920 The pigmentation, growth and endocrine disturbances induced in the anuran tadpole by early ablation of the pars buccalis of the hypophysis. Am. Anat. Mem., no. 11.

SMITH, P. E. AND CARL DORTZBACH 1929 The first appearance in the anterior pituitary of the developing pig foetus of detectable amounts of the hormones stimulating ovarian maturity and general body growth. Anat. Rec., vol. 43, pp. 277–298.

SMITH, P. E. AND E. T. ENGLE 1934 The gonad-stimulating hormones from the pituitary and from human urine. J. Pediatrics, vol. 5, pp. 163–176.

SMITH, P. E. AND E. C. MACDOWELL 1930 An hereditary anterior-pituitary deficiency in the mouse. Anat. Rec., vol. 46, pp. 249–257.

SNYDER, FRANKLIN P. 1928 The presence of melanophore expanding substance in the pituitary body of early pig embryos. Am. J. Anat., vol. 41, pp. 399–409.

THIENES, C. H. AND A. J. HOCKETT 1930 The effects of pituitary extract upon the absorption of glucose and iodide. Proc. Soc. Exp. Biol. Med., vol. 27, pp. 501–502.

——— 1931 Decreased absorption from the alimentary tract following injections of posterior pituitary extract. J. Lab. and Clinical Med., vol. 16, pp. 843–849.

TRENDELENBURG, P. 1929 Die Hormone, vol. 1. Julius Springer, Berlin.

WADDELL, J. A. 1916 Pituitary extract: effect on frog's esophagus. Am. J. Physiol., vol. 41, pp. 529–534.

THE DEVELOPMENT OF THE PARS INTESTINALIS OF THE COMMON BILE DUCT IN THE HUMAN FETUS, WITH SPECIAL REFERENCE TO THE ORIGIN OF THE AMPULLA OF VATER AND THE SPHINCTER OF ODDI

III. THE COMPOSITION OF THE MUSCULUS PROPRIUS

R. A. SCHWEGLER, JR. AND E. A. BOYDEN
Departments of Obstetrics and Anatomy, University of Minnesota

NINE TEXT FIGURES AND FOUR PLATES (TWELVE FIGURES)

Two phases of development have already been discussed in this series of articles: first, the involution of the ampulla of Vater; second, the relation of this process to the development of a musculus proprius. It is now possible to consider the fetal pattern of Oddi's muscle and to relate this new information to what is known about the histology of the sphincter in the adult.

PREVIOUS CONCEPTIONS OF THE ADULT SPHINCTER

It is perhaps well to point out first that the significance of Oddi's studies of 1887–1888 rests not so much upon his anatomical description of Glisson's sphincter as upon his physiological interpretation of it; for Gage (1879) had already described 'special sphincters' around the ducts and ampulla of the cat; and Oddi seems to have known very little about the anatomy of the human sphincter.[1] To be sure, he mentions

[1] It will be recalled that Oddi was the first to measure the resistance of this muscle in animals and to show that removal of the gall bladder resulted in marked dilatation of the ducts. Thus he was led to attribute to the sphincter the function of retaining the bile; Glisson had postulated that it prevented regurgitation of intestinal contents. Dilation of the sphincter he considered due either to reflex or mechanical action; dysfunction of the muscle was believed to result in such morbid affections as spastic icterus and catarrhal jaundice. As a result of this work he was subsequently appointed director of the Physiological Laboratory at Genoa.

having extended his primary observations on the sheep and dog to man and other mammals and notes that "one does not encounter an arrangement [in these other species] identical to that which I have described," but he seems not to have grasped the significant differences between man and certain domestic mammals. Thus he writes, "I have always been able to verify [in other species] an arrangement which approximates that which I have named as typical and which is proper . . . . to the dog and to the sheep."

Accordingly one must look elsewhere for the first histological description of the human sphincter—namely, to the inaugural dissertation of v. Znaniecki.[2] According to Soulié, Znaniecki made two important observations: first, that the smooth muscle fibers of the intestine, while remaining distinct from those of the choledochus, seem to be thickened in the vicinity of the sphincter (an observation which we have not confirmed); second, that the number of transverse fibers of the choledochus increases perceptibly at the level where the duct discharges into the ampulla—to a degree constituting a true sphincter. This latter observation is the one which the present embryological investigation has established as being most significant.[3]

Three years later, Hendrickson (1898), a student of the American anatomist Lewellys Barker, published the first study of the human sphincter to be based upon maceration methods (using among others the technique devised by Oddi's teacher, Marcacci). No other description has approached this in accuracy or completeness unless it be the recent account by the Dutch surgeon, Nuboer ('31), from the Institute of Pathology at Utrecht, which has provided the first series of transverse

[2] Greifswald (1895). Cited by Soulié ('01), p. 810; by Halpert ('32) and others. Unfortunately this thesis is not available, but it is presumed that it was sponsored by the anatomist, Emil Ballowitz. According to Halpert, Znaniecki's material consisted of preparations taken from five individuals. This material was then cut serially in celloidin and stained with Orth's picro-lithium-carmine and alum-carmine dyes.

[3] On the basis of v. Znaniecki's thesis, Soulié reconstructed the first longitudinal section of the pars intestinalis that features this preampullary thickening of the intrinsic muscle (loc. cit., fig. 459). In thus incorporating the most characteristic feature of the human sphincter, the French treatise stands in shining contrast to current English texts; for of the four books on anatomy most commonly used in American medical schools, only one (the Jackson edition of Morris) adequately discusses the sphincter of Oddi. The other three do not even mention it except for Waterston's diagram (Cunningham, fig. 930, edition of 1931), in which a segment of the wall of the duodenum is erroneously labelled "circular muscle fibers forming sphincter."

sections through this region in the adult. As these two papers outstrip all others in the field, we shall use them as a basis for comparing the musculus proprius of the adult with that of late fetal stages.

Brief mention, however, should be made of the work of Letulle and Nattan-Larrier (1898), who noted that the bile and pancreatic ducts 'borrow' fibers from the muscle coats of the intestine; of Helly (1899), who emphasized the importance of the longitudinal fibers of the ducts in shortening the major papilla; of Stracker ('09), who demonstrated in macroscopic sections the independence of the musculus proprius (Taf. 2); of Rost ('13) and of Auster and Crohn ('22), who made incidental observations on the human sphincter in connection with their physiological experiments on dogs; of Matsuno ('23), who made a special study of the circular fibers enclosing the pre-ampullary portion of the bile duct, concluding that they were thick enough to produce biliary stasis; of Nagai and Sawada ('25–'26), who made numerous maceration preparations and stressed the variability of the oblique, transverse and longitudinal fibers that compose the sphincter of Oddi, observing that on the mucosal side of the plica the circular fibers predominate, whereas on the other side, the longitudinal fibers are more conspicuous; of Job ('26), who noted that inside the gut wall the bile duct has a very definite sphincter; of Giordano and Mann ('27), who observed that as the bile duct enters the duodenum it is surrounded by intestinal muscle fibers; of Porsio ('29), whose longitudinal diagram of the pars intestinalis would lead one to infer that the musculus proprius throughout much of its length emanates from the intestinal muscle; of Pfuhl ('32), whose study of the histological literature led him to believe that the human sphincter is also a peristaltic mechanism; of Cestari and Tantini ('33), who observed that the muscle of the 'portio intraduodenalis' is autonomous and becomes sparser as it approaches the intestinal cavity; and lastly, of Dardinski ('35), who described the blood and nerve supply and who erroneously concluded that Oddi's sphincter is represented only by certain fibers at the 'base of the papilla' and that the logical place for sphincteric action is where the bile duct pierces the intestinal muscle.

It is now proposed to describe in detail the pattern of the musculus proprius in late fetal stages. It will be recalled that in the preceding article (of this series) discussion of Oddi's sphincter was carried to that period in development in which

the intramural portion of the ducts was surrounded by a sheath of differentiating muscle fibers which extended from just outside the window in the intestinal muscle to the first portion of the ampulla. At that stage (16 weeks) it was not clear what pattern the fibers would assume—excepting those around the fenestral portion of the bile duct. Between that stage and the one which is the basis of this article—a fetus of approximately 34 weeks (43 cm.) of menstrual age—the musculus proprius has acquired what is essentially the adult pattern. For purposes of convenience we have divided it into somewhat arbitrary subdivisions.

THE FENESTRAL PORTION OF THE MUSCULUS PROPRIUS

The sphincter choledochus superior. At this stage, as indicated by the heavy stipple in figure 1, the musculus proprius of the bile duct begins about 0.6 mm. above (and outside) the superior margin of the window and extends to a point about 0.3 mm. below the margin, where, on the pancreatic side, it abruptly ends. Thus, while lying at the entrance of the window—which, in this specimen, measures approximately 1.2 × 2.2 mm.—it nevertheless occupies the extreme upper end of the plica longitudinalis, and its pancreatic side is almost flush with the intestinal muscle (Margo lat., fig. 12). This segment of the musculus proprius we have named the 'pars superior of the sphincter choledochus' or 'sphincter choledochus superior.' It does not appear in the sketches of Hendrickson's maceration preparations (fig. 2B) but that author shows it in cross section (his fig. 32), as does also Nuboer (fig. 4).

A comparison of figures 10 and 12 reveals that it becomes a complete sphincter only after it enters the window, for its upper portion consists of two half cylinders, one on the pancreatic side and one on the intestinal side of the duct. The latter begins about 0.6 mm. above the margo superior as transverse lines of scattered fibers in the periphery of the tunica propria of the bile duct. Such fibers differ from the scattered bundles higher up on the bile duct only in being more numerous. As they turn around the sides of the duct many of them

become obliquely or longitudinally directed (some upward but mostly downward) and apparently mingle with the 'K' fibers of Hendrickson (fig. 2B). At least they cannot be told apart in sections.

Lower down, as the bile duct approaches the window, sphincter fibers appear on the pancreatic side of the bile duct (figs. 10 and 11); meanwhile, those on the intestinal side have blended with the circular muscle of the intestine. More peripherally, i.e., lying outside the tunica propria of the bile duct, offshoots are given off from the outer side of the intestinal muscle (X^1, fig. 10) as reported in the preceding article. These, likewise, join the column of 'K' fibers.

The 'X' fibers of Hendrickson (see fig. 29, Hendrickson, 1898). In this class are grouped all the scattered bundles of fibers that pass from the upper or lower margins of the window (mostly from the corners of the eye-shaped slit) to the sides of the bile duct. We have classified them as follows: X^1, from the outer side of the margo superior (fig. 10); X^2, from the inner (i.e., mucosal) side of that margin (fig. 12); and X^3, from the inner side of the margo inferior (fig. 13). Their function would seem to be at least twofold. They not only attach the bile duct to the window but by getting a purchase on the margins of the window, they are able, when contracting, to shorten the ducts and thus to facilitate the discharge of bile. Some of them, indeed, pass like crossed reins from one side of the upper margin to the opposite side of the duct, as if to erect the duct in contracting. These are the fibers that are described as having been 'borrowed' from the intestinal muscle. Matsuno says that in the adult they may be distinguished from the intestinal muscle by the reduced width of their fibers. Hendrickson gives the best figures of them. Dardinski also shows them in illustrations of his macerated specimens, but we have not been able to understand either his descriptions or his figures. It is therefore to be hoped that these fibrous connections between intestinal and intrinsic musculatures will be studied again by the maceration method in order to bring out more details of their gross arrangement.

These 'X' fibers are of special interest not merely because they connect the two musculatures but because of the difficulty of interpreting them. Are they to be considered as scattered offshoots from the intestinal muscle, induced by the presence

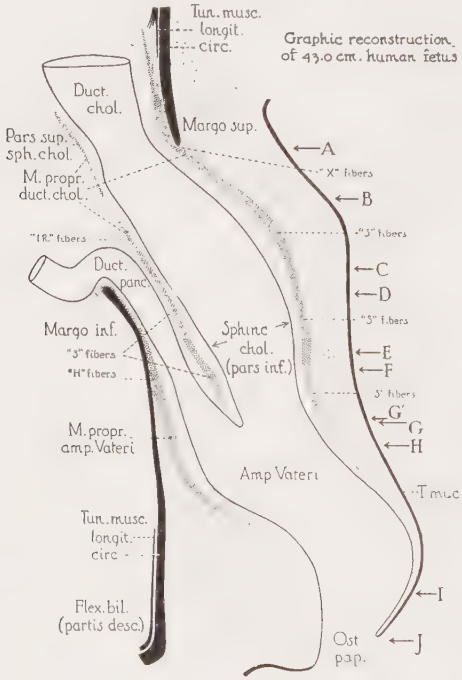

Fig. 1 Graphic reconstruction of the pars intestinalis of a 43-cm. fetus (× 16). *A* to *J*, levels of transverse sections shown in plates 1 to 4 (*H* should be placed ¼ inch lower than appears on the figure). *Heavy black* areas, intestinal muscle; *heavy stipple*, musculus proprius of ducts; *Margo sup.* and *inf.*, upper and lower margins of choledochal fenestra. This is a posterior view, having the same orientation as figure 2B.

of the bile duct—muscle bundles which grow to their destinations by multiplication of fibers or progressive differentiation of mesenchyma—or do they represent early points of contact between the margins of the window and the musculus proprius of the bile duct, which have become drawn out in the course of development? Our study of early fetal stages (compare figs.

1 and 4 of preceding article) suggests that both processes are involved in the formation of at least some of the 'X' fibers. For, as the concentrically arranged mesenchyma of the bile duct comes in contact with the margins of the window and begins to differentiate into the fibers of the musculus proprius, those strands which hit the intestinal muscle tangentially appear to induce a local budding of intestinal muscle that cements

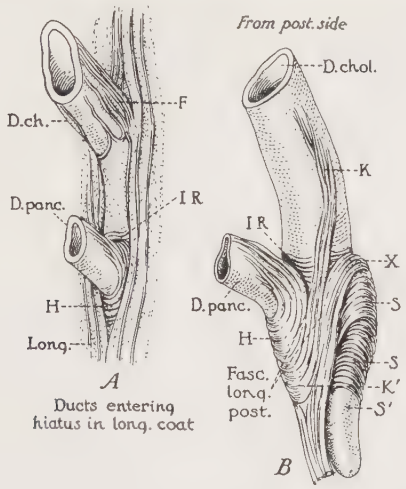

Fig. 2 Sketches of Hendrickson's maceration specimens, redrawn from figures 28 and 30 of his article in the Bulletin of the Johns Hopkins Hospital, vol. 9, 1898. *K'*, our designation for the circular portion of those fibers on the pancreatic side of the ampulla that turn upward onto the bile duct (see *K'*, fig. 14). *S'*, our designation for the circular fibers on the mucosal side of the ampulla, which likewise turn upward to join the longitudinal bundles; *Fasc. long.*, our designation for the combined *S'*, *K'*, *H*, *K* and *X* fibers that cover the interval between bile and pancreatic ducts on the anterior and posterior sides of the pars intestinalis (compare *Fasc. long.*, fig. 14).

the point of contact; so that thereafter such fibers of the musculus proprius appear to 'emanate' from the margins of the window. Then as they become drawn out in the course of growth they appear to be strands of intestinal muscle running to the sphincter of Oddi.

The 'F' fibers of Hendrickson (fig. 2A). These are the flaring and frayed ends of the longitudinal muscle of the intestine which are attempting to encircle the ducts and pancreatic

lobes (figs. 10 and 11). In later stages as the bile duct expands to meet them, these fibers appear to form the outer layer of the bile duct (fig. 4)—becoming superimposed upon the 'K' fibers—but in reality they merely camouflage the entrance of the duct into the intestinal wall.

THE SPHINCTER CHOLEDOCHUS INFERIOR

This ring-like sheath of fibers encloses the bile duct from the choledochal window to the junction of bile and pancreatic ducts. It is composed of the 'IR' ('independent ring') and the 'S' ('sphincter') fibers of Hendrickson. Why that author felt it necessary to give two designations to this continuous sheath is not clear. For in two out of our three fetuses over 6 months of age (fig. 8 of this article and fig. 6 of article I) it is even continuous with the sphincter choledochus superior (not recognized by Hendrickson). Accordingly, it is perhaps more accurate to designate this lower portion as the 'pars inferior of the sphincter choledochus.'

Upper and lower parts, together, form a sheath 2.5 mm. long in this 8-month fetus. Matsuno describes it in the adult as varying from 5 to 10 mm. in length. His description of it is perhaps the best. He states that this ring of musculature surrounds the lumen of the duct in the manner of a cohesive band which yet exhibits interruptions in those places in which large glandular convolutions are lodged. Nuboer speaks of the muscle mantle of the choledochus as reaching its greatest extension just before the ampulla of Vater and as consisting mostly of incomplete circular fibers that are ensnared by oblique and longitudinal fibers, all three together forming a closed mantle around the duct. Znaniecki, as noted above, was the first to describe this ring.

Figs. 3 to 7 Photographs of Nuboer's drawings (figs. 13 to 17 of his article in the Frankfurter Zeitschrift für Pathologie, Bd. 41, 1931); 3, Longitudinal section of pars intestinalis of a 59-year-old man; 4 to 7, successive transverse levels of pars intestinalis in a 39-year-old man. Compare figure 4 with figures 10 and 11; 5 with figure 13; 6 with figure 16; 7 with figure 17. All legends are ours, placed on Nuboer's figures to facilitate comparison of adult and fetal structures.

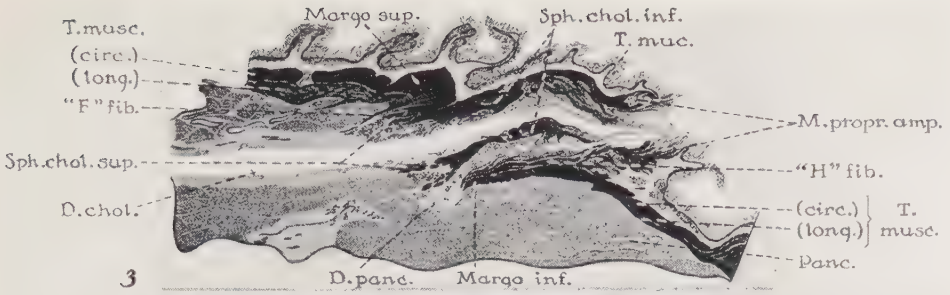
T.musc.
(circ.)
(long.)
"F" fib.
Sph.chol.sup.
D.chol.
Margo sup.
Sph.chol.inf.
T.muc.
M.propr.amp.
"H" fib.
(circ.)
(long.)
T. musc.
Panc.
D.panc.
Margo inf.

3

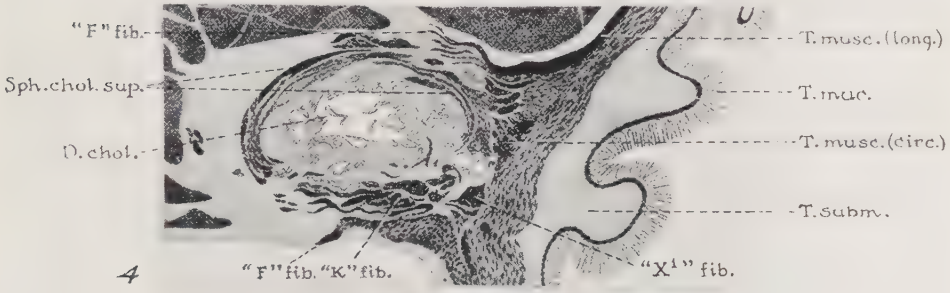
"F" fib.
Sph.chol.sup.
D.chol.
T.musc.(long.)
T.muc.
T.musc.(circ.)
T.subm.
"F" fib. "K" fib.
"X¹" fib.

4

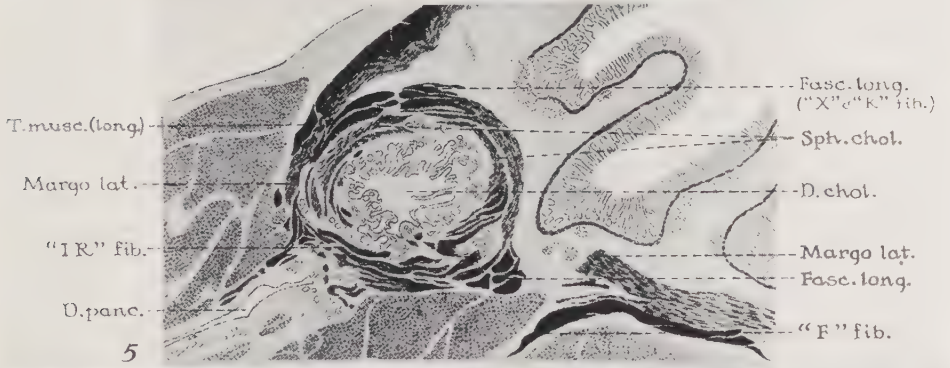
Fasc.long.
("X" & "K" fib.)
T.musc.(long.)
Sptv.chol.
Margo lat.
D.chol.
"I R" fib.
Margo lat.
Fasc.long.
D.panc.
"F" fib.

5

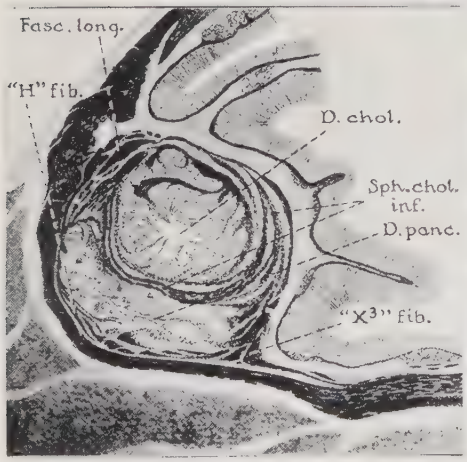
Fasc.long.
"H" fib.
D.chol.
Sph.chol.
inf.
D.panc.
"X³" fib.

6

Fasc.ant.
Sph.
amp.
Junct.
Fasc.post.

7

As one proceeds downward from the window (figs. 13 and 15) the pars inferior of the sphincter becomes further and further removed from the intestinal muscle. Just before it reaches the ampulla it undergoes its greatest development (fig. 16).

Here, then, is a sheath of circular muscle that is so strategically placed as to close the bile duct independently of the action of any surrounding muscles. Accordingly it is to be inferred that this is the muscle which causes the filling of the gall bladder during the intervals between meals and the one which, in becoming overstimulated during certain physiological or pathological states, gives rise to the clinical entity known as biliary dyskinesia or dyssynergia. In other words, this is presumably the muscle which fulfills the functions attributed by Oddi to the intrinsic musculature of the whole oblique passage.

THE MUSCULUS PROPRIUS DUCTUS PANCREATICI

These are the 'H' fibers of Hendrickson (fig. 2B). We have seen them, in the 4-month fetus (figs. 14 to 16 of article II), differentiating from that layer of mesenchyma which lies between the margo inferior and the pancreatic duct. By the eighth month (fig. 16) they are seen to consist of transverse arcs which half encircle the pancreatic duct and then assume a longitudinal direction. Whether they turn up or down is not apparent in transverse sections, but in longitudinal sections of an older fetus, they can be seen coursing upward along the ducts and even extending through the choledochal window (fig. 14). We would take exception, however, to Nuboer's statements (pp. 232–233) that "the muscle mantle around the D. pancreaticus has in the main the same structure as that around the D. choledochus" and that just before the union of the two ducts "the muscle of Oddi lies around both ducts in such a way that a fig. 8-shaped structure arises." For, as in figure 6, we have seen only a few insignificant circular fibers on the sides of the pancreatic duct that swing around between the two ducts. Therefore, it is questionable whether the musculus proprius exerts any sphincter action upon the pancreatic

duct. Hendrickson's macerated preparations would suggest that its function is to shorten the pancreatic duct ('H' fibers, fig. 2B).

THE MUSCULUS PROPRIUS AMPULLAE

This is composed of intrinsic muscle that ensheaths the ampulla of Vater. In the fetus under discussion it consists of two systems of different age. First, at the level where the ducts come together, there is an outer sheath of deeply staining fibers which consists not only of outer longitudinal strands ('K,' 'H' and 'X' fibers) but also certain inner circular fibers that encircle both ducts in a radius which lies outside the tunica propria. These circular fibers are obviously the ones seen at the 4-month stage (fig. 15 of preceding article). Below the junction, the ampulla becomes surrounded by a meshwork of much lighter staining fibers which are confined to the tunica propria—obviously the ones just beginning to differentiate at the 4-month stage (figs. 16 and 17 of preceding article). In the 8-month fetus (figs. 17 and 18) the color differences in these two sets of fibers are quite noticeable.

The fate of these younger and lighter staining fibers becomes apparent in the 9-month fetus. On the bile duct side they are the lowermost 'S' fibers of Hendrickson (those which we have labelled S^1, fig. 2B, in order to distinguish them from the fibers that encircle the bile duct); but instead of encircling the ampulla completely, as suggested by Hendrickson's figure they turn upward as soon as they reach the sides of the duct, to join the longitudinal fibers. This may be ascertained by studying serial sections cut parallel to the ampulla. At first one comes down upon circular muscle cut tangentially; then these rings sink into the transverse fissures between the glands of the ampulla; finally, as the lumen of the glands is replaced by that of the ampulla, these semicircular rings turn upward and join the main bundle of longitudinal fibers.

On the pancreatic side of the ampulla, a similar arrangement prevails. Semicircular fibers (*K′*, figs. 2B and 14) turn upward to mingle with the longitudinal system. Many of the

circular fibers of the ampulla are thus connected with fibers that shorten the ampulla.

This brings us to a consideration of the longitudinal system as a whole. We have seen that it is made up of fibers from many sources—*X, K, H, S′* and *K′* (fig. 2B). Others pass to adjacent portions of the plica longitudinalis. All these are gathered together into anterior and posterior fascicles that cover in the interval between bile and pancreatic ducts. These we propose to group under the name '*fasciculi longitudinales.*' Their function is obviously to shorten the different segments of the pars intestinalis and therefore to facilitate the discharge of bile and pancreatic juice. This description can be reconciled with the statement of Nagai and Sawada that on the mucosal (i.e., the bile duct) side of the ampulla the fibers are predominately circular and on the intestinal (i.e., pancreatic) side the fibers are predominately longitudinal, because the longitudinal fibers do not lie exactly in the interval between the ducts but favor the pancreatic side.

Returning now to the ampulla, it is apparent that all of its circular fibers do not pass into the longitudinal fascicles but that some of them completely encircle the ampulla. Such fibers would constitute a sphincter of the ampulla but unquestionably their action is much weaker than that of the sphincter choledochus, especially when we consider that in most cases it is a very short segment.[4] Nor is it likely that it is involved in biliary dyskinesia, because a sphincter at this place would obstruct not only the flow of bile but of pancreatic juice. In

[4] Since writing article I, our attention has been called to the experimental studies of Cameron and Noble ('24). These authors object to Mann and Giordano's statistical study of the length of the ampulla on the ground that the specimens were fixed in formalin. But a scrutiny of Cameron and Noble's article reveals that while they found an average length of 6.7 mm. in 60% of their 100 cases, these measurements were obtained from Wood metal casts after bile stones had been 'stripped' down to the orifice by force of hand, after the duct system thus blocked by a terminal stone had been subjected to pressure of a column of water 1800 cc. high and after the ampulla had been desiccated by running warm compressed air through it. Since then, Mann and Giordano's conclusions have been virtually substantiated by Job ('26), Holzapfel ('30), Dardinski ('35) and Baggenstoss ('37).

this connection it is of interest to recall the critical experiment of Ivy, Voegtlin and Greengard ('33) on a human subject. In this individual, intravenous injection of secretin and cholecystokinin caused a cessation of flow of bile and an accompanying right hypochondriac pain; yet the pancreatic juice continued to flow. Possibly the latter secretion might have come from the accessory pancreatic duct, but a comparison of

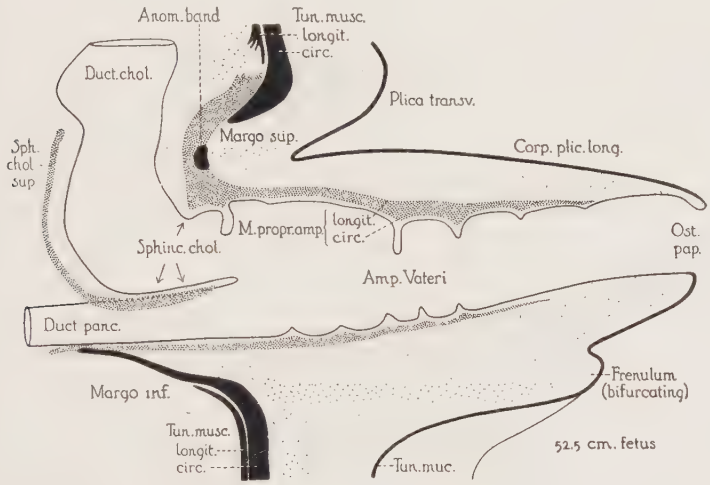

Fig. 8 Graphic reconstruction of the pars intestinalis of a 52.5-cm. fetus (× 17.5). Just below *Margo sup.* note black island. This is the anomalous band of circular intestinal muscle shown in figure 11 (*Anom. band*). The latter figure is a cross section of the bile duct at this level. It suggests that the margo superior may have originally extended to this point. Heavy stipple indicates musculus proprius. Figure 14 is a longitudinal section of the ampulla of figure 8. It cuts the lower curve of the sphincter choledochus tangentially (i.e., in the space between bile and pancreatic ducts).

the sphincter choledochus and sphincter ampullae in our photomicrographs (e.g., figs. 16 and 18) and in Nuboer's drawings (figs. 6 and 7 of this article) strongly suggests that it was the sphincter choledochus in this experiment that held the bile and that the musculature of the ampulla (if one was present) was engaged in shortening the ampulla so that the pancreatic juice could escape.

Lastly, a study of the ampullary musculature fails to substantiate Nuboer's idea that this muscle is capable of peristalsis. The longitudinal fibers are largely limited to the anterior and posterior sides of the ampulla and, as we have shown, much of the circular muscle becomes longitudinal when it reaches these positions. To function peristaltically a sheath of muscle should consist of complete longitudinal and circular layers. Incidentally, it is of interest to note that in the opossum, where peristalsis has been observed, the longitudinal fibers form the inner coat, the circular fibers the outer coat of the ampulla (Du Bois and Hunt, '32).

COMPARISON WITH THE ADULT MUSCULUS PROPRIUS

Between the fetal stages presented in this article and the adult stage, the following changes take place in the pars intestinalis of the biliary tract.

First, as the ducts increase in absolute size the musculus proprius increases proportionately in thickness (figs. 4 to 7).

Secondly, the longitudinal fibers of the duodenum which border upon the choledochal window, draw in closer to the two ducts, not only supplying the bile duct with its outermost longitudinal coat (the 'F' fibers), but narrowing the hiatus through which the ducts are passing. This, in turn, conceals the window in the inner muscle layer of the gut. Thus it is not difficult to understand how Nuboer, studying exclusively the adult pattern, should "acquire the impression that almost everywhere the continuity in the muscle of the gut is not wholly interrupted and that leastwise no great hiatus arises in this layer. Only where the D. pancreaticus leans against the D. choledochus, before uniting with it, can an opening in the gut musculature be present" (loc. cit., p. 230). Yet a comparison of fetal and adult specimens indicates that if the camouflaging strands were swept away, the limits of the choledochal fenestra could be easily detected. Furthermore, it would be important to know the exact gauge of the window in a series of adults in order to determine the size of the calculi that could be passed through. This brings us to the consideration of the next age difference.

Thirdly, the pars intestinalis undergoes reduction in its cross sectional diameter; for Baggenstoss ('37) has shown that its circumference is distinctly less than that of the extra-duodenal portion of the bile duct. His figures for fifty-three adults are as follows:

Measurements of circumference of ducts

	BILE DUCT			PANCREATIC DUCT		
	Mean	Largest	Smallest	Mean	Largest	Smallest
	mm.	*mm.*	*mm.*	*mm.*	*mm.*	*mm.*
Before entrance	10.0	10.7	6	5.5	10	3
At entrance	6.3	9.0	5	4.1	8	2
After entrance	5.4	10.0	4	4.3	7	2

These figures are of importance in explaining how calculi form in the bile ducts. If large stones cannot pierce the window or enter this tapering, muscle-ensheathed segment they must grow by accretion, in situ. Recently one of us (E.A.B.) examined a bile duct that was thus packed tight with stones (fig. 9). Dissection of the specimen indicated that the stone next to the window was gradually breaking down the margo inferior but that up to that time the sphincter choledochus had held. Obviously, in the case of smaller stones the whole pars intestinalis must become distended, sometimes chronically so, permitting regurgitation of intestinal contents—a condition that is classified by clinicians under the heading 'internal biliary fistula' and which is revealed roentgenologically by reflux of barium.

Finally, a word must be said about Nuboer's interpretation of cross sections of the musculus proprius (figs. 3 to 7). Dealing only with the complicated structure of the adult, he writes (loc. cit., p. 228): "By a comparison of transverse and longitudinal sections, it is clear to see that these two muscle groups are so intimately connected in many places, that one must indeed conceive the Muscle of Oddi as arising from the intestinal muscle, whereby the first, however, has also partly preserved an independent character." Without wishing in any way to detract from the excellence of Nuboer's figures—which

give every evidence of most painstaking and accurate observation—we would interpret them somewhat differently, finding in his muscle 'quiver' the same pattern that obtains in the fetal stages described above.

As examples of the deceptiveness of these adult appearances we quote the following passages from Nuboer. Referring to the region of the sphincter choledochus superior (fig. 4), he writes: "It is very clearly recognizable, that the bundles of the muscle of Oddi separate from the outermost lengthwise

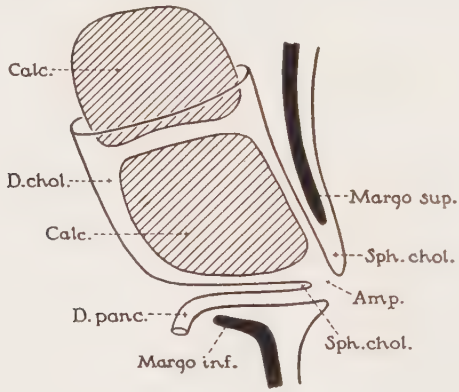

Fig. 9 Scheme of pars intestinalis in a cadaver in which the extramural portion of the bile duct was distended with stones (*Calc.*) too large to enter the choledochal window. Note that the margo inferior is being pressed down and that the sphincter choledochus is still holding. Pressure on the pancreatic duct would seem to be considerable, yet the duct is not distended—perhaps because the accessory pancreatic duct relieves the pressure.

directed muscle layer of the gut, in order to wind around the bile duct or to unravel there along the length of the duct" (loc. cit., p. 228). These, however, are obviously the X^1 fibers which we have seen occupying the former position of the longitudinal muscle but which have sprouted from the circular layer of the gut. Again, in discussing his longitudinal section (fig. 3), he writes (p. 230): "The lengthwise directed layer [of the gut] becomes indeed thinner in a certain withdrawal from the bile duct" [a good description of the fibers we have labelled 'F' in fig. 3]; "forms at times, again, a slight bulge

at the point where it reaches the duct and then unravels with the main mass of its bundles in the direction of the papilla of Vater.'' From this account it appears that Nuboer considers the upper part of that which we have labelled 'sph. chol. inf.,' in figure 3, to have been derived from the longitudinal layer of the gut, yet as we have shown in plate 2 of the preceding article, the longitudinal muscle disappears from the region of the choledochal fenestra sometime before the third fetal month.

SUMMARY

The sphincter of Oddi or musculus proprius of the pars intestinalis of the biliary tract is a continuous sheath of fibers extending from the choledochal window of the duodenum to nearly the end of the ampulla of Vater. It invests not only the bile duct and ampulla but also three sides of the ductus pancreaticus. Its most important segment is the 'sphincter choledochus,' a sheath of annular fibers enclosing the pre-ampullary portions of the bile duct. This muscle is so well developed and so strategically placed as to be capable of stopping the flow of bile into the duodenum independently of the intestinal muscle, thus accounting for the filling of the gall bladder in the interval between meals and for such abnormal states as would result from a physiological stasis induced by overstimulation or hypertrophy of its fibers.

Next in importance would seem to be the two columns of longitudinal fibers (fasciculi longitudinales) which cover in the interval between the two ducts, anteriorly and posteriorly. Liverward, these run up on the sides of the pancreatic and bile ducts to extraduodenal levels and send off sprays to the margins of the choledochal window; toward the lumen of the intestine they end in fibers that encircle the pancreatic side of the pancreatic duct and ampulla, the mucosal side of the bile duct and ampulla, and spread out to adjacent portions of the plica longitudinalis. Contraction of these longitudinal columns would, of necessity, shorten the pars intestinalis and thus facilitate the discharge of bile.

There is no sphincter pancreaticus in the sense of an intrinsic ring of muscle that encircles the pancreatic duct on all sides. The meshwork of fine fibers that encloses the ampulla, however, can be called a 'sphincter ampullae.' Yet in view of the shortness of this segment, in the majority of adults, and the fact that it is much less robust than the sphincter choledochus, it would not seem that it could offer much resistance to the flow of bile and pancreatic juice.

Finally, it is concluded from this study of fetal stages that all constituents of the sphincter of Oddi (except, perhaps, the 'X' fibers of Hendrickson) are of mesenchymal origin, i.e., they develop as a true musculus proprius of the ducts. Yet even the 'X' fibers themselves may represent early points of contact between the musculus proprius and the margins of the choledochal window which have become drawn out in the course of development and so appear to 'emanate' from intestinal muscle.

LITERATURE CITED

(For references not given below, see preceding articles.)

Auster, Lionel S. and Burrill B. Crohn 1922 Notes on studies in the physiology of the gall-bladder. Am. J. Med. Sci., vol. 164, pp. 345–360.

Baggenstoss, A. H. 1937 The duodenal papillae, with special reference to the normal and pathological anatomy of the mucosa. Master's thesis, Univ. Minn.

Cameron, Angus L. and John F. Noble 1924 Reflux of bile up the duct of Wirsung caused by an impacted biliary calculus. An anatomic study concerning its possibility. J. Am. Med. Assoc., vol. 82, pp. 1410–1414.

Cestari, Aldo and Emanuel Tantini 1933 Beitrag zur Histologie der Portio infra-(intra?) duodenalis des Choledochus. Anat. Anz., Bd. 77, S. 98–105.

Dardinski, Vincent J. 1935 The anatomy of the major duodenal papilla of man, with special reference to its musculature. J. Anat., vol. 69, pp. 469–478.

Gage, Simon H. 1879 The ampulla of Vater and the pancreatic ducts in the domestic cat. Am. Quart. Micr. J., vol. 1.

Giordano, Alfred S. and Frank C. Mann 1927 The sphincter of the choledochus. Arch. Path. and Lab. Med., vol. 4, pp. 943–957.

Helly, Konrad K. 1899 Die Schliessmuskulatur an den Mündungen des Gallen- und der Pankreasgänge. Arch. f. Mikr. Anat., Bd. 54, S. 614–621.

Holzapfel, Rudolf 1930 Die Mündung von Gallen- und Pankreasgang beim Menschen. Anat. Anz., Bd. 69, S. 449–453.

IVY, A. C., W. L. VOEGTLIN AND HARRY GREENGARD 1933 The physiology of the common bile duct. A singular observation. J. Am. Med. Assoc., vol. 100, p. 1319.

MATSUNO, YOSHIMITSU 1923 Ueber die Muskulatur des Ductus choledochus. Virch.'s Arch. f. Path., Anat. u. Phys., Bd. 247, S. 208–215.

ODDI, RUGERO 1886–1887 Di una speciale disposizione a sfintere allo sbocco del coledoco. Ann. d. Univ. Libera di Perugia. Fac. di Med. e Chir., ii, pp. 249–264. (Cited by Hendrickson.)

——— 1887 D'une disposition à sphincter speciale de l'ouverture du canal cholédoque. Arch. Ital. d. Biol., T. 8, pp. 317–322.

——— 1888 Sulla tonicita dello sfintere del coledoco. Arch. per le Scienze Med., 12, p. 333. (Cited by Babkin, '28, p. 727.)

PFUHL, WILHELM 1932 Die Gallenblase und die extrahepatischen Gallengänge. In v. Möllendorff's Handb. d. Mikr. Anat. d. Menschen, Bd. V, T. 2, S. 426–462.

ROST, F. 1913 Die funktionelle Bedeutung der Gallenblase. Experimentelle und anatomische Untersuchungen nach Cholecystektomie. Mitt. a. d. Grenzegeb. d. Med. u. Chir., Bd. 26, S. 710–770.

SCHWEGLER, JR., R. A. AND E. A. BOYDEN 1937 The development of the pars intestinalis of the common bile duct in the human fetus, with special reference to the origin of the ampulla of Vater and the sphincter of Oddi. I. The origin and involution of the ampulla of Vater. Anat. Rec., vol. 67, pp. 441–467.

——— 1937 a Id. II. The early development of the musculus proprius. Anat. Rec., vol. 68, pp. 17–41.

SOULIÉ, A. 1901 Structure des voies biliaires. Chap. X, T. IV of Poirier and Charpy's Traité D'anatomie Humaine. Paris.

STRACKER, OSKAR 1909 Die Plica longitudinalis duodeni beim Menschen und bei Tieren. Sitzungsber. d. Math.- Naturwiss. Klasse d. Kais. Akad. d. Wiss., Wien., Bd. 118, Abth. 3, H. 7, S. 375–437.

v. ZNANIECKI, MICHAEL 1895 Beiträge zur Kenntnis der Wandungen des Ductus cysticus, hepaticus und choledochus, namentlich der Muskelfasern des letzteren in der Portio duodenalis. Inaug.- Diss. Greifswald., 25 pp. (Cited by Soulié, Halpert, etc.)

PLATE 1

EXPLANATION OF FIGURES

10 Transverse section of bile duct in 43-cm. fetus. Level *A* (fig. 1). × 34. *Asterisk* indicates first break in margo superior of intestinal muscle, indicating that this section lies just above the choledochal window. For younger stages of same level, see figures 2, 4 and 12 of preceding article; for older stage, see next figure; for explanation of other legends, see text.

11 Transverse section of bile duct of 52.5-cm. fetus. × 38.5. Observe that the sphincter choledochus superior does not completely invest the duct at this level, but consists of circular fibers that become oblique as they reach the sides of the duct. *Anom. band*, anomalous band of circular layer of intestine, represented in figure 8 as a black island. This isolated bundle simulates the appearance of the margo superior and may indicate the original lower limit of that boundary of the fenestra.

12 Transverse section through upper part of fenestra choledocha of 43-cm. fetus. Level *B* (fig. 1). × 34. This is forty-one sections (0.41 mm.) below *A*. Note that the sphincter choledochus superior is now virtually a complete ring of fibers lying some distance from the lateral margins of the window. The intervals between margin and sphincter are filled with pancreatic tissue (*Alv.*) and blood vessels (*Art.*). The bile duct (*D. chol.*) is entering the upper part of the plica longitudinalis. The section is above the level at which the pancreatic duct enters the window.

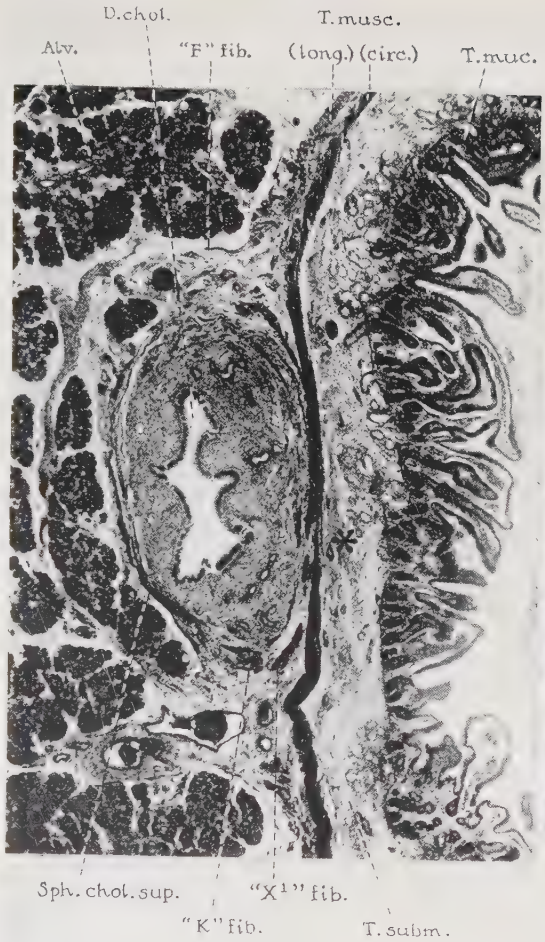
D.chol.
T.musc.
Alv.
"F" fib.
(long.) (circ.)
T.muc.
Sph.chol.sup.
"X¹" fib.
"K" fib.
T.subm.

10

D.chol.
Anom.band
Sph.chol.sup.
"F" fib.
"K" fib.
Margo lat.

11

Sph.chol.sup.
Art.
T.muc.
of
plica long.
Alv.
Margo lat.
D.chol.
"K" fib.
Margo lat.
Sph.chol.sup.
"X²" fib.
"X³" fib.

12

PLATE 2

EXPLANATION OF FIGURES

13 Transverse section through lower part of choledochal fenestra of 43-cm. fetus. Level *C* (fig. 1). × 34. This is fifty-five sections (0.55 mm.) below *B*. Note that pancreatic duct is just entering window and that except for '*X*' fibers, the sphincter choledochus is independent of the inferior margin of the tunica muscularis (*Margo lat.*)

14 Longitudinal section through ampulla and junction of ducts in a 52.5-mm. fetus. × 16.5. This shows the lower end of the sphincter choledochus cut tangentially (compare fig. 8); also the *K'* fibers, swinging around the pancreatic side of the ampulla to join the longitudinal fascicles of the musculus proprius. The upper side of the ductus pancreaticus is cut tangentially. Note pancreatic alveoli (*Alv.*) and blood vessels protruding into the choledochal window. *Lum.*, lumen of intestine filled with debris; *Pap.*, corpus of plica longitudinalis. The limits of the window in the intestinal muscle are indicated by its two lateral margins (*Margo lat.*). *D. panc.*, pancreatic duct cut tangentially.

15 Transverse section just below the choledochal window of a 43-cm. fetus. Level *D* (fig. 1). × 34. This is eighteen sections (0.18 mm.) below *C*. Part of the pancreatic duct is outside the intestinal muscle (*Margo inf.*) and part inside. Note that there are no fibers encircling the pancreatic duct at this level. Other relations are much the same as in figure 13.

"X3" fib.
Margo lat.
D. panc.
Margo lat.
T. subm.
Sph. chol.
D. chol.
"K" fib.
"X2" fib.
"X3" fib.

13

Amp.
Margo lat.
Alv.
D. panc.
Sph. chol. inf.
Margo lat.
Fasc. long.
Lum.
"K'" fib.
Pap.
Fasc. long.

14

"X3" fib.
Margo inf.
D. panc.
T. muc.
D. chol.
Sph. chol.
"X3" fib.

15

PLATE 3

EXPLANATION OF FIGURES

16 Transverse section through the thickest portion of the pars inferior of the sphincter choledochus in a 43-cm. fetus. Level *F* (fig. 1). × 34. This is sixty-one sections (0.61 mm.) below level *D*. (For level *E* of same specimen see Boyden, '37, fig. 5). Note circular 'H' fibers swinging around to the sides of the pancreatic duct where they become longitudinal. Observe that no fibers completely encircle the pancreatic duct.

17 Transverse section through junction of two ducts in a 43-cm. fetus. Level *G* (fig. 1). × 34. This is forty-two sections (0.42 mm.) below *F*. The two ducts are about to join and are enclosed in a common sheath of scattered fibers. The darker staining fibers are older than the lighter staining ones. For detail of this region see figure 21.

18 Transverse section through upper portion of ampulla of 43-cm. fetus. Level *H* (fig. 1). × 34. This is forty-seven sections (0.47 mm.) below *G*. Note that ampulla is surrounded by a delicate network of fine fibers that are less numerous on the side next to the lumen of the intestine. A comparison with figure 16 indicates that the sphincter choledochus is much further differentiated at this stage than the musculus proprius of the ampulla.

Sph. chol. inf.
"H" fib.
D. panc.
D. chol.

16

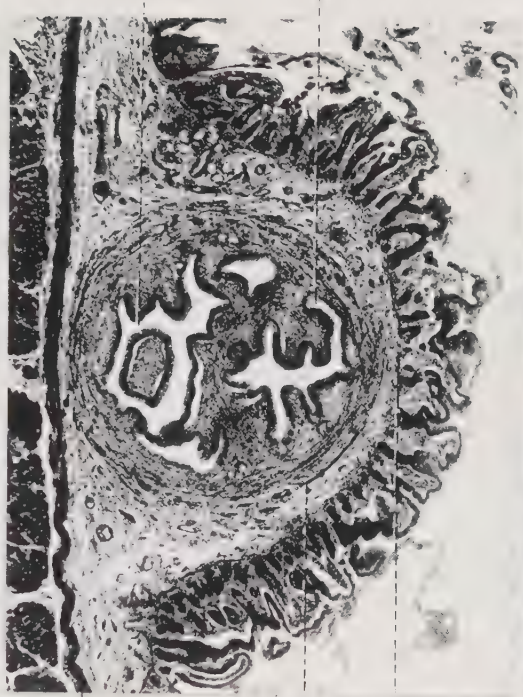
D. panc.
D. chol.
T. musc. (circ.)
Sph. amp.
Musc. muc.

17

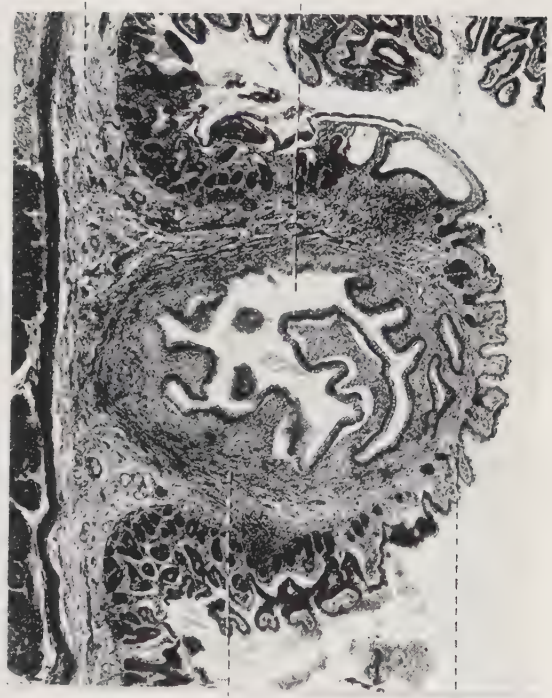
T. subm.
Amp. Vat.
Sph. amp.
T. muc.

18

PLATE 4

EXPLANATION OF FIGURES

19 Transverse section through lower end of ampulla of 43-cm. fetus. Level *I* (fig. 1). × 34. This is eighty-eight sections (0.88 mm.) below *H*. Note that the musculus proprius has disappeared and that the ampulla occupies the distal portion of the plica longitudinalis, the epithelium of which (*epith.*) has lost its folds.

20 Transverse section through orifice of ampulla of 43-cm. fetus. Level *J* (fig. 1). × 34. This is thirty-six sections (0.36 mm.) below *I*. *Ost. pap.*, orifice of ampulla.

21 High power view of level G^1 (fig. 1), × 100; four sections above figure 17. Note goblet cells in pancreatic duct, coarse and fine circular fibers of the musculus proprius of the ampulla, and lowest fibers of the sphincter choledochus.

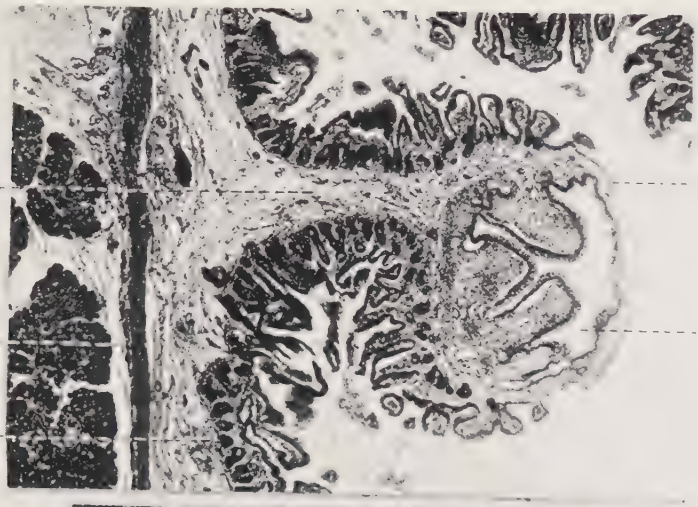
Plica long.
Epith.
T. musc. (long.)
Amp. Vat.
Gl. subm.

19

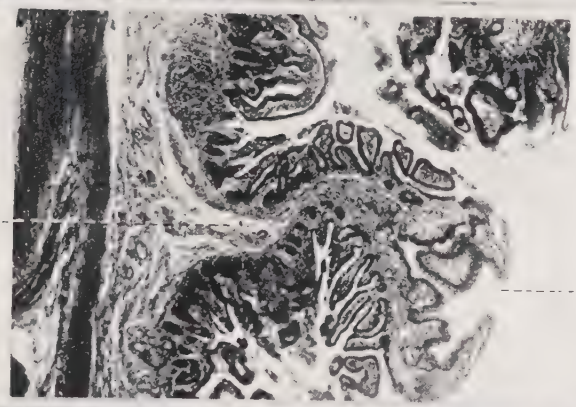
Plica long.
Ost. pap.

20

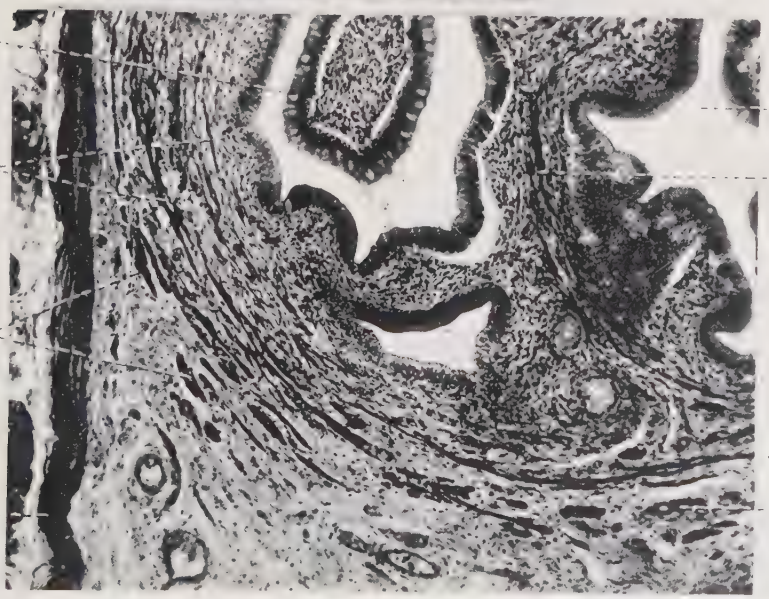
Goblet cells (d. panc.)
M. propr. amp. (circ.)
(long.)
T. musc.
D. chol.
Sph. chol. inf.
M. propr. amp.
(circ.)
(long.)

21

TWO SIMPLE NOMOGRAPHS FOR ESTIMATING THE AGE AND SOME OF THE MAJOR EXTERNAL DIMENSIONS OF THE HUMAN FETUS

RICHARD E. SCAMMON

The Graduate School and Institute of Child Welfare, University of Minnesota

TWO FIGURES

It has been known since the days of Mall's classic studies ('07) that linear and circumferential dimensions of the body could be very generally expressed by a straight line, viz:

$$D = aL + b \tag{1}$$

where D is the dimension in question, L is the body length, either total or crown-heel length or crown-rump length or sitting height, and *a* and *b* are empirically determined constants. This rule holds true for practically all external bodily dimensions from the middle of the third lunar (or menstrual) month of prenatal life to birth. The age can also be determined approximately from the total or crown-heel body length by the simple parabola:

$$A = 2.3 + 0.089\ CH + 0.00128(CH)^2 \tag{2}$$

where A is the age in lunar months from the onset of the last menstruation and CH is crown-heel or total body length. If estimates of age (A) from the crown-rump (CR) length or sitting height of the body are preferred, the following expression obtained by substitution in (2) may be used:

$$A = 1.7 + 0.106\ CR + 0.00293(CR)^2 \tag{3}$$

The expressions given should be regarded as approximations at best, due in large part to the inaccuracy of even the best collections of records of duration of pregnancy. More complicated expressions will give slightly better fits and will extend below the second half of the third lunar month.



Fig. 1 Nomograph of ten major external bodily dimensions in the fetal period, of crown-heel length, crown-rump length, and computed age. CH, crown-heel, total or standing height (length), CR, crown-rump, body stem or sitting height (length). Numbers on the vertical scales in centimeters (Arabic numerals), with the exception of computed age (from the first day of the last menstruation) which is given for lunar months in Roman numerals.



Fig. 2 A second nomograph of external bodily dimensions. Details as described in figure 1.

Using the expression (2) for the relation between total body length and age (developed by Scammon and Calkins, '23) and the several expressions for the relation of external bodily dimensions to crown-heel or to crown-rump length (Calkins and Scammon, '25; Scammon and Calkins, '29), to eliminate tedious computation two nomographs[1] have been drawn up to give the approximate size of commonly measured external dimensions with respect to crown-heel and crown-rump body length and computed menstrual age.

The construction of the nomographs is simple. They consist of oblique grids (so arranged to give more space for lettering). These oblique grids contain vertical and oblique lines. The lateral vertical lines on either side are calibrated for crown-heel and crown-rump length and external to these are columns in alternate segments black and white representing the calculated age in weeks from the first day of the last menstruation. The calculated age in lunar months is indicated on these columns in Roman numerals. Each intermediate vertical line is scaled for the dimension in question. The oblique lines represent 5 cm. intervals of total body length.

The nomographs may be used in several ways. If the magnitude of a mean approximate dimension or dimensions is desired for a given age, draw a taut thread across the nomograph between the corresponding age points and parallel to the oblique lines on the grid. If an estimated age or dimension is desired from a given dimension, use the same process, placing the thread at the level of the measurement on the appropriate scale and keeping it parallel to the oblique lines of the grid.

[1] The principles of nomography were suggested in the seventeenth century. The subject was really developed by M. d'Ocagne (1884). Nomographs are used chiefly for representing power expressions. Perhaps the best discussion of nomographs in M. d'Ocagne's Traité de Nomographie (Paris: G. Villars, 1899) and Le calcul simplifié (Paris, '05). Good accounts in English are given in Brodetsky, S., A first course in nomography (London: G. Bell and Sons, '20), Lipka, J., Graphical and mechanical computation (New York: John Wiley and Sons, '18), and Feldman, W. M., Biomathematics (London: Charles Griffith and Co., '35). The nomograph is rarely used for rectilinear functions.

LITERATURE CITED

CALKINS, L. A. AND R. E. SCAMMON 1925 Empirical formulae for the proportionate growth of the human fetus. Proc. Soc. Exp. Biol. and Med., vol. 22, pp. 353–357.

MALL, F. P. 1907 On measuring human embryos. Anat. Rec., vol. 1, pp. 129–140.

SCAMMON, R. E. AND L. A. CALKINS 1923 Simple empirical formulae for expressing the lineal growth of the human fetus. Proc. Soc. Exp. Biol. and Med., vol. 20, pp. 353–356.

——— 1929 The development and growth of the external dimensions of the human body in the fetal period. Minneapolis: The University of Minnesota Press.

A COMPARISON OF SOME OF THE METHODS USED IN STUDIES OF HEMOPOIETIC TISSUES

A. KIRSCHBAUM AND HAL DOWNEY

Hematological Laboratory, Department of Anatomy, University of Minnesota

TWO PLATES (SIX FIGURES)

Permanent preparations of hemopoietic tissues whose cells may be compared with similar cells in blood smears are valuable in studies of hemopoiesis. The commonly employed method of making microscopic preparations of blood-forming tissues is by chemical fixation in solutions such as 10% formalin, Helly's fluid, etc., embedding the tissue in either paraffin or celloidin, sectioning and staining with Dominici's toluidin-blue, eosin-orange G, Maximow's hematoxylin and azure II-eosin, Giemsa or hematoxylin-eosin. Subcutaneous tissue and omentum have been spread on cover slips, fixed and stained. In the moist fixation (moist-smear) method the fresh tissue (bone marrow, lymph node, liver, spleen) is touched lightly to a cover slip which is immediately floated face down on the fixative. The washed preparation is stained, dehydrated and mounted in balsam.

The above methods have been used by the anatomists and show similar morphological details. In the moist fixation method the complete cell is retained, which is probably an advantage over the section method where only a part of the cell can be seen at once. The cells are larger and show more detail than a single section.

The dry blood smear is the common preparation used in clinical hematology since it is easily and rapidly made and gives a constant picture. From these preparations the commonly discussed cells have been described—megaloblasts,

normoblasts, myeloblasts, leukoblasts, reticulo-endothelial cells, Türk cells, monocytes and lymphocytes. To get preparations with cells having morphological characteristics similar to those of blood smears the dry imprint method for hemopoietic tissues such as bone marrow, lymph nodes and spleen has been devised. Briefly this method is as follows:

1. The cut surface of the tissue is touched lightly to the cover slip or slide which is waved vigorously to insure rapid drying. Cancellous bone, without squeezing to extrude marrow, is touched to the slide for bone marrow imprints.

2. The preparation is then stained like a blood smear. The best results are obtained from Pappenheim's May-Grünwald-Giemsa combination. In this method the slide is flooded for 3 minutes with May-Grünwald stain. An equal number of drops of buffered distilled water are then added, the slide being agitated at the same time. The diluted stain is allowed to remain on the slide for 1 minute. It is then drained off and the slide is covered with Giemsa stain, double strength (2 drops of stock solution to 1 cc. of distilled water) for 10 to 12 minutes, as recommended by Ferrata. This time may be varied according to the material. The preparation is differentiated in distilled water and allowed to dry in the air.

A comparison of the cells of the normoblastic red cell series in dry imprints and sections is illustrated in plate 1. The sections (figs. 1 and 2) are taken from Maximow's article in Arch. f. mikr. Anat., Bd. 73, '09. These were made from the liver of a 14-day rabbit embryo. The magnification is $\times$ 1400. The material was fixed in Helly's fluid, embedded in celloidin and stained with hematoxylin-azure II-eosin. For explanation of legends in figures consult description of plate 1. The cells to the right of the sections (figs. 1 and 2) are taken from dry imprints of similar material. The magnification is the same as that of Maximow's sections. Sections made of the livers of littermates corresponded to Maximow's illustrations.

Maximow identified cells 'a' and 'b' (fig. 1) as 'lymphocytes.' Later he called this type of cell a 'hemocytoblast'

(Von Möllendorff's Handbook, '27) while retaining in addition the term 'large lymphocyte' (Textbook of Histology, Maximow and Bloom, '30). In section this cell has one or more large eosinophilic nucleoli and quite basophilic cytoplasm. We do not approve of the indiscriminate use of the term 'lymphocyte' for all the large basophilic cells of sectioned hemopoietic tissues. Downey ('27) showed the necessity for using the dry imprint method for distinguishing the genuine lymphocyte from the myeloblast. The 'lymphocyte' of the embryonic liver shows important morphological differences from the adult blood and tissue lymphocytes of dry smears and imprints (compare cell 'x' with cells 'A,' 'A′′' and 'B'). True lymphocytes such as those seen in adult peripheral blood and lymph node imprints (fig. 1, cell 'x') are not found in the embryonic liver. The nucleus of the true lymphocyte (dry imprint) has coarse blocks of basichromatin which are not sharply separated from the parachromatin, the blending of the two types of chromatin giving rise to a 'cloudy' appearance. Cells 'A,' 'A′′' and 'B' do not answer to this description. In cell 'A,' a transitional stage between a mesenchyme cell and pronormoblast, the basichromatin is present in the form of a coarse stippling; the cytoplasm is basophilic. The nucleus of cell 'B' has the coarser clumps of basichromatin characterizing the basophilic normoblast. The cytoplasm is more basophilic than in cell 'A.' Cell 'A′,' a myeloblast from the liver (dry imprint) of a 19-mm. pig embryo, has a delicate chromatin net, two sharply defined nucleoli and lightly basophilic cytoplasm. It is quite similar to a myeloblast from chronic myelogenous leukemia illustrated by Downey ('27), cell 46, plate I. Maximow's 'large lymphocytes' of the yolk sac appear to be basophilic megaloblasts (fig. 3).

Maximow considered the 'large lymphocyte' a totipotent stem cell in both embryonic and adult life. The stem cell of hemopoietic tissues has the appearance of cell 'A′′' (19-mm. pig embryonic liver imprint). This cell is described above and is Naegeli's myeloblast (Pappenheim's lymphoidocyte, Ferrata's hemocytoblast).

Cell 'c' (fig. 2) is the 'megaloblast' of the strict unitarian school (Maximow, Jolly, Jordan). In dry imprints it appears as the basophilic normoblast of clinical hematology (fig. 2, cell 'C'). The coarse chromatin pattern approaches the 'radkern' effect which is finally assumed in the polychromatic stage (cell 'D'). Here the blocks of basichromatin are distinctly delimited from the nuclear parachromatin. Perhaps it is better to restrict the term 'megaloblast' to the primitive red cell series formed on the surface of the yolk sac (figs. 3, 4 and 6) and the pathologic erythroblasts of pernicious anemia. Such cells must be described from dry imprints or blood smears. In sections differential characteristics between them and the normoblasts are not sharply defined. Cells 'd' and 'D,' 'e' and 'E' (fig. 2) are polychromatic and orthochromatic normoblasts. Note that in sections as well as dry imprints the 'radkern' nuclear pattern is apparent.

The normoblastic series illustrated in plate 1 is cytologically identical with the erythrocyte line of normal adult bone marrow. The chromatin pattern is coarser than that of the megaloblastic series and assumes the 'radkern' effect in contrast to the latter series. Both lines have their distinct old and young forms (plates 1 and 2) with no transitions between the two. The cell labelled 'Pr. Ebl.' in figure 2 (Maximow's section) belongs to the yolk sac megaloblastic series. It is a fully hemoglobiniferous cell of the general circulation and arises in the yolk sac, not the liver, which is a center of normoblastic erythropoiesis.

Nuclear size, cell size and cytoplasmic basophilia were used to correlate the cells in sections and in imprints. Note the difference in the size of the cells resulting from the application of the two techniques (plate 1). The spherical cells are transected in the sections, whereas in the dry imprint the whole cell is present and is flattened out.

Greater clarity of detail, especially nuclear, but also cytoplasmic, makes identification of cells easier in imprint preparations than in sections. The relationship of cells of the tissues to those in the blood is followed more readily in dry

imprint preparations than in sectioned material. Finally, the ease of preparation combined with greater differentiation in staining makes the dry imprint preferable to embedding and sectioning if individual cells are to be identified.

SUMMARY

Comparison is made of the cellular detail seen in permanent preparations of hemopoietic tissues utilizing different methods. No better method than sectioning was found for purposes of cellular orientation. Although tissue architecture is lost, the dry imprint technique offers advantages in respect to both cellular morphology and ease of preparation.

LITERATURE CITED

Downey, Hal 1927 The myeloblast—its occurrence under normal and pathological conditions, and its relations to lymphocytes and other blood cells. Folia Hematol., vol. 34, p. 145.

Ferrata, A. 1933 Le Emopatie. Soc. Ed. Lib. Milan.

Jolly, J. 1923 Traité technique d'hématologie. A. Maloine et Fils. Paris.

Jordan, H. E. 1934 A textbook of histology. D. Appleton-Century Co., New York, London.

Kirschbaum, A. 1937 Cytological studies of mammalian embryonic blood cells. Proc. Soc. Exp. Biol. and Med., vol. 35, p. 542.

Maximow, A. 1909 Untersuchungen über Blut und Bindegewebe, etc. I. Die frühesten Entwicklungstadien der Blut und Bindegewebszellen beim Säugetierembryo, bis zum Aufang der Blutbildung in der Leber. Arch. f. Mikr. Anat., Bd. 73, S. 444.

——— 1927 Bindegewebe und Blutbildende Gewebe. Handbuch der mikroskopischen Anatomie des Menschen. Bd. II, S. 232–583. Die Gewebe. Wilhelm von Möllendorff. Julius Springer. Berlin.

Maximow, A. and W. Bloom 1930 Textbook of Histology. Saunders and Company, Philadelphia.

Naegeli, O. 1931 Blutkrankheiten und Blutdiagnostik. Julius Springer. Berlin.

Pappenheim, A. 1911 Atlas der menschlichen Blutzellen. Gustav Fischer. Jena.

Slider, E. and Hal Downey 1929 Methods for the study of leucocytes, pp. 243–256. Handbook of microscopical technique. C. E. McClung. Paul B. Hoeber, New York.

PLATE 1

EXPLANATION OF FIGURES

The normoblastic series is compared in section and dry imprint. Cells labelled in small letters are from Maximow's plates drawn from celloidin sections (Helly-fixation, hematoxylin-azure II eosin stain).[1] Those labelled in capital letters are cells from dry imprints of similar material, liver of 14-day rabbit embryos (May-Grünwald-Giemsa stain). Note differences in nomenclature given below. × 1400. (Photographs of drawings in water color made with aid of camera lucida.)

1 a, 'large lymphocyte' of Maximow. b, 'large lymphocyte.' A, transition of mesenchyme cell to pronormoblast. B, basophilic normoblast. Note that the chromatin pattern is coarser than in cell 'A.' A′, myeloblast (stem cell) of 19-mm. pig embryonic liver (dry imprint). Note prominent nucleoli and delicate chromatin net characteristic of this cell type. The cytoplasm is lightly basophilic. Compare with cell 'x,' a genuine lymphocyte. X, true lymphocyte as seen in dry imprint of adult rabbit mesenteric lymph node. Note differences in nuclear structure between this cell and the 'lymphocytes' of the embryonic liver as seen in dry imprints (cells 'A' and 'B'). The basichromatin is present in the form of coarse clumps which are not marked off sharply from the parachromatin, and the cytoplasm lacks the intense deep basophilia of the young ced cells.

2 c, 'megaloblast' of Maximow ('09).[2] d, polychromatic normoblast. e, orthochromatic normoblast. C, basophilic normoblast. The cytoplasm is deeply basophilic; the nucleus shows heavy chromatin blocks. D, polychromatic normoblast. Note 'radkern' nucleus. E, orthochromatic normoblast.

Ed, endothelium; Mlz, myelocyte; w, endothelial phagocyte; Pr.Ebl., prim. erythroblast; Lmz′, lymphocyte in mitosis; Mlb, megaloblast in mitosis (Maximow).

[1] Arch. f. mikr. Anat., Bd. 73, '09.

[2] Note that the 'megaloblast' of Maximow is in the normoblastic series. The megaloblasts of pernicious anemia bone marrow in relapse and the embryonic yolk sac are not immature normoblasts.

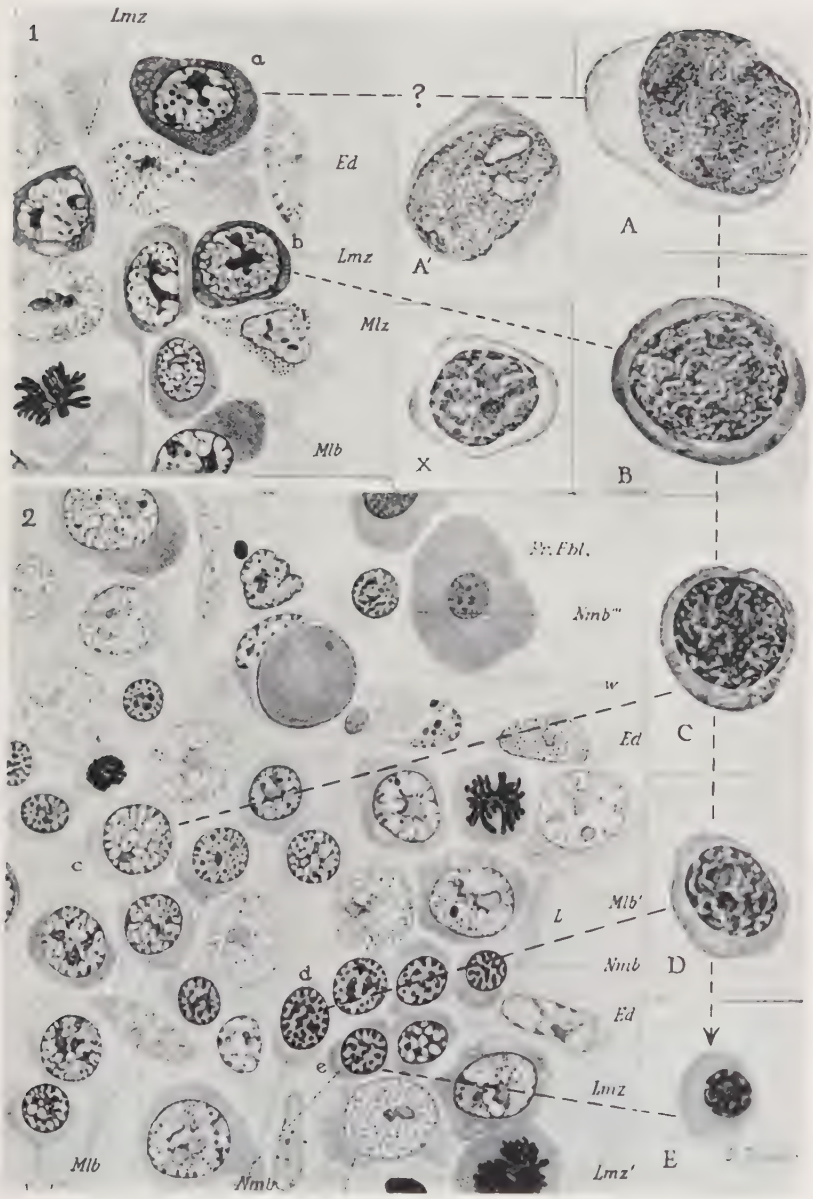
1
Lmz
a
?
Ed
A
b
Lmz
A'
Mlz
Mlb
X
B
2
Pr. Fbl.
Nmb'''
w
Ed
C
c
Mlb'
L
Nmb
D
d
Ed
e
Lmz
Mlb
Nmb
Lmz'
E

PLATE 2

EXPLANATION OF FIGURES

All preparations stained with May-Grünwald-Giemsa stain

3 Dry imprint of yolk sac (11-day rat embryo). Note basophilic megaloblast in the center of the field. The finely stippled nuclear basichromatin stands out sharply due to the great amount of parachromatin providing a light background. Note absence of chromatin clumping. There is a more uniform distribution of the basichromatin than in the basophilic normoblast. The nuclei of cells of this type are similar to those of basophilic megaloblasts of pernicious anemia bone marrow in relapse. Photomicrograph. × 1400.

4 Dry imprint of yolk sac (14-day rat embryo). Group of orthochromatic megaloblasts. Note large size of cells. Compare from standpoint of size with normoblasts of figure 5 (same magnification), most of which are basophilic and polychromatic, and thus more immature. Photomicrograph. × 1400.

5 Dry imprint of embryonic liver (15-day rat embryo). Note basophilic and polychromatic normoblasts with 'radkern' nuclei and heavy blocks of chromatin. These cells are produced extravascularly in the mesenchyme of the liver cell cords. The cell to the left of the normoblast in mitosis is an orthochromatic megaloblast of the circulation, formed in the yolk sac. Similar cells are seen in figure 4. Sections reveal that these cells are within the sinusoids of the liver, and are never found extra-vascularly where the normoblasts develop. Photomicrograph. × 1400.

6 Blood smear of 18-day rat embryo. Note the three large nucleated cells, orthochromatic megaloblasts from the yolk sac. The three smaller nucleated cells are orthochromatic normoblasts formed in the liver. Photomicrograph. × 250.

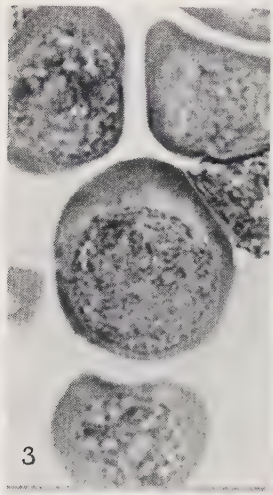
3

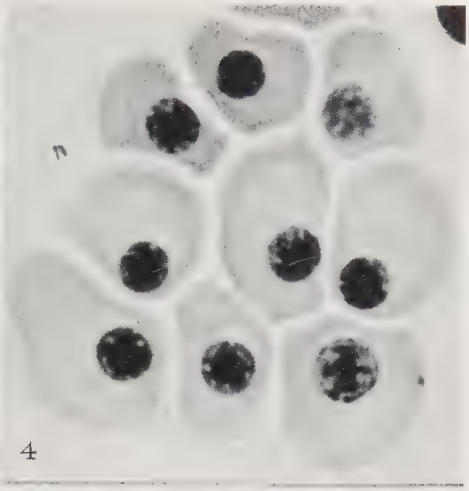
4

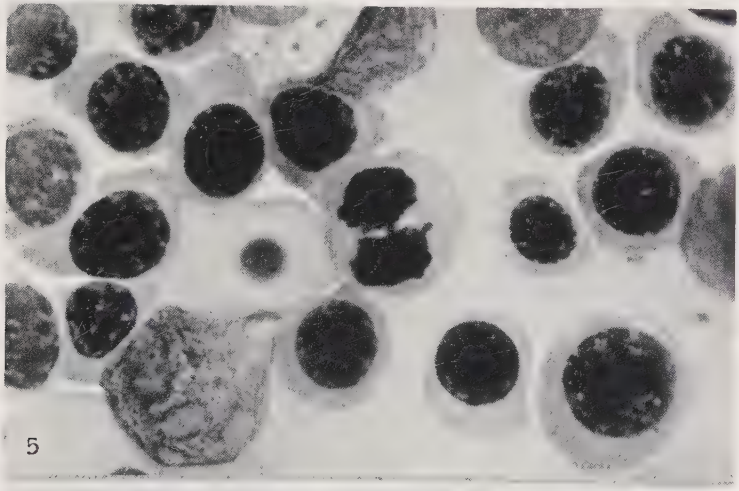
5

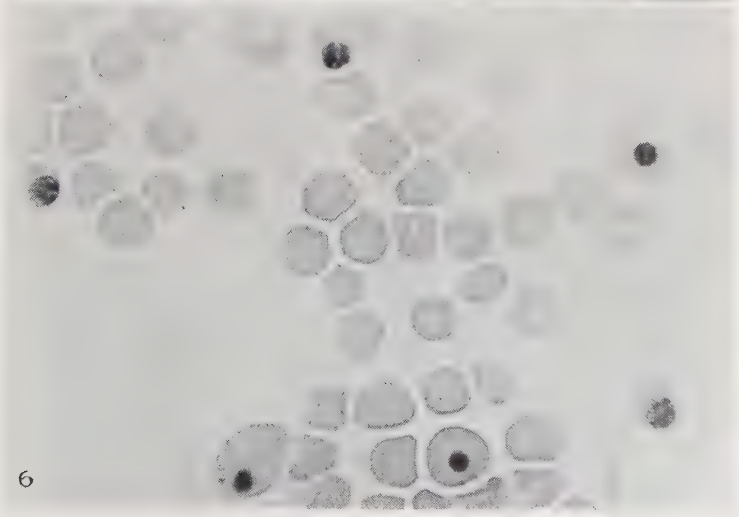
6

COMPARATIVE ACTION OF INJECTIONS OF OESTRIN AND A COMBINATION OF OESTRIN AND ANTERIOR PITUITARY-LIKE SUBSTANCE ON THE ANTERIOR HYPOPHYSIS [1]

J. M. WOLFE

Departments of Anatomy, Vanderbilt University School of Medicine and Albany Medical College, Union University

Recent studies (Hohlweg, '34; Wolfe, '35 a; Selye et al., '35, and Nelson, '35) have indicated that injection of large amounts of oestrin in mature rats stimulates the production of corpora lutea in the ovaries equal in size to those of pregnancy. Injections of oestrin also prolong the life of the corpora lutea in pseudopregnant rabbits (Allen and Heckel, '36). Other experiments have showed that combined injections of oestrin and A.P.L. (anterior pituitary-like substance) into immature rats produces heavier ovaries which contain larger individual corpora lutea than those produced by the injection of A.P.L. alone (Selye et al., '35, and Wolfe, '36). For this reason we have considered it of interest to compare the reaction of the anterior pituitary to injections of oestrin alone to that obtained by injecting combinations of oestrin and A.P.L.

EXPERIMENTAL RESULTS

In the first series twenty-four immature female rats (21 to 28 days old) received daily injections of 200 rat units of oestrin[2] for 10 days. Twenty-one littermate sisters received

[1] These studies were aided by grants made to Vanderbilt University from the Grants-in-Aid Committee of the National Research Council and from the Division of Medical Sciences of the Rockefeller Foundation.

[2] Dihydrooestrin-benzoate (Progynon-B) and progesterone were furnished by the Schering Corporation, Bloomfield, N. J., through the courtesy of Dr. Erwin Schwenk.

daily injections of like amounts of oestrin and, in addition, simultaneous injections of 100 rat units of A.P.L.[3] for 10 days. Twenty-two untreated littermate sisters served as controls. Serial sections of the ovaries and representative sections of the uteri and vaginae were cut. The pituitaries were studied by quantitative methods previously described (Wolfe and Chadwick, '36).

Injection of 200 rat units of oestrin daily for 10 days induced a marked weight increase of the pituitaries; the mean was 6.1 mg. The pituitaries of rats which received combined injections of oestrin and A.P.L. were definitely smaller by weight than those of rats which received oestrin alone; the mean was 4.8 mg. The mean pituitary weight of the controls was 3.1 mg. When the weight data from the three groups of rats were arranged in a frequency-distribution table there was considerable overlap in the pituitary weights of the two experimental groups due probably to the differences in weight and age of the various litters; but when the individual litter group was analyzed separately, the members of the litter which received oestrin alone always presented heavier pituitaries than those which had received oestrin combined with A.P.L. (see table 2 for summary data).

Morphologically and quantitatively the pituitaries of rats which received oestrin alone were considerably different from those of rats which received injections of both oestrin and A.P.L. In the former group the basophiles were almost completely degranulated; the mean relative percentage of the granular basophiles was reduced to the low level of 0.1%. In contrast, the pituitaries of rats which received the combined injections of oestrin and A.P.L. contained appreciable numbers of granular basophiles. While the mean level of these cells was only 2.7%, their presence constituted a definite point of difference between the pituitaries of this group and those which received only oestrin. These granular basophiles were rather small and the negative image of the Golgi apparatus

[3] Pregnancy urine extract (Follutein) was furnished by E. R. Squibb and Sons through the courtesy of Drs. J. J. Durrett and H. Sidney Newcomer.

TABLE 1

Detailed quantitative data arranged in a frequency-distribution table

INTERVAL IN PERCENTAGE	NORMAL IMMATURE FEMALES			NORMAL MATURE FEMALES			CASTRATED FEMALES	NORMAL MALES	
	Control	Oestrin	Oestrin and A.P.L.	Control	Oestrin	Oestrin and A.P.L.	Oestrin	Oestrin	Oestrin and A.P.L.
Eosinophiles									
10.0–14.9							1		
15.0–19.9					6		10		
20.0–24.9		3		4	24	3	8	3	
25.0–29.9		10	5	14	11	6	1	6	
30.0–34.9	5	10	15	66	1	8			1
35.0–39.9	8		10	49		2			4
40.0–44.9	9		6	9					4
45.0–49.9				1					
Basophiles—G.									
None		19	3		40	4	18	2	
0.1–0.9		4	6	74	2	12	2	1	
1.0–1.9			1	28		3		5	
2.0–2.9			8	20					2
3.0–3.9	1		9	12				1	4
4.0–5.9	4		8	8					3
6.0–7.9	15			1					
8.0–9.9	2								
Basophiles—N.G.									
0.0–0.9	3			18	28	2	18		
1.0–1.9	8	1	4	15	11	15	2	1	1
2.0–2.9	6	2	7	38	2	1		1	3
3.0–3.9	1	8	12	39	1	1		1	1
4.0–5.9	4	9	10	30				5	4
6.0–7.9		3	3	4				1	
Chromophobes									
45.0–49.9	2		1	1					2
50.0–54.9	13		7	4					5
55.0–59.9	7		12	41					1
60.0–64.9		9	13	69		4		2	1
65.0–69.9		8	4	28	2	7	2	4	
70.0–74.9		6			16	5	3	2	
75.0–79.9					18	3	5	1	
80.0–84.9					6		9		
							1		

was usually prominent. Careful focussing revealed the presence of small orange or yellowish bodies in addition to the blue basophilic granules in many cells; these former were thought to be mitochondria. The mean level of the granular basophiles in the untreated controls was 6.7%. In both experimental groups the non-granular basophiles were increased (tables 1

TABLE 2

Summary of quantitative data. The groups of castrated animals are indicated by 'Cast.' in the column of ovary weights

SERIES	TREATMENT	OVARY WEIGHT	PITUITARY WEIGHT	PERCENTAGE OF CELL TYPES			
				Eosinophiles	G. Basophiles	N.G. Basophiles	Chromophobes
		mg.	*mg.*				
1	Control	15.1	3.1	38.4	6.7	2.4	52.5
	Oestrin	21.8	6.1	29.0	0.1	4.3	66.6
	Oestrin-A.P.L.	121.0	4.8	34.8	2.7	3.8	58.7
2	Control	48.1	10.2	34.2	1.2	2.9	61.7
	Oestrin	64.6	20.7	23.3	..	1.0	75.7
	Oestrin-A.P.L.	346.0	17.1	29.8	0.5	1.6	68.1
3	Oestrin	Cast.	6.2	25.6	0.1	4.4	69.9
	Oestrin-A.P.L.	Cast.	6.4	26.1	0.1	3.9	69.9
4	Oestrin	64.6	20.7	23.3	..	1.0	75.8
	Oestrin	Cast.	20.0	19.7	..	0.6	79.7
5	Oestrin	18.1	6.3	27.9	..	4.9	67.2
	Oestrin	Cast.	7.0	25.7	..	4.9	69.4
6	Oestrin	Cast.	11.0	27.8	..	1.9	70.3
	Oestrin-Progest.	Cast.	11.0	27.6	..	1.4	71.0
7	Oestrin	Male	8.5	25.8	1.3	3.7	69.2
	Oestrin-A.P.L.	Male	6.0	39.6	3.8	3.6	53.4

and 2). In the pituitaries of rats receiving oestrin alone, numerous eosinophiles exhibited loss of granules and the mean relative level of these cells was reduced to 29%; the mean level of these cells in the untreated controls was 38.4%. However, in the pituitaries of rats which received both oestrin and A.P.L., very few eosinophiles showed evidence of loss of granules and the mean relative level of these cells was not greatly

reduced (tables 1 and 2). In the rats receiving only oestrin the chromophobes were markedly increased in percentage. Many of these cells were greatly enlarged; the cytoplasm was either a dense blue or light blue in color and fragmentary in character. The negative image of the Golgi apparatus was often hypertrophied. In the rats receiving both oestrin and A.P.L. the chromophobes were not increased to as marked a degree as in the other group, and the histologic changes were not so marked (tables 1 and 2). The mean weight of the ovaries of rats receiving oestrin alone was 21.8 mg.; those which received both oestrin and A.P.L. presented ovaries with a mean weight of 121 mg. (table 2). The ovaries of those in the former group contained small corpora lutea in some instances; those in the latter group contained many large corpora lutea.

Since these results were of considerable interest, we have repeated these experiments using mature female rats. Forty-two female rats (series 2) received daily injections of 200 rat units of oestrin for 10 days. A second group of nineteen received in addition to the above amounts of oestrin, 100 rat units of A.P.L. daily for this period. Previous studies made on 143 cyclic females served as control data (Wolfe, '35 b).

The pituitaries of rats receiving oestrin alone were heavier than those which received oestrin combined with A.P.L. (table 2). There was considerable overlap in the pituitary weight between the two groups, but for unit of animal weight the pituitaries were heavier in the rats which received oestrin alone. The morphologic picture in the pituitaries of the two groups differed. In rats receiving only oestrin no granular basophiles were found. In those receiving both oestrin and A.P.L. granular basophiles were found in all but four rats. In rats receiving oestrin alone numerous eosinophiles showed loss of granules and they were reduced in relative percentage to a mean of 23.3%. In rats receiving both oestrin and A.P.L. few eosinophiles presented loss of granules and the relative levels of these cells were not greatly reduced below the normal level of 34.8% found in normal cyclic females (tables 1 and 2).

The chromophobes were markedly increased in percentage in those rats which received oestrin alone but much less so in those which received the combined injections (tables 1 and 2).

The ovaries of the rats which received oestrin alone had an average weight of 64.6 gm. They contained a moderate number of corpora lutea equal in size to those of pregnancy. The vaginae were usually mucified. The ovaries of those rats which received both oestrin and A.P.L. had an average weight of 346 mg. They contained large numbers of corpora lutea, many of which were as large as pregnancy corpora. The vaginae were invariably mucified.

The data in these two series indicated that simultaneous injection of A.P.L. along with oestrin in normal female rats elicited a weight and morphologic response in the anterior pituitary which was considerably modified from the response obtained by injection of oestrin alone. With the exception of the pituitaries, the other most obvious difference in the pituitary-gonad complex of these two groups was the extremely large ovaries, containing many large corpora lutea, found in the rats which received both oestrin and A.P.L. These were obviously over-stimulated when compared with those of rats which received only oestrin. It seemed possible that the modified pituitary obtained in the rats receiving both oestrin and A.P.L. was associated with the marked reaction in the ovaries of these animals or else to the direct action of A.P.L. on the pituitary itself. To ascertain this latter point we have in series 3 compared the reaction of the pituitaries of castrated female rats to injections of oestrin alone with that obtained by injection of both oestrin and A.P.L. Six immature rats were castrated and were immediately given 200 rat units of oestrin daily for 10 days. Six castrated littermate sisters were given the same amount of oestrin for the same period and in addition 100 rat units of A.P.L. daily. Reference to table 2 will show that in the pituitary weight increase in the two groups was almost identical. In like manner the pituitaries were morphologically identical. In both groups of this series practically all basophiles were degranulated. In both groups numerous eosinophiles showed loss of granules and in both the

relative percentages of these cells were decreased to the same extent (table 2). Inversely, the chromophobes were increased in percentage. These data indicated that injections of A.P.L. along with oestrin in castrated female rats in no way altered the response of the pituitaries of these animals to injections of oestrin.

In view of these results, the possibility that the pituitary differences in the normal rats were due to the over-stimulation of the ovaries of the rats receiving both oestrin and A.P.L. became more tenable. It was then necessary to ascertain if the presence of the ovaries in the animal, without the stimulating effects of A.P.L., would in any way alter the response of the pituitary to oestrin. We have therefore tested the comparative effects of oestrin on the pituitaries of normal and castrated immature and mature female rats. Forty-two normal female rats (series 4) received daily injection of 200 rat units of oestrin daily for 10 days. Twenty castrated rats received like amounts of oestrin for the same period; injections were started immediately after ovariectomy. At autopsy it was found that the pituitary weights were almost identical in the two groups; the mean weights were 20.7 and 20.0 mg., respectively. The range of variation was practically the same in both groups. Morphologically, the basophiles were completely degranulated in both groups. In both groups many eosinophiles showed loss of granules. These cells in the non-castrates were reduced in percentage to a mean of 23.3% and in the castrates to a mean of 19.7%. The mean level of these cells in normal cyclic females was 34.8%. Analysis of the frequency distribution (table 1) reveals the fact that in the castrates the eosinophiles showed some tendency to be lower in percentage than occurred in the normal rats receiving oestrin; inversely, the level of the chromophobes was somewhat higher. However, there was no clear-cut or constant difference between the pituitaries of normal and castrated rats which had received the same amounts of oestrin for the same period of time (tables 1 and 2). These experiments were repeated using littermate immature female rats (series 5). Eight rats received daily injections of

200 rat units of oestrin daily for days. Eight littermate sisters were castrated and received the same treatment. The results obtained confirmed those in series 4. The summary data are given in table 2.

Since the reaction of the pituitaries of normal and castrated female rats to oestrin was essentially the same, the only factor that could definitely be associated with the modified pituitary response in the normal female rats which received both oestrin and A.P.L. was the intense over-stimulation of the ovaries of these rats. The most conspicuous feature of these greatly enlarged ovaries was the presence of the great amount of lutein tissue. It seemed possible that greater amounts of the corpus luteum hormone had been produced in the ovaries of those animals which had received both oestrin and A.P.L. than had been produced in those of rats receiving oestrin alone. It therefore seemed necessary to ascertain if the simultaneous injection of the corpus luteum hormone along with oestrin would alter the pituitary response to oestrin. Such a view was held tenable because it has been demonstrated that the simultaneous injection of progesterone modifies the response of the vaginal epithelium to oestrin (Allen and Meyer, '35; Selye et al., '36).

Three mature castrated female rats received daily injection of 1.5 rat units of oestrin daily for 30 days; the injections were begun immediately after castration. Three other castrates received the same amounts of oestrin for the same period and in addition 500 γ of progesterone[4] daily. The rats receiving oestrin alone remained in an almost constant oestrus; those receiving both oestrin and progesterone remained in dioestrus. At autopsy the vaginal epithelium of those rats receiving oestrin alone was cornified; those receiving both oestrin and progesterone were mucified. However, the pituitary response to oestrin was not modified by the additional injection of the progesterone in these experiments. In both groups the mean pituitary weights were almost identical and the range of variation was approximately the same. Morphologically, the pituitaries were indistinguishable. In both

[4] See footnote 2 on page 237.

groups castration changes were completely prevented. Few granular basophiles were found in either group; numerous non-granular basophiles were found. In both the eosinophiles were reduced only slightly in relative percentage. Within the limits of this small series of experiments, the injection of progesterone along with oestrin did not modify the pituitary response to oestrin (see table 2, series 6, for summary of data).

These experiments seemed to indicate that the modified pituitary response obtained in the first two series described was associated with the increased ovarian reaction but was not due to any possibly increased amounts of the corpus luteum hormone. It was considered worthwhile to repeat these original experiments on male rats. In series 7, nine male rats received 200 rat units of oestrin daily for 10 days. A second group of nine rats received the same amounts of oestrin for the same period and in addition 100 rat units of A.P.L. daily for the same period. Both mature and immature rats were used. At autopsy it was found that the pituitaries of rats which received oestrin alone were heavier than those which received the combined injections (table 2). In the rats receiving oestrin the mean testis weight was 1 gm., the mean combined weight of the prostate and seminal vesicles was 0.18 gm. In the rats receiving the combined injections, the mean testis weight was 1.6 gm., that of the prostate and seminal vesicles was 1.7 gm.

Morphologically the pituitaries of the rats receiving the combined oestrin and A.P.L. injections varied from those which received only oestrin. In the latter group a great majority of the basophiles exhibited loss of granules, the mean level of the granular basophiles was only 1.3%. In the pituitaries of rats receiving the combined injections the granular basophiles were much more abundant, the mean level was 3.8%. References to table 1 will show that in only one instance was there any overlap in the levels of these cells between the two groups. In the pituitaries of the rats receiving oestrin alone the mean level of the eosinophiles was rather markedly reduced below that found in normal male rats; the mean was 25.8%. Numerous cells presented loss of granules. The eosinophiles

were much more abundant in the pituitaries of rats which received both oestrin and A.P.L.; the mean level was 39.2%. There was no overlap in the levels of these cells between the two groups (table 1). The chromophobes were much more abundant in the pituitaries of the rats which received oestrin alone than they were in those of rats which received the combined injections; the mean levels were 68.2 and 53.1%, respectively. We have considered it legitimate to assume from these experiments that in normal male rats simultaneous injection of A.P.L. along with oestrin induces a modification of the weight and morphologic response of the pituitary from that obtained by injection of the same amount of oestrin alone.

DISCUSSION

The significance of these experiments is at present unknown. If the weight increase and the degree of degranulation of the chromophilic cells (together with a reduction in their relative percentages and an increase in that of the chromophobes) is considered as an index of the capacity of oestrin to induce changes in the anterior lobe, these experiments would probably indicate that the simultaneous injection of A.P.L. along with oestrin more or less inhibits the action of oestrin in both male and female rats with intact gonads. Furthermore, the gonads must be intact before the modified pituitary reaction is obtained. The experiments involving the use of progesterone and oestrin in castrated female rats and those on the male rats would seem to indicate that the hormone of the corpus luteum is not the factor responsible for the modified pituitary reaction. It does seem that the excessive stimulation of the gonads in the normal male and female rats can be associated with this modified reaction. The experiments of Meyer et al. ('32), of Leonard et al. ('31) and of Moore and Price ('32) have demonstrated that under certain conditions injection of oestrin may suppress the activity of the anterior lobe while those of Hohlweg, of Wolfe, of Selye et al., and of Hisaw et al. ('34) indicate that oestrin injections stimulate the production or the release of a luteinizing factor from the

anterior lobe. How the data in this paper fits in with that mentioned in the papers above is at present a matter of conjecture.

SUMMARY

1. The injection of relatively large amounts of A.P.L. simultaneously with oestrin in male and female rats with intact gonads resulted in a weight and morphologic response in the anterior pituitary which was modified from that obtained by the injection of oestrin alone. The degree of the weight increase of the pituitary and the degree of degranulation of the chromophilic cells, together with a reduction in their relative percentages and an increase in that of the chromophobes, were more marked in those animals which received oestrin alone than in those which received combined injections.

2. The above effects were not obtained in castrated female rats.

3. The anterior pituitary response of normal and castrated female rats to injections of oestrin was practically the same.

4. Injection of progesterone simultaneously with oestrin did not result in a pituitary response different from that obtained by injections of oestrin alone.

LITERATURE CITED

Allen, W. M. and S. P. Heckel 1936 Prolongation of the corpus luteum in the pseudopregnant rabbit. Science, vol. 84, pp. 161–162.

Allen, W. M. and R. K. Meyer 1935 Physiology of the corpus luteum. 9. The inhibition of oestrin by progestin-containing extracts of corpus luteum. Anat. Rec., vol. 67, pp. 427–439.

Hohlweg, W. 1934 Veranderungen des Hypophysenvorderlappens und des Ovarium nach Behandlung mit Grossen Dosen von Follikelhormon. Klin. Woch., Bd. 13, S. 92–95.

Hisaw, F. L., H. L. Fevold, M. A. Foster and A. A. Hellbaum 1934 A physiological explanation of the oestrous cycle in the rat. Anat. Rec., vol. 60 (suppl.), pp. 52–53.

Leonard, S. L., R. K. Meyer and F. L. Hisaw 1931 The effect of oestrin on the development of the ovary in immature female rats. Endocrinology, vol. 16, pp. 41–54.

Meyer, R. K., S. L. Leonard, F. L. Hisaw and S. J. Martin 1932 The influence of oestrin on the gonad-stimulating complex of the anterior pituitary of castrated male and female rats. Endocrinology, vol. 16, pp. 655–661.

Moore, C. R. and D. Price 1932 Gonad hormone functions and the reciprocal influence between gonads and hypophysis; with its bearing on the problem sex hormone antagonism. Am. J. Anat., vol. 50, pp. 13–49.

Nelson, W. O. 1935 Gonad hormone effects in normal, spayed and hypophysectomized rats. Anat. Rec., vol. 64 (suppl. no. 1), p. 52.

Selye, H., J. B. Collip and D. L. Thomson 1935 Effect of oestrin on ovaries and adrenals. Proc. Soc. Exp. Biol. and Med., vol. 32, pp. 1377–1381.

Selye, H., J. S. L. Browne and J. B. Collip 1936 Effect of combined administration of oestrone and progesterone in adult ovarectomized rats. Proc. Soc. Exp. Biol. and Med., vol. 33, pp. 198–200.

Wolfe, J. M. 1935 a Reaction of the anterior pituitaries of mature female rats to large amounts of oestrin. Proc. Soc. Exp. Biol. and Med., vol. 32, pp. 1192–1195.

——— 1935 b The normal level of the various cell types in the anterior pituitaries of mature and immature female rats and further observations on cyclic histologic changes. Anat. Rec., vol. 61, pp. 321–330.

——— 1936 Ovaries of immature female rats receiving pregnancy urine extract and combinations of pregnancy urine extract and oestrin. Proc. Soc. Exp. Biol. and Med., vol. 34, pp. 26–29.

Wolfe, J. M. and C. S. Chadwick 1936 Quantitative studies on the structural changes induced in the anterior pituitary by injections of oestrin. Endocrinology, vol. 20, pp. 503–510.

FAILURE OF THYROIDECTOMY TO INFLUENCE THE FOLLICULAR COMPONENTS OF THE IMMATURE RAT OVARY [1]

OLIVE L. LEONARD AND SAMUEL L. LEONARD
Biology Department, Union College, Schenectady, New York

Thyroidectomy in the rat increases the effectiveness of injected follicle stimulating hormone from the hypophysis on the rat ovary (Leonard, '36) although this operation has an inhibitory effect on the gonads of the normal rat (Hammett, '26; see also 'Sex and Internal Secretions,' '32 for discussion of the literature). Although the impairment of the gonads is the result of a prolonged absence of the thyroid, it is not clearly indicated whether similar changes occur shortly after thyroidectomy. Recently Lane ('35) has reported that the total number of primary follicles and antrum-containing (vesicular) follicles in the ovary can be increased by injections of follicle-stimulating extracts in amounts that were insufficient to induce gross changes in the ovaries of young rats. We have employed Lane's method to determine whether thyroidectomy in the normal immature female rat would temporarily increase the effectiveness of the normal circulating follicle stimulating hormone as revealed by numerical changes in the ovarian follicular components.

METHODS

Rats of the same strain used by Lane were thyroidectomized and a mock operation was made on the controls to exclude any possible changes which might have resulted from trauma. Two groups of 24-day-old rats were used; the first were killed 6 days after the operation; the second were killed 8 days afterward. At autopsy, the ovaries were weighed, fixed in Bouin's, cut serially at 10 μ and stained with hematoxylin and eosin.

[1] Aided by a grant from the Rockefeller Foundation.

Only follicles containing normal ova and with two or more layers of granulosa cells were counted (primary follicles), the follicles were considered vesicular if a definite antrum was present. Ova in every section of both ovaries were observed, and to avoid duplication, counts were made only when the plane of the section passed through either the nucleolus or the largest diameter of the nucleus.

RESULTS

The follicular count expressed as the mean of the total number of follicles and vesicular follicles per ovary, together with the probable error of the mean is given in the table. In the first group, there were twenty-seven more total follicles in the operated rats than in the controls. However, this was not significant, since the probable error of the standard deviation was only slightly less than the difference of the means. In the second group, the total number of follicles per ovary in the control rats exceeded those in the operated animals by eight which statistically was not considered a significant difference.

There were twenty-seven fewer vesicular follicles per ovary in the thyroidectomized rats in the first group than in the controls. Since this difference is about four times the probable error, it may be considered significant. The average ovarian weight of the operated rats was less than that of the controls by an amount that was also probably significant. In the second group of rats, a difference of three in the average number of vesicular follicles in the experimental and control rats was too small to be considered. The mean body weights of the thyroidectomized rats were slightly less than those of the controls; in the first group, 3.2 gm. less; in the second group, 5.3 gm. less.

DISCUSSION

These results show that under the conditions of this experiment there is no significant change in the total number of ovarian follicles in the immature rat following thyroidectomy.

Lane ('35) has reported that injections of minute amounts of the follicle stimulating hormone increase the total number of follicles in the immature rat ovary. Even though thyroidectomy enhances the effectiveness of the follicle stimulating hormone introduced into the experimental animal, it cannot induce an increased effect of the follicle stimulating hormone produced by the animal's own hypophysis.

The decrease in the number of vesicular follicles, following thyroidectomy, in the first group of rats, seems to be statistically significant. The significance of this decrease, however, can be minimized when considered with the other results. In the second group of rats, only a slight difference occurs between the number of vesicular follicles in the operated and control animals even though they have been without thyroid glands for only 2 additional days. Any precocious maturing action of the circulating follicle stimulating hormone resulting from the augmenting effect of thyroidectomy, should increase the number of vesicular follicles as well as the total follicles in view of Lane's work. These facts have led us to conclude that there is no significant change in the number of vesicular follicles as well as in the total number of follicles in the ovary shortly after thyroidectomy.

Hammett ('26) has shown that the ovaries of rats thyroidectomized at ages of 23 to 100 days are of the same approximate size by 150 days but considerably smaller than the controls. This he attributes to the faulty metabolism of the animal and not to any specific relation of ovary and thyroid. It is a question whether adult rats thyroidectomized for a long period would still show the increased responsiveness to injections of the follicle stimulating hormone.

SUMMARY

Immature female rats deprived of their thyroid glands for 6 to 8 days, show no significant change in the total number of ovarian follicles from their controls. The decrease in the number of vesicular follicles in the group which were thyroidectomized for 6 days, is of doubtful significance.

Follicular components of ovary of immature rat following thyroidectomy

GROUP	NUMBER OF DAYS THYROIDECTOMIZED	AVERAGE OVARIAN WEIGHT (BOTH OVARIES)		AVERAGE TOTAL FOLLICLES (ONE OVARY)		AVERAGE VESICULAR FOLLICLES (ONE OVARY)	
		Operated	Control	Operated	Control	Operated	Control
1 7 exp. 6 cont.	6	13.6±0.56	16.1±0.84	394±24.9	367±23.6	86±6.1	113±7.0
2 8 exp. 7 cont.	8	14.8±0.36	15.5±0.50	416±13.6	424±20.1	104±4.5	107±9.3

LITERATURE CITED

Hammett, F. S. 1926 The role of the thyroid apparatus in the growth of the reproductive system. Am. J. Physiol., vol. 77, p. 527.

Lane, C. E. 1935 The follicular apparatus of the ovary of the immature rat and some of the factors which influence it. Anat. Rec., vol. 61, p. 141.

Leonard, S. L. 1936 Hypophysis-thyroid-gonad relationship. Proc. Soc. Exp. Biol. and Med., vol. 34, p. 599.

Sex and Internal Secretions 1932 Chap. 17. Williams and Wilkins Co., Baltimore.

THE RELATION OF LYMPHOID NODULES TO BLOOD PRODUCTION IN THE BONE MARROW OF THE TURKEY

H. E. JORDAN
University of Virginia

ONE PLATE (FOUR FIGURES)

A sample of tibial marrow of a 4-month-old turkey shows numerous lymphoid nodules.[1] A longitudinal section, 15 mm. by 3 mm., contains twenty-four nodules of various sizes, including nine nodules of relatively large size. Transverse sections with a diameter of 3 mm. show from three to five nodules. Sections of three samples of marrow (tibial, radial and femoral) from a full-grown turkey contain no nodules. The sections of these samples of marrow have the dimensions 15 by 4 mm., 14 by 2 mm. and 8 by 5 mm., respectively. Still larger sections of two samples of marrow (tibial and femoral) from another full-grown turkey show a predominantly fatty condition and lack nodules. Sections of femoral and tibial marrow of a 6-month-old turkey show several nodules.[2] In agreement with conditions in chickens and pigeons only the marrow of young individuals contains nodules. This material extends the scope of avian marrow with typical lymphoid nodules and gives opportunity for additional observations on the relation between lymphocytes and erythrocyte production. Conditions in this material are especially clear with

[1] The material, including samples of marrow, spleen, ceca and liver, was kindly supplied by Dr. E. P. Johnson, Associate Animal Pathologist, Virginia Agricultural Experiment Station, Virgina Polytechnic Institute, Blacksburg, Virginia. The turkeys were said to be "normal as far as we are able to determine . . . . as normal as most any bird you might obtain on the market."

[2] Dr. E. P. Johnson informs me that "this bird had been raised on wire and screened away from flies, so that we know he is free from all the common parasites that affect turkeys."

reference to the evidence for a genetic relation between lymphocytes and erythrocytes and for this reason warrants brief description.

Figure 1 shows the general distribution of the nodules; they are not restricted to any particular region of the marrow cylinder. The typical nodule has a central area where larger cells (hemocytoblasts) predominate. This area constitutes a germinal center. Peripherally the predominating cells are small lymphocytes. Both in this mantle zone and in the germinal zone occur cells of intermediate size between hemocytoblasts and small lymphocytes. Only the larger cells of the nodule, including those of intermediate size, show mitotic figures. The nodule (fig. 3) shows two germinal centers, one near each pole. A capillary near the left border is filled with small lymphocytes.

A striking condition concerns the arrangement of the perinodular marrow; venous sinuses filled with hemocytoblasts and maturing erythrocytes radiate in all directions from the surface of the nodules (figs. 1 and 2). Moreover, the portions of the sinuses next the nodule contain mostly hemocytoblasts, the distal portions mostly erthrocytes, and the intermediate portions mostly maturing eyrthroblasts. Alternating with the erythrocytogenic sinuses are columns of maturing granulocytes, likewise showing a direct series of stages in the progressive differentiation of hemocytoblasts into granulocytes. In the juxtanodular area the granuloblasts are characterized by a variable number of basophilic granules; in the more distal intervascular regions the granulocytes contain only mature eosinophilic granules. In the case of certain of the smaller nodules as seen in the sections the lymphoid mass is completely enveloped by a layer of developing granulocytes.

The special feature of this material relates to certain clearly outlined intranodular capillaries, dilated and rendered more conspicuous by reason of their large content of small lymphocytes (figs. 3 and 4). The nodules are supplied by a plexus of capillaries in connection with a tangential arteriole (fig. 2); the capillaries drain into the more or less complete peripheral

venous sinus which in turn opens into the extranodular radial sinuses. The majority of the intranodular capillaries are collapsed but several may be open and completely filled with small lymphocytes (figs. 3 and 4). The genetic series between large lymphocytes (hemocytoblasts) and erythrocytes and granulocytes, respectively, is complete and clear. The conditions are essentially as previously described for the marrow of young chickens and pigeons ('36). The hemocytoblasts of the germinal center (secondary nodule) proliferate and produce typical small lymphocytes. These in part grow to become parent large lymphocytes. The intermediate growth stages constitute the medium-sized lymphocytes, many of which also divide by mitosis. The majority of the small lymphocytes are forced or migrate peripheralward where they constitute the relatively wide mantle layer. From here they migrate into the intervascular radial columns of the stroma, meanwhile growing in size and reacquiring the general features of the parent hemocytoblast, and differentiating into definitive granulocytes. The morphologic evidence that the smaller cells of the lymphoid nodules of avian marrow are genuine lymphocytes in twofold: 1) These cells are identical with the small lymphocytes of the splenic and cecal nodules; 2) in smear preparations of marrow these cells are cytologically identical after Wright's stain with the small lymphocytes of blood smears.

Within the nodule small lymphocytes migrate into certain capillaries and by this route find their way into the juxtanodular venous sinuses (fig. 4). There is evidence to suggest also that large collections of intranodular lymphocytes may become directly incorporated into the capillaries by peripheral transformation of reticular cells into endothelium, which becomes continuous with the capillary endothelium and in this way transforms an original capillary into an intranodular sinus. The small lymphocytes during their passage into the adjacent venous sinuses begin to hypertrophy. This growth process continues in the proximal part of the sinus until the dilating lumen becomes filled with typical hemocytoblasts.

Distad from such regions these ancestral cells differentiate into erythrocytes, the maturation proceeding in the direction from periphery to center of lumen. There is not the slightest evidence that these hemocytoblast ancestors of erythrocytes arise from endothelium.

Turning from the hemopoietic process as related to definite nodules, to the endosteal portion of the marrow where erythrocytogenesis and granulocytogenesis are equally active, one finds essentially identical conditions. The relatively wide subendosteal venous sinuses are completely filled with hemocytoblasts. Sinuses nearer the medullary axis contain chiefly maturing erythrocytes. In the intervascular stroma of these regions hemocytoblasts undergo transformation into granulocytes. In the case of certain of these subendosteal sinuses there occurs in the sections an apparently direct continuity between the intravascular hemocytoblasts and collections of extravascular small lymphocytes. These collections are related to scattered more peripheral hemocytoblasts along the inner border of the endosteum. Conditions here suggest that histiocytes of the endosteum separate and round off to become hemocytoblasts. These proliferate to form typical small lymphocytes, which in turn migrate into adjacent venous sinuses or become incorporated en mass with these sinuses, meanwhile hypertrophying into typical hemocytoblasts.

The subendosteal marrow contains also frequent nodules and here conditions regarding genetic relation between lymphocytes and hemocytes are identical with those described for the axial lymphoid nodules. In addition, it seems quite possible that many of the small lymphocytes of the subendosteal venous sinuses represent cells which have been separated from the blood stream in these relatively static areas. Apparently the small lymphocytes, whatever their origin, whether from spleen, endosteal histiocytes or from intramedullary lymphoid nodules, all have the bivalent capacity to differentiate via a hemocytoblast phase either into erythrocytes or granulocytes, depending upon location in venous sinuses or intervascular stroma, respectively. The

abundant thrombocytes represent only slightly differentiated intravascular small lymphocytes. No structural criteria appear in this material with which to discriminate between small lymphocytes which become thrombocytes and those which grow to be hemocytoblasts and subsequently mature into erythrocytes and granulocytes. It may be tentatively assumed that the differential factor is one of relatively rapid growth of small lymphocytes.

DISCUSSION

The evidence from a study of the lymphoid nodules of avian bone marrow shows that one of the functions of this lymphoid tissue is to supply the ancestral cells of erythrocytes. The small lymphocyte is a potential erythroblast. The intermediate stage between the small lymphocyte and erythroblast is a large lymphocyte or hemocytoblast. It seems remarkable that this feature of bone marrow of birds, namely the presence of lymphoid nodules, has been overlooked or ignored in connection with the efforts to solve the problem of the significance of the small lymphocyte. In birds, which lack lymph nodes, the homologue of this lymphoid tissue in mammals is located within the marrow in direct genetic relation with the myeloid tissue. Here, as in certain of the lower vertebrates, e.g., hagfish and lungfish, lymphoid and myeloid cells are intermingled in a common tissue; in fact lymphoid and myeloid tissue here are one and the same thing. In the lower vertebrates this common tissue is the spleen or the mesonephros; in birds it is the bone marrow; in these organs the relation of the small lymphocyte to the erythroblast is the same. In certain teleost fishes, elasmobranchs and salamanders the lymphoid spleen is the chief source of the precursors of the erythrocytes; granulocytes may arise in the mesonephroi (teleosts and certain salamanders), the gonads (elasmobranchs) or the subcapsular connective tissue of the liver (many salamanders). In some teleosts the intertubular connective tissue of the mesonephroi is the predominant source of blood cell formation. The subject of the phylogenesis of blood forming tissues has been treated in a previous

publication ('33). The literature relating to lymphoid nodules also has been cited and in part reviewed in an earlier paper ('36). The purpose of this description of lymphoid nodules in the marrow of the turkey is to support further the contention of the normal occurrence of nodules in the marrow of birds, to emphasize the essential genetic relation between lymphoid and myeloid tissues, and to add to the evidence for the claim that one of the important functions of the small lymphocyte inheres in its capacity as a red cell ancestor.

LITERATURE CITED

JORDAN, H. E. 1933 The evolution of blood forming tissues. Quart. Rev. Biol., vol. 8, pp. 58–76.

——— 1936 The relation of lymphoid tissue to the process of blood production in avian bone marrow. Am. J. Anat., vol. 59, pp. 249–297.

PLATE 1

EXPLANATION OF FIGURES

1 Area of tibial marrow of turkey showing distribution of lymphoid nodules. Venous sinuses, filled with hemocytoblasts and maturing erythrocytes, are disposed in radial manner about the nodules. Magnification × 96.

2 Large lymphoid nodule showing at the left border the arteriole which supplies the nodular capillaries. A dilated capillary filled with small lymphocytes appears as a bilobed darker area to the left of the center (indicated by arrow). Magnification × 120.

3 The dilated capillary of nodule, figure 2, highly magnified. The capillary is filled with small lymphocytes. Endothelial cells are indicated by the arrows. Magnification × 920.

4 Long capillary of a large nodule. The lumen is filled with small lymphocytes. At the border of the nodule at the left at the point indicated by the arrow, the capillary is continuous with a venous sinus containing hemocytoblasts and maturing erythrocytes. Magnification × 736.

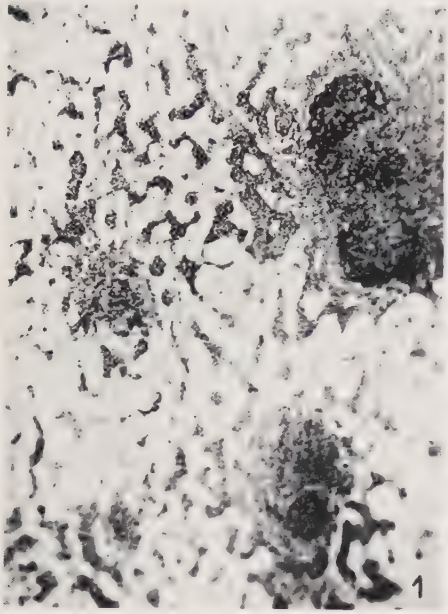
1

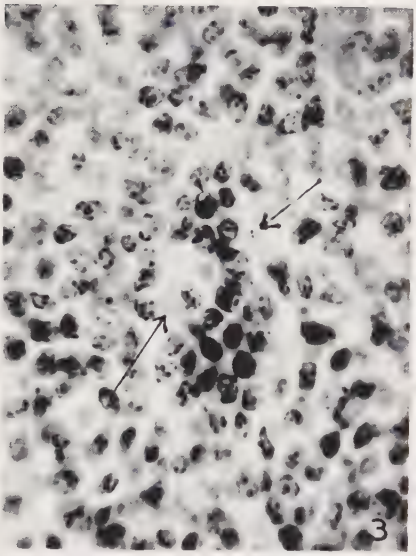
3

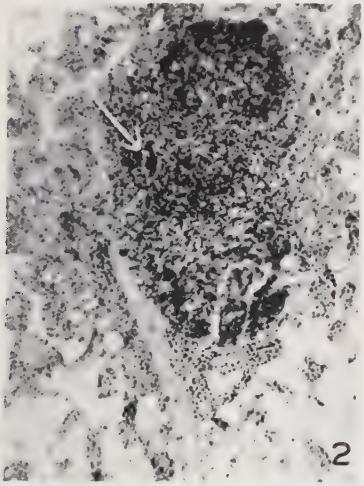
2

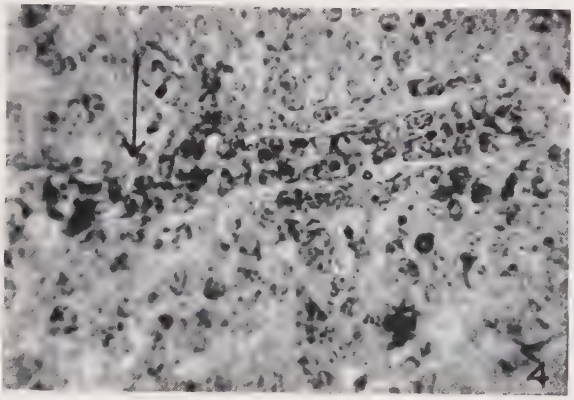
4

NEW BOOKS AND PUBLICATIONS

ELECTRICAL SIGNS OF NERVOUS ACTIVITY, by Joseph Erlanger and Herbert S. Gasser. 1937. Size, $6\frac{1}{2} \times 9\frac{1}{2}$ inches. Pages x + 221. Index. Bibliography. 113 illustrations. Cloth. Price, $3.50. The University of Pennsylvania Press, Philadelphia.

The Eldridge Reeves Johnson Foundation for Medical Physics offers from time to time lectures presenting outstanding advances in various fields of scientific investigation. The 1936 lectures, published in this volume, dealt with electrical signs of nervous activity. The two scientists who gave the lectures divided the subject matter into two parts according to their special interests. Dr. Joseph Erlanger wrote the first three chapters on The analysis of the compound action potentials of nerve, The comparative physiological characteristics of nerve fibers, and Some reactions of nerve fibers to electrical stimulation. Dr. Herbert S. Gasser contributed the chapters on sequence of potential changes and the excitability cycle.

HANDBOOK OF MICROSCOPICAL TECHNIQUE, for Workers in Animal and Plant Tissues. Edited by C. E. McClung. Contributors: William H. F. Addison; Ezra Allen; Joseph L. Appleton, Jr.; Robert Chambers; Herman R. T. Churchill; William V. Cone; Harold J. Conn; Edmund V. Cowdry; Ulric Dahlgren; Hal Downey; Sophia H. Eckerson; N. Chandler Foot; William C. Gibson; Robert T. Hance; Ethel B. Harvey; Chester H. Heuser; Sven Hörstadius; Raphael Isaacs; Ruth McClung Jones; Melvin H. Knisely; Henry McE. Knower; M. J. Kopac; Frank B. Mallory; Clarence E. McClung; Josephine W. McNabb; Frederic Parker, Jr.; Wilder Penfield; Florence R. Sabin; Gordon H. Scott; Paul G. Shipley; Ethel M. Slider; Charles J. Sutro; W. Randolph Taylor and David H. Wenrich. Second edition, revised and enlarged. 1937. Size, $6\frac{1}{2} \times 9\frac{3}{4}$ inches. Pages xviii + 698. Index. 82 illustrations. Fabrikoid. Price, $8.00. Paul B. Hoeber, Inc., New York.

This book on laboratory methods of preparing cytological material for study meets two general needs. To the beginner it gives specific directions applicable to the general run of material. To the experienced investigator it supplies latest approved methods necessary to special results. The second edition retains the good features of the first one and adds much new information including a complete, new dioxan technique for paraffin sections, directions for free hand manipulations of living material, methods for staining boutons terminaux, an account of the fused quartz rod method of illuminating living structure, a description of the micro-incineration method, a presentation of the centrifuge microscope and a description of fluorescent microscopy.

CAT.

W. J. Greenman

MILTON JAY GREENMAN

CAT.

(1866–1937)

When a visitor to The Wistar Institute entered the office of the Director, he found a genial, alert man, trained in biology, gifted to an unusual degree with mechanical and inventive abilities, with business capacity and good judgment, based on the imagination needed for an administrator. Thus Doctor Greenman was peculiarly fitted to bear his many responsibilities.

He died on April 7th, in his seventy-first year, failing rapidly in the few weeks before his death—and the Institute thus lost its real scientific founder, to the sorrow of all those associated with him.

In 1892 he graduated in medicine from the University of Pennsylvania, and became at once associated with Dr. Horace Jayne in the biological work at the University. In 1893 Doctor Jayne became Director of The Wistar Institute, and Doctor Greenman was associated with him as Assistant Director.

During this period he made a remarkable preparation of the bones of the human skeleton, which now forms an exhibition of these structures quite unequalled in detail and elegance.

On the retirement of Doctor Jayne, in 1905, Doctor Greenman was made Director of the Institute. This brought him in direct contact with General Isaac J. Wistar, the Founder of the Institute, and under him he developed his business training.

THE ANATOMICAL RECORD, VOL. 68, NO. 3
JUNE, 1937

Almost at once he began to consider the problems of the further development of the Institute, which, in the earlier years, had grown more as a museum than as a center for investigation. Pursuing this idea, a group of ten anatomists was called in council, and a plan for the research work drawn up. This work began in 1906, and, with the aid of the Advisory Board formed from the original group of advisors, has continued ever since.

Following the purpose of making the Institute helpful to the biologists of the country, Doctor Greenman began taking over the responsibility for the publication of a biological journal. The first experiment was made with the Journal of Morphology. Then gradually, other journals were added until, at the present time, eight such journals have been acquired and are published, together with the bibliographic cards referring to them.

This step brought up the problem of printing, and through the generosity of a member of the Board of Managers, a suitable printing plant was established.

From the beginning of the laboratory work the albino rat had been used as the animal of choice. Large numbers of these had to be kept, and well kept. Here again, through the generosity of a member of the Board, an adequate colony house was built for these animals, not only to furnish those used in the Institute laboratories, but also to permit distribution to other laboratories working with these animals.

In 1916–1917, Doctor Greenman turned aside for a time, to make two excellent studies on the nervous system of the rat. However, increasing executive duties prevented him from further work in this field.

The problem of the welfare of the rats was always before him, and to supply fresh food and pure water, a station was required in the country, where these conditions could be met. In 1928 this was accomplished by the establishment of The Effingham B. Morris Biological Farm, near Bristol and about 30 miles from Philadelphia. Through the generosity of Mr. Morris this station developed rapidly, furnishing build-

ings not only for laboratories but for the culture of amphibians and for the rearing of the opossum—a project in which Doctor Greenman had been interested for many years. Thus was added a division of the Institute which called for much administrative care. Here Doctor Greenman had his home.

He acted as Secretary of the Board of Managers, who were his devoted friends and admirers, and it was through them that many activities not warranted by the resources of the Institute were made possible.

Doctor Greenman has left behind him an unusual record of achievements directed to the advance of biology and of biologists the world over. His work will be long remembered.

Henry H. Donaldson

ON DIFFERENTIAL STAINING

ALEXANDER PETRUNKEVITCH
Osborn Zoölogical Laboratory, Yale University

FOUR FIGURES

In studying cytoplasmic inclusions in the cells of the digestive system of spiders I was confronted with the problem of finding stains which would permit clear differentiation. The inclusions are all granular or globular, of intergrading sizes and of not less than six different organic substances, exclusive of fats and lipoids. Several kinds occur jointly in the same cells and cannot be easily separated either by their size or shape. In may cases they all stain alike or else exhibit a bewildering series of intergrading colors. This is especially true in the case of triple and quadruple staining such as Millot's ('26) acid fuchsin, metanil yellow, light green, toluidin blue method which, as I am now quite certain, led him to wrong conclusions. To settle the question as to whether the intergrading colors were due to differences in the chemical nature of the inclusions or to faults inherent in the staining methods themselves, an extensive analysis was found to be necessary. A great many stains and staining methods after different fixing fluids were tried with variable success. It was at this stage of my work that I had a conference with my friend Doctor Tolstoouhov, on the application of pH control in staining. Unfortunately, neither his methods, nor those of other investigators who used buffered solutions of stains gave the desired results. However, they put me on the track of certain phenomena involved in differential staining, which finally gave me the clue to a proper and reliable method. This method combining the principle of destaining with control of pH promises to have such wide application in

histology that it seemed desirable to publish it in such form as to make it possible for other investigators to apply it to other material.

Let us first consider the factors involved in differential staining. In doing so we may disregard the question as to the physical or chemical nature of staining and use the expression 'staining affinity' for the reaction which takes place when a substance and a stain are brought together. Differentiation is a function of the staining affinity and may be due to one or several of the following factors: The chemical composition and physical state of the substrata, their change under the influence of various fixing fluids, the isoelectric point, solubility in the staining and washing fluids, the chemical composition, purity and dissociation constant of the stain, the pH of the stain, the concentration of the stain, duration of staining, the temperature at which the stain is used and the respective properties of the washing fluids and mounting medium. Many of these factors are interrelated and have been extensively studied by various investigators, making their further, detailed consideration here unnecessary. A short list of references is given at the end of this paper. Further references will be found in the papers listed.

For the better understanding of the method to which we may now turn our attention, the following points must be emphasized.

1. Fixation has a profound effect on staining. Thus the so-called refractive bodies in the interstitial tissue of the digestive organs of spiders remain colorless in acid fuchsin at all pH values at room temperature after fixation in almost all fixing fluids generally employed, but stain a deep red after fixation in absolute alcohol or paranitroformol (4 parts of my cupric paranitrophenol fixing fluid with 1 part of 37 to 40% reagent grade formalin, freshly added).

2. Duration of staining has an effect only when it is shorter than the time required for the completion of the staining reaction. From that time on duration has no effect whatsoever. To achieve identical results one should, therefore, always bring staining to completion.

3. The solvent used in the preparation of the staining fluid has a distinct effect on staining even though not easily noticeable at a glance. Alcoholic and aqueous solutions of the same stain in equal concentration and adjusted to the same pH produce a different degree of differentiation, aqueous solutions being distinctly more selective. Buffer solutions used as solvents for the stains show the same effect. The greatest differentiation is obtained by aqueous solutions adjusted to a certain pH by the addition of HCl or NaOH. Nearest in effect come stains dissolved in acetate, phosphate and borate buffers. Citrate buffers are less suitable because they give a more diffuse staining. Stains dissolved in phthalate buffers give very poor differentiation and should be avoided.

4. The pH value of the staining solution is of the highest importance in itself. Moreover, it is intimately related to the method of fixation. The same stain used after different fixing fluids may have the same effect, but more often has a different effect. In the latter case, at least after some fixing fluids, it may or may not be possible to achieve the same result by using the staining fluid at some other pH value. It is an old experience that staining after fixation in picric acid mixtures is difficult and unsatisfactory. The reason for this lies not in an inability of the tissues so fixed to become stained, but in the fact that they stain diffusely at all values of pH.

5. The concentration of the stain, when the stain is allowed to act to the completion of its reaction, has no noticeable effect on the result within very wide limits. A 0.01% solution, let us say, of toluidin blue gives the same depth of staining as a 0.1% or a 1% solution when used at the same pH to the completion of its reaction. When unbuffered aqueous solutions are used, the degree of concentration may lead to a considerable change of the pH. Thus a 2% aqueous solution of acid fuchsin showed a pH value of 2.85, while the same solution further diluted with distilled water to 0.25% had a pH 3.64. Grübler's aurantia in a saturated aqueous solution had a pH 7.8. A freshly prepared solution of 0.1% had a pH

of ca. 6.4. It is clear that the superiority of staining in dilute unbuffered aqueous solutions as often recommended in preference to more concentrated solutions, is due to the change in the pH value and not to concentration as such.

6. The temperature at which a stain is used has little effect on the result within a wide range, provided the pH is kept constant. The latter, of course, changes with temperature. If the same pH is to be used at considerably different temperatures, the buffer solution has to be adjusted correspondingly. At temperatures over 60°C. a profound change in staining properties may be observed. Thus the above mentioned refractive bodies after fixation in Regaud remain colorless in acid fuchsin at all pH values within usual room temperature limits, but stain a deep red at a temperature of 60°C. or more in the acid range up to about pH 4.

7. The pH of the washing fluid has a profound effect on the result, an effect which is different from that of the pH of the staining fluid. In view of its importance in the application of the method proposed here, it will be discussed in greater detail below.

To achieve uniform results the sources of error were eliminated by the following methods:

a. Stock solutions of a certain concentration were made from samples of certified stains further purified whenever possible. Weighing was done on an analytical balance. Water was twice distilled in a Pyrex distilling apparatus. A volumetric flask was used for dilution.

b. Measurements of pH were made to the second decimal at a temperature of 25°C. with the aid of a glass electrode and an amplifier with a pliotron tube.

c. Temperature was controlled by an airbath of special construction, having a tolerance of $\pm$ 0.02°C., and a water bath with a tolerance better than 0.1°C.

d. Long series of 7 μ sections were made from the same block and mounted without albumen, by stretching over warm distilled water in the usual way. The same species of spider was used in all experiments, namely Phormictopus

cancerides (Latreille), a native of Haiti. In addition, some experiments were made with smears of human blood and sections through the intestine of the leopard frog and the newt. It may be worth while mentioning that some of the cell inclusions in the spider material are proteins and others carbohydrates.

e. The sections were kept at constant temperature in the staining solutions for 12 hours, although it was found that normal staining was attained in about 1 hour.

f. For the study of the effect of pH of the stain, the slides were washed directly in pure dioxan. Most stains are not or very little soluble in dioxan. It was found that even prolonged sojourn in dioxan did not affect the staining density, but for convenience of handling the slides were transferred to xylene before mounting in dammar.

g. In the procedure of the staining method finally adopted, buffer solutions, $\frac{N}{10}$ HCl, $\frac{N}{100}$ HCl and distilled water were used for washing and destaining before dehydration with dioxan.

The first step consists in the preparation of a series of staining fluids having the same concentration of stain at all values of pH. It was found desirable to begin at the lowest pH at which the stain does not precipitate and to make the series at 0.5 pH intervals all the way up to pH 12 or to such a pH in the alkaline range at which the stain does not precipitate or become decolorized. The range is, of course, a different one for each stain. Some stains, such as eosin, are not soluble in water at lower values of pH and as they are transformed into a corresponding acid, the latter was used in preference to the salt. Eosinic acid of a high degree of purity may be easily prepared from certified water soluble eosin Y (di-sodium eosinate). Dried and weighed, it can then be dissolved in absolute alcohol and used as a stock solution for the preparation of 0.1% solutions in 50% alcohol by adding the required volumes of HCl or NaOH and water. If desired, one may use aqueous solutions from about pH 5 to pH 12 by dissolving dried eosinic acid in graded solutions of NaOH. It is advisable to measure the pH of each stock solution, as this facilitates a subsequent adjustment of the stain. A

curve is made by plotting the volume of $\frac{N}{10}$ HCl and $\frac{N}{10}$ NaOH against the pH for a constant volume and concentration of the resulting staining solution. Once the curves have been prepared, staining solutions of any desired value of pH may be easily and quickly made from the graph.

In cases of buffered stain solutions one should follow the same procedure because the stain often causes considerable change in the pH value of the buffer solution unless the concentration of the stain is very small.

The next step is the plotting of curves for the density of staining of the various cell components at all values of pH.

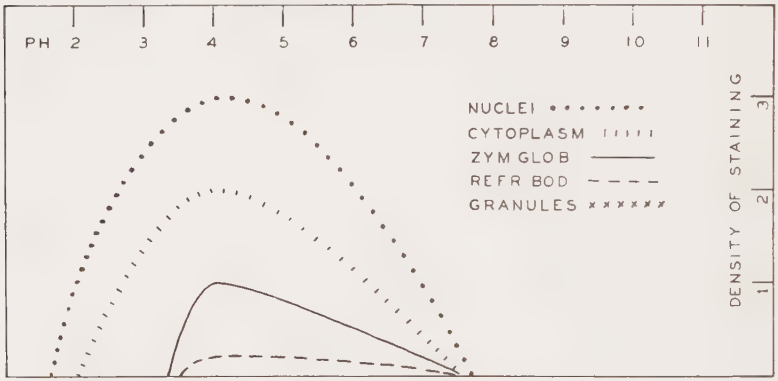

Fig. 1 Methylene blue after paranitroformol.

Color comparators, unless specially designed and constructed for such work, are neither suitable, nor really necessary, because all that one wants to know is the approximate relative density in terms of maximum, medium, slight or zero, when staining is completely absent. Similar curves have been published by other investigators and could be omitted here. However, an interesting feature manifested itself when several curves were compared with each other. This is the presence of an optimum or greatest density of staining at a certain pH, the curve dropping from this point in both directions (fig. 1). Another remarkable feature is that a curve for the same stain used after another fixing fluid may not

only be different in shape, but show a constant rise up to pH 12 (fig. 2). Higher values of pH were not tried because of the deleterious effect on tissues.

An examination of the curves thus constructed, permits at a glance the selection of the pH at which greatest differentiation takes place. Thus for methylene blue after fixation in paranitroformol the differentiation is greatest between pH 2 and pH 3.3, because in this range neither the zymogen globules, nor the refractive bodies are stained.

The last step is the selection of the proper pH value of the buffer solution to be used in destaining. It may be accepted

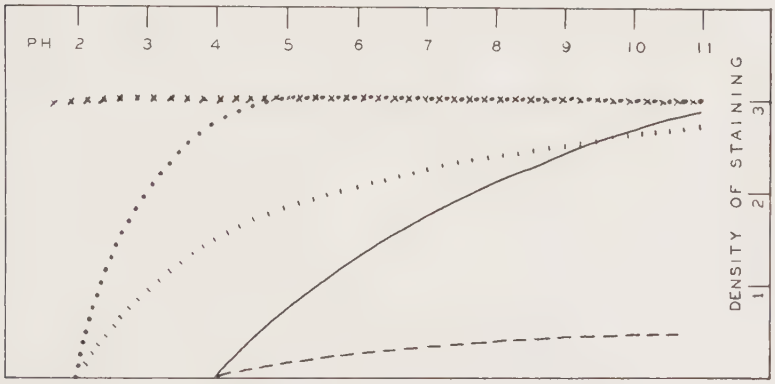

Fig. 2 Methylene blue after Regaud.

as a general rule that the capacity of retaining a stain in a destaining fluid of a given pH is not of the same order as the staining affinity at that pH. A few examples may illustrate this. Acid fuchsin, after fixation in paranitroformol, barely stains at pH 8 and does not stain at all at pH 10. Maximum staining is at pH 2 when all cell organs and inclusions are almost equally dark red. At pH 7 the refractive bodies and zymogen globules are stained below medium density, while nuclei and cytoplasm are of a very faint pink color. But if a section is stained at pH 2, or even at pH 2.85, and then destained for half an hour or more in a buffer solution at pH 7, all cell organs and inclusions loose their color completely,

except the zymogen globules, the refractive bodies and the plasmasomes of interstitial nuclei. They retain their dark red color. In the case of light green the maximum density of staining is between pH 2 and pH 2.5, while no staining of any kind takes place at and above pH 8 after fixation in Regaud. But if a section is stained at pH 2.4 and destained in a buffer solution at pH 8, the zymogen globules remain dark green, while all other cell organs and inclusions become completely decolorized. The same holds true for orange G, only that in this case the refractive bodies as well as the zymogen globules remain colored after fixation in Regaud. After fixation in paranitroformol, staining in orange G at pH 1.8 and washing in a buffer solution at pH 6 the refractive bodies alone remain colored, the rest of the structures losing the color completely.

The analysis of the curves and the capacity of stain retention by certain structures at a pH at which staining is otherwise impossible open the way to correct double staining without intergrading colors. If a staining solution is used, containing a mixture of two stains, one is bound to get intergrading colors because both stains are of necessity used at the same pH no matter what the value of the latter may be. Take for example Wright's blood stain. If one adjusts it to a certain pH, one gets without fail a beautiful double staining of human blood because of the great differences in the isoelectric point and chemical composition of the various cellular structures. Even so, some of them show intergrading colors which do not appear after staining with separate solutions of eosin and methylene blue. If Wright's stain is used for staining other material, such as sections through digestive organs of spiders or vertebrates, one gets besides pure blue and pink all kinds of intermediate purplish colors. This is always the case when the staining optima of both stains coincide or lie close together and the staining affinity of the substratum is more or less of the same order for both stains. But we have seen that staining affinity and capacity to retain stain at certain values of pH are of different order. Herein

as in staining with single stain solutions, the way is open for differentiation without intergrading colors. The stains must be used separately, one after the other at the pH of greatest density and washing after each stain done in fluids having a pH at which stain will be retained only in the desired cellular component. Thus in the case of the digestive organs of the spiders, if the sections are first stained in eosinic acid at pH 2.1, washed in $\frac{N}{10}$ HCl, stained in methylene blue at pH 3.6 to 4 and rinsed in distilled water, only the zymogen globules in the enzyme cells are stained pink, refractive bodies remain colorless, while all the other cell components are stained in various degrees of density of pure blue color. Toluidin blue may be substituted for methylene blue at the same pH with similar result. If it is desirable to retain blue color in nothing but basophilic granules, the second washing solution should have a lower pH. In this case $\frac{N}{100}$ HCl or even $\frac{N}{10}$ HCl should be used. If acid fuchsin is used instead of eosinic acid, the sections should be stained in it at pH 2.8 to pH 3.5 and washed in a buffer solution at pH 7 or 8 depending upon the fixing fluid, then counterstained with either methylene blue or toluidin blue as before.

But this is not the only result which may be achieved by the method here described. An examination of the curves of some stains, such as eosin (fig. 3), orange G (fig. 4) and aniline blue shows that they cross each other at certain values of pH. In the case of eosin all cell components are stained with an equal degree of density. At pH 3 zymogen globules are stained deepest, nuclei and cytoplasm less so and refractive bodies least of all. At pH 10.5 refractive bodies are stained deepest, zymogen globules less so and cytoplasm and nuclei least of all. This permits the use of the same stain, only at a different pH, for differentiation of other cell components. For example, if we stain the sections in eosin at pH 9 (instead of pH 2.15) wash in distilled water and counterstain with methylene blue or toluidin blue as before, the refractive bodies are stained pink, all the other small components presenting different shades of blue, including the zymogen globules which appear light blue.

At first sight, the method appears to be a complicated and troublesome one. In reality its practical application is simple, reliable and free from errors inherent in other methods. Moreover the results are strikingly clear and beautiful. One must remember that each curve is good only for staining after

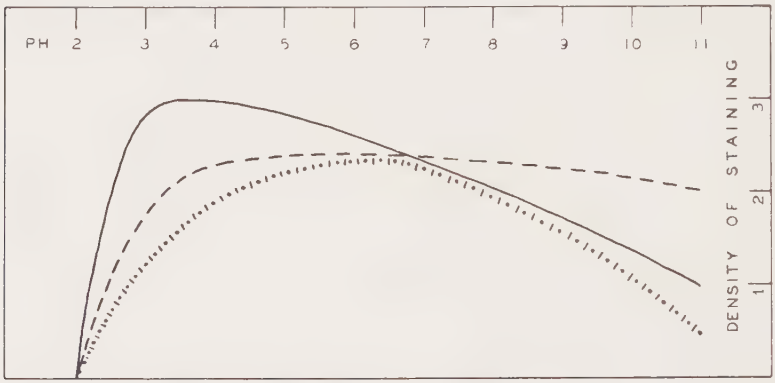

Fig. 3 Eosinic acid after paranitroformol.

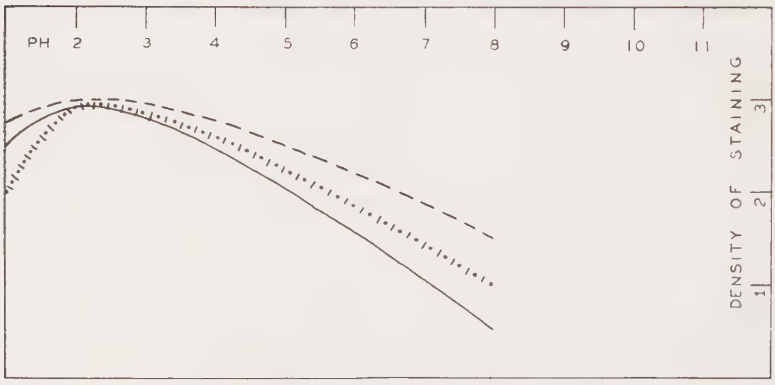

Fig. 4 Orange G after sublimate formol.

the particular fixing fluid for which it was drawn and possibly only for the material which was used. Human or amphibian tissues may require different values of pH of the staining fluids. But once a curve has been made it is not necessary to prepare stains or buffer solutions of the entire series of pH. The optimum value is all that is needed

for stains, while for washing $\frac{N}{10}$ HCl, $\frac{N}{100}$ HCl,[1] buffer solutions of pH 3, 6, 7 and 8 and distilled water will meet all requirements. Selection of a proper pH is done from examination of the curve. Staining may be safely done at room temperature for not less than 1 hour, still better over night. Rinsing in distilled water is not only permissible, but fully warranted whenever the pH of the water (ca. 5.5) comes to lie between that of the stain and the destaining buffer solution. Moreover, such rinsing prevents rapid deterioration of buffer solutions. After final rinsing in distilled water the stained slides are dehydrated in pure dioxan and mounted in dammar. This prevents loss in staining density and leaves the color as permanent as the nature of the respective stain permits. Xylene may be used between dioxan and dammar, if one so desires. Alcohol should be avoided under all circumstances and is not only undesirable on account of its destaining effect on many stains, but also, fortunately, quite unnecessary.

For the convenience of those who may wish to try the method, but lack equipment for proper measurement of pH of colored solutions the following instructions for the preparation of staining fluids of certain pH values may be of use. It must be remembered, however, that samples of even certified stains vary appreciably and that the resulting values of pH may differ from those given here.

Acid fuchsin, 2% aqueous solution—pH 2.85. To make 50 cc. of a 0.25% solution having a pH 2, take 25 cc. of a 0.5% solution, add 0.5 cc. of $\frac{N}{10}$ HCl and dilute with water to 50 cc.

Aniline blue, make a 0.5% stock solution. To prepare a 0.1% aqueous solution having a pH of ca. 7.4 dilute the stock solution with distilled water. To prepare a 0.1% solution having a pH 2, add to 10 cc. of the stock solution 6 cc. of $\frac{N}{10}$ HCl and dilute with water to 50 cc.

Aurantia, 0.1% aqueous solution—pH ca. 6.4. To make a 0.1% solution having a pH 2.4, take 25 cc. of a 0.2% solution

[1] 'Fixanal' reagents of the E. de Haen Company, Germany, Pfaltz and Bauer sole agents for U.S.A., were found to be quite satisfactory.

of aurantia, add 3 cc. of $\frac{N}{10}$ HCl and dilute with distilled water to 50 cc.

Benzoazurine, after paranitroformol fixation gives double staining at pH 5.5 to 6.0. To get a solution having a pH 5.5 make a 0.1% solution of benzoazurine powder in pH 5.5 acetate buffer.

Eosin yellowish in a 0.5% aqueous solution has a pH of ca. 9.5.

Eosinic acid (tetrabromfluorescic acid), stock solution 0.2% in absolute alcohol. To make a 0.1% solution in 50% alcohol having a pH 3.3 take 25 cc. of the stock solution and dilute with distilled water to 50 cc. To make a similar solution having a pH 2.6 take 25 cc. of stock solution, add 2 cc. of $\frac{N}{10}$ HCl and dilute with water to 50 cc. To make a solution having a pH 2.1 take 25 cc. of stock solution, add 7 cc. of $\frac{N}{10}$ HCl and dilute with water to 50 cc. For pH 2.25 use only 5 cc. of $\frac{N}{10}$ HCl.

Light green. To make a 0.1% solution in 50% alcohol having a pH 2.4 take 10 cc. of 0.5% aqueous solution, add 25 cc. of absolute alcohol and 4 cc. of $\frac{N}{10}$ HCl and dilute with water to 50 cc.

Metanil yellow, 1% aqueous solution—ca. pH 8.0. To make a 0.1% solution having pH 2.4 take 25 cc. of a 0.2% aqueous solution, add 3 cc. of $\frac{N}{10}$ HCl and dilute with water to 50 cc. This dye is soluble in dioxan in place of which chloroform should be used.

Methylene blue, U.S.P.—aqueous stock solution 0.5%. To make a 0.25% solution having a pH 4.0 take 25 cc. of stock solution and dilute with water to 50 cc. To make a solution having a pH 3.0 take 25 cc. of stock solution, add 0.5 cc. of $\frac{N}{10}$ HCl and dilute to 50 cc. To make a solution having a pH 2.0 take 25 cc. of stock solution, 5 cc. of $\frac{N}{10}$ HCl and dilute to 50 cc. with water.

Orange G, 0.1% aqueous solution has a pH of ca. 8.4. To make a 0.1% solution having a pH 2.0 take 25 cc. of a 0.2% solution, add 5 cc. of $\frac{N}{10}$ HCl and dilute with water to 50 cc.

Toluidin blue, a 0.1% aqueous solution has a pH ca. 4.3. A 0.1% solution in 50% alcohol has a pH ca. 4.6. To make a

0.1% aqueous solution having a pH 2.1 take 10 cc. of a 0.5% aqueous solution, add 4 cc. of $\frac{N}{10}$ HCl and dilute with water to 50 cc.

Wright's blood stain, to adjust the pH to 7.36 which gives the greatest differentiation with human blood smears make a 1% stock solution by dissolving the powder in pure methyl alcohol and add an equal volume of a phosphate buffer solution pH 6.3.

Double staining with eosin-methylene blue in separate solutions to obtain greatest differentiation without intergrading colors. Pass the blood smear over a flame and fix it for 1 or 2 minutes in pure methyl alcohol. Stain in 0.1% eosinic acid in 50% alcohol, rinse in distilled water, stain in 0.1% solution of methylene blue, U.S.P. in acetate buffer pH 5.5, rinse in water and dry.

For double staining with eosin-methylene blue of oxyntic cells in the stomach of vertebrates, fixed in Zenker's fluid, sublimate formol or paranitroformol, stain the sections in 0.1% eosinic acid in 50% alcohol adjusted to pH 2.2 to 2.3 wash in approximately 0.01 normal hydrochloric acid, rinse in distilled water, stain in 0.1% solution of methylene blue, U.S.P. in acetate buffer pH 4, rinse in distilled water and dehydrate directly in dioxan. Do not expect to obtain the same result at other values of pH.

LITERATURE CITED

Baker, J. R. 1933 Cytological technique. London.

Burke, V. and F. O. Gibson 1933 The Gram reaction and the electric charge of bacteria. J. Bacter., vol. 26, pp. 211–214.

Conn, H. J. 1936 Biological Stains. 3rd ed. Geneva, New York.

Dutton, L. O. 1927 The status of Wright's stain and some suggestions as to its use. Stain Tech., vol. 2, pp. 105–108.

——— 1928 Wright's as a differential stain. Stain Tech., vol. 3, pp. 140–142.

Hatano, Sukehisa and Shigeru Iwata 1933 Hydrogen ion concentration of histiocyte by vital staining with indicator dyes. J. Orient. Med., vol. 19, pp. 823–832, 980–986.

Haynes, R. 1927 Investigation of thiazin dyes as biological stains. I. Stain Tech., vol. 2, pp. 8–16.

——— 1928 Investigation of thiazin dyes on biological stains. II. Stain Tech., vol. 3, pp. 131–139.

HOLMES, W. C. 1929 The mechanism of staining. The case for the physical theories. Stain Tech., vol. 4, pp. 75–80.

JEFFERS, K. R. 1934 Staining reactions of protoplasm and its formed components. A cytological and biochemical study. J. Morph., vol. 56, pp. 101–123.

LASSEUR, PH., A. DUPAIX-LASSEUR AND W. PALGEN 1933 Fixation des colorants par les éléments microbiens. V. Décoloration de quelques solutions colorantes par les suspensions bactériennes. Influence du pH sur la marche du phénomène. Trav. Lab. Microbiol. Fac. Pharm. Nancy, T. 6, pp. 50–54.

LASSEUR, PH. AND M. BENOIT 1934 Observations sur la méthode de Gram. Trav. Lab. Microbiol. Fac. Pharm. Nancy, T. 7, pp. 129–151.

LISON, L. 1936 Histiochemie animale. Paris.

MILLOT, J. 1926 Contribution a l'histophysiologie des aranéides. Suppl. Bull. Biol. France et Belg., T. 8, pp. 1–238.

MILOVIDOV, P. F. 1936 On the distribution of thymonucleic acid in normal and pathologically modified cells; also on the structure, chemical and physico-chemical properties of the cell nucleus. Investigations with the aid of the nucleic reaction. Dissertation published by the author in Russian. Pp. 1–312. Prague.

NAYLOR, E. E. 1926 The hydrogen-ion concentration and the staining of sections of plant tissue. Am. J. Botany, vol. 13, pp. 265–275.

PIETTRE, M. 1933 Floculation, dans l'organisme, des colorants, colloides artificiels chimiquement definis. C. R. Acad. Sci. Paris, T. 196, pp. 298–300.

SEKI, M. 1932 Zur physikalischen Chemie der histologischen Färbung. Folia Anat. Japonica, vol. 10, pp. 621–654.

——— 1934 Studien der electrischen Ladung und Färbbarkeit der Erythrocyten. V. Bestimmung des isoelectrischen Punktes der fixierten Erythrocyten auf färberischem Wege. Zeitschr. Ges. Exp. Med., vol. 94, pp. 655–662.

STEARN, E. W. AND A. E. STEARN 1928 The effect of the chemical nature of a decolorizer on its functioning. Stain Tech., vol. 3, pp. 81–93.

STRUGGER, S. 1932 Ueber das Verhalten des pflanzlichen Zellkernes gegenüber Anilinfarbstoffen. Ein Beitrag zur Methodik der Bestimmung des isoelectrischen Punktes der Kernphasen. Zeitschr. Wiss. Biol., Abt. E., Bd. 18, S. 561–570.

TOLSTOOUHOV, A. V. 1925 Some practical applications of the physicochemical theory of differential staining: Blood, tissue and bacteria staining. Methylene blue eosin water soluble mixtures as an universal dye mixture. Proc. N. Y. Path. Soc., N. S., vol. 25, pp. 147–159.

——— 1928 The effect of preliminary treatment (fixing fluids) on staining properties of the tissues. Stain Tech., vol. 3, pp. 49–56.

——— 1929 Detailed differentiation of bacteria by means of a mixture of acid and basic dyes at different pH values. Stain Tech., vol. 4, pp. 81–89.

UNNA, P. G. 1921 Chromolyse. Abderhalden's Hand. biol. Arbeitsmetoden.

YAMAHA, G. AND T. ISHII 1933 Ueber die Wasserstoffionen Konzentrazion und die isoelectrische Reaction der pflanzlichen Protoplasten, insbesondere des Zellkernes und der Plastiden. Protoplasma, Bd. 19, S. 194–212.

OBSERVATIONS ON THE NATURE OF THE PARAFOLLICULAR CELLS IN THE THYROID GLAND OF THE DOG

A PRELIMINARY NOTE

EMELIA M. VICARI

Department of Anatomy, Cornell University Medical College

ONE PLATE (FIVE FIGURES)

During a study of sections of thyroid glands made on pure bred and hybrid dogs from Dr. C. R. Stockard's Experimental Colony a survey of the variations in abundance and locus of the so-called parafollicular cells has brought out certain facts which may throw light on the nature of these cells.

The long known Wölfler's interfollicular epithelial cells of the thyroid have been observed by various workers: Wegelin, Webber, Bernard, Florentin, Nonidez and Zechel. In general these cells have been considered to be undifferentiated elements of embryonic nature. However, in recent years the opinion has been against this view. The current belief is that the cells arise individually from the follicular epithelium or they may arise as groups if F. Thomas's 'cellules des follicules satellites' described in the human thyroid can be regarded as true interfollicular cells.

I observed these interfollicular cells in the thyroid of an adult female Boston terrier in 1929. They were in clusters between the follicles, and mainly outside the follicular epithelium. The thyroid of this animal had been fixed immediately after death in Bouin's fluid and stained with haematoxylin and eosin. The cells were sharply outlined. I have since found these cells to show variations in number in the different dog breeds and at different ages.

In 1932 Doctor Nonidez of this laboratory reported the fact that these cells can be impregnated with silver nitrate. He

termed the cells parafollicular "since they lie in the interstitial spaces in close proximity to the follicles from the epithelium of which they arose."

In order to study these cells by this new method of differentiation with silver nitrate, a series of thyroids from different breeds of dogs were fixed in alcohol-chloral hydrate and impregnated with the reduced silver nitrate method of Cajal. Also for comparison, a part of each thyroid was fixed in Bouin's fluid and part in Zenker-formol.

The study of this material has shown constant differences in numbers of parafollicular cells in the thyroid of various breeds. Certain breeds, such as the Boston terrier, showed more of these cells while other breeds as, for instance, the St. Bernard showed fewer.

More recently in a survey of thyroids from female dogs during oestrus and pregnancy the parafollicular cells are seen in great abundance and arranged in large clusters. The excess of the parafollicular cells during oestrus and pregnancy might be interpreted as being the result of the increase in the activity of the thyroids during these physiologic conditions.

In a year-old female, a dachshund-cocker spaniel hybrid which was in oestrus at time of killing, the thyroid showed a number of parafollicular cells. There was also a mass of such cells in a partially external parathyroid. A cross section through this mass of parafollicular cells is shown in a low power photomicrograph, figure 1. The mass of parafollicular cells, labeled a, is buried in the parathyroid and the relation of this parathyroid to the thyroid is shown. The left border of the parathyroid lies adjacent to the thyroid gland.

Figure 2 shows a higher power of this mass of parafollicular cells in the parathyroid gland with the adjacent thyroid tissue. In the interfollicular spaces of the thyroid and also leaving the follicular wall are seen parafollicular cells impregnated with silver nitrate. The region labeled *a* shows six such parafollicular cells around two follicles. The regions labeled *b* and *c* show groups of parafollicular cells in the parathyroid gland.

Figures 3, 4 and 5 show much higher magnifications of the cells labeled *a*, *b* and *c* in figure 2. Close inspection of these parafollicular cells both in the parathyroid and thyroid glands leaves no doubt that they are the same kind of cells; both show the clear nucleus and the argyrophilic granules in the cytoplasm.

The presence of parafollicular cells in the parathyroid gland has not been noted by previous investigators. This might be attributed to their rare occurrence. With regard to their localization in the parathyroid one possibility is that these cells have migrated from the thyroid into the parathyroid. Another possibility is the occurrence of an embryonic thyroid follicle in the parathyroid.

One hundred and two cross sections (7 μ in thickness) were used in a study of this parathyroid gland. The mass of parafollicular cells began with the twenty-eighth section and continued through the sixty-second section. The parafollicular mass of cells within the parathyroid gland was surrounded by parathyroid tissue in which no migrating parafollicular cells could be definitely detected.

The presence of parafollicular cells in the parathyroid gland in the absence of thyroid follicles does not favor Thomas' opinion regarding the formation of interfollicular cells by budding or breaking away of a diverticulum from the epithelial wall of a thyroid follicle. The observations rather favor Nonidez's belief of a migration of differentiated follicular cells into interfollicular spaces.

LITERATURE CITED

NONIDEZ, J. F. 1932 The origin of the 'parafollicular' cell, a second epithelial component of the thyroid of the dog. Am. J. Anat., vol. 49, p. 479.

——— 1932 Further observations on the parafollicular cells of the mammalian thyroid. Anat. Rec., vol. 53, p. 339.

THOMAS, FÉDÉRIC 1934 L'histophysiologie de la glande thyroide humaine à la lumiére de tests morphologiques nouveaux. Arch. de Biol., T. 45, p. 189.

VICARI, E. M. 1936 Variations in abundance of the parafollicular thyroid cells of the dog. Anat. Rec., vol. 64, suppl. no. 3, p. 53.

——— 1936 Parafollicular thyroid cells in pregnant dogs. Anat. Rec., vol. 67, p. 6.

PLATE 1

EXPLANATION OF FIGURES

All figures in this plate are unretouched photomicrographs of the thyroid and parathyroid glands of an adult female dog. Alcohol-chloral hydrate fixation and silver nitrate impregnation.

1 Low power, × 30, showing location of the mass of parafollicular cells, labeled a, buried in the parathyroid gland. At the left and adjacent to the parathyroid lies the thyroid gland. At the right the parathyroid shows a free surface, external to the thyroid.

2 A higher magnification, × 280, showing at the right the mass of parafollicular cells in the parathyroid gland. At the left are parafollicular cells singly and in clusters among thyroid follicles. Parafollicular cells labeled a, b, c are shown under much higher powers in figures 3, 4 and 5.

3 Much higher magnification, × 2000, of the parafollicular cells around the two thyroid follicles labeled a, in figure 2. They have just left the follicular wall. Note the argyrophilic granules in their cytoplasm.

4 and 5 High power, the same as figure 3, × 2000, of the parafollicular cells in the parathyroid labeled b and c in figure 2, showing their cytoplasmic argyrophilic granules.

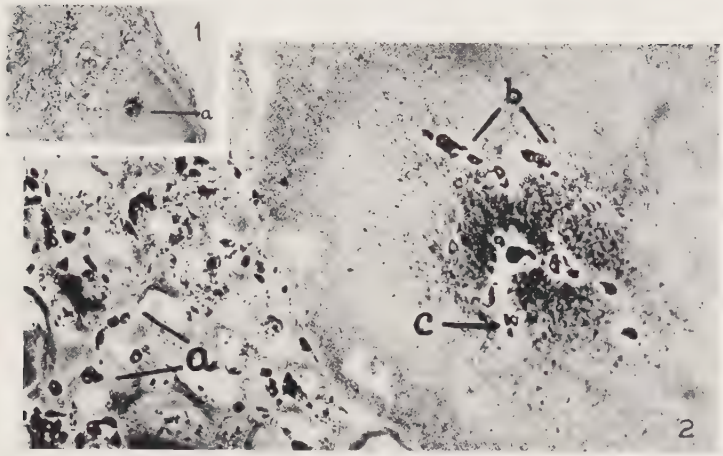
1
a
b
c
a
2

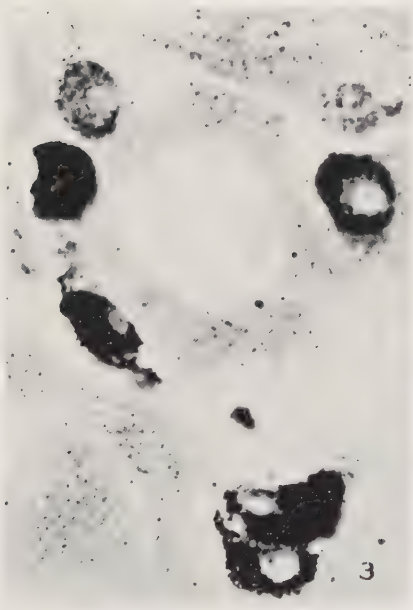
3

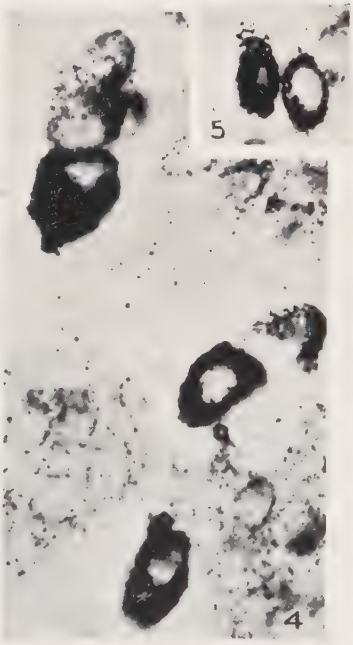
5
4

THE STRUCTURE OF THE NEPHRON IN FISHES

REPRESENTATIVE TYPES OF NEPHRON ENCOUNTERED; THE PROBLEM OF HOMOLOGIES AMONG THE DIFFERENTIATED PORTIONS OF THE PROXIMAL CONVOLUTED SEGMENT

ALLAN L. GRAFFLIN
Department of Anatomy, Harvard Medical School

SIX TEXT FIGURES AND ONE PLATE (FOUR FIGURES)

The work of many investigators has demonstrated a wide diversity in the structure of the nephron in fishes. All variations have been described from an aglomerular nephron, composed only of a proximal convoluted segment, to a nephron of the order of complexity found in amphibia. Many of the recent contributions to this problem are listed at the end of this report. In these contributions adequate references to the older literature will be found. It is the purpose of the present paper 1) to discuss certain representative types of nephron encountered in the fishes; 2) to consider, in these representative nephrons, the problem of homologies among the differentiated portions of the proximal convoluted segment. Sufficient information is not yet at hand to allow us to make all-inclusive generalizations concerning the structure of the nephron in fishes. Under the circumstances, the present discussion will be limited primarily to four species with which I am personally well acquainted, and for which fairly adequate histological data are available: Opsanus tau (marine teleost), Myoxocephalus octodecimspinosus (marine teleost), Anguilla rostrata (euryhaline teleost) and Lepidosiren paradoxa (lungfish, fresh water).

For the purposes of this discussion, the following terminology for the various subdivisions of the nephron will be

employed: 1) Glomerulus. 2) Neck segment. 3) Proximal convoluted segment, including that entire portion of the nephron lined by epithelium provided with brush border. In three of the species considered in detail—Myoxocephalus, Anguilla, Lepidosiren—this segment is subdivided into two histologically distinct portions; these will be referred to simply as the first and second portions of the proximal convoluted segment. 4) Ciliated intermediate segment. 5) Distal convoluted segment. 6) Initial collecting segment, a short terminal segment continuous distally, at a dichotomous branching, with a collecting tubule. Such a segment is typically present in all vertebrate nephrons; it is usually regarded merely as a conduit, and will be so considered for the purposes of the present report.[1]

As a basis for the subsequent discussion, essential histological data concerning the four nephrons under consideration will now be given.

Opsanus tau (toadfish)

The structure of the nephron in this species has been the subject of several investigations, and the available information may be summarized as follows:

The nephron is aglomerular, and was first described by Marshall ('29): "The greater part of the tubule beginning from the blind ending is lined with high, cuboidal, rodded epithelium, while at the lower end there is a transition to a low cuboidal, more basophilic epithelium without striations. This basophilic segment is extremely short and can be easily traced into a collecting duct." In sections Marshall was able to demonstrate brush border on the rodded epithelium 'in practically every case.' However, he stated that "it is quite possible that there may be a small segment of the tubule with rodded epithelium but without brush border, but this can only be definitely settled by a careful reconstruction from thin sections." The nephron was subsequently reconstructed in wax (fig. 1) by Grafflin ('31), who reported as follows: "Investigation of the present material has demonstrated conclusively that in the toadfish the cells of the renal tubule, to

[1] See, however, Cordier ('29) and Defrise ('32 a), who, on cytological grounds, suggest the possible participation of this segment in the elaboration of the urine.

the point of junction with the collecting tubule, are invariably provided with brush border. It is therefore definitely proved that there is no segment devoid of brush border.'' The wording here is unfortunate and confusing, but the meaning is clear enough when one compares the reports of Marshall and of Grafflin. Collecting tubule, as used by the latter, obviously refers to the initial collecting tubule or initial collecting segment as designated in the present account. Such a segment was identified by Marshall, was present (though quite short—see table 1) in the nephron reconstructed by me, and was included in the schematic representation of the nephron in a subsequent publication (Marshall and Grafflin, '32), in which the designation collecting tubule was unfortunately perpetuated. The statement quoted above, ''that there is no segment devoid of brush border,'' refers to the major portion of the nephron, exclusive of the initial collecting segment which exhibits no brush border.

These investigations established the following structure for the toadfish nephron: 1) proximal convoluted segment, 2) initial collecting segment. Convincing evidence that the proximal convoluted segment exhibits only one fundamental type of cell was supplied by Defrise ('32 a), whose pertinent observations for the normal animal may be briefly quoted: ''The toadfish nephron is unisegmental and composed of only one type of epithelial cell [2] . . . . The chondriome . . . . is irregularly arranged and spread throughout the cytoplasm . . . . The substance O of the Golgi complex . . . . consists of voluminous, rather spherical masses, variable in number, volume, and position, depending upon the functional condition of the cell.'' The chondriome as illustrated from fixed material (see his fig. 3) consists of rather delicate filaments, not very long, which exhibit a tendency to vertical orientation. In fresh material (see his fig. 1) the basal portion of the cell exhibits marked vertical striation, and elsewhere ('32 b) Defrise specifically refers to the 'prevalently vertical disposition' of the mitochondria in supravital preparations stained with Janus green.[3] Edwards ('33 b) confirms, on histological

[2] Here again he is referring to the nephron exclusive of the initial collecting segment, which he identified.

[3] Defrise ('32 a) also reports the presence of a flagellated diplosome for the cells of the proximal convoluted segment, and comments upon the variations in the appearance of the brush border. The reader should consult his two reports in Italian ('32 b, '32 c), which supplement in certain respects the data given in '32 a.

grounds, the presence in the proximal convoluted segment of only one type of cell, which he characterizes as columnar and as staining readily with eosin.

In summary, the nephron of the toadfish is aglomerular and has the following structure: 1) proximal convoluted segment (of one cell type), and 2) initial collecting segment.

Myoxocephalus octodecimspinosus (sculpin)

As established elsewhere (Grafflin, '37 a), the nephron of the sculpin exhibits typically the following structure: 1) glomerulus, 2) ciliated neck segment, 3) proximal convoluted segment, and 4) initial collecting segment. The proximal convoluted segment is further subdivided into two distinct portions, the transition between which is typically abrupt histologically; scattered isolated ciliated cells occur along both portions of this segment. The available literature upon the sculpin nephron is summarized in the paper referred to above.

Anguilla rostrata (common eel)

The nephron of this species has been made the subject of a detailed study (Grafflin, '37 b), and has the following structure: 1) glomerulus, 2) ciliated neck segment, 3) proximal convoluted segment, 4) distal convoluted segment, and 5) initial collecting segment. The proximal convoluted segment is further subdivided into two distinct portions, the transition between them being histologically abrupt. Scattered isolated ciliated cells are present along both portions of this segment; although these ciliated cells are present in large numbers at the distal end of the second portion, a true ciliated intermediate segment, between the proximal and distal convoluted segments, does not occur. My findings differ, to some extent, from those of Defrise ('34) for the nephron of Anguilla vulgaris, and these differences are discussed in the paper referred to (also, see below).

Lepidosiren paradoxa (South American lungfish)

The nephron of Lepidosiren was first studied by Bargmann ('34), and has been investigated more recently, in this laboratory, by Guyton ('35), who reported the following structure: 1) glomerulus, 2) ciliated neck segment, 3) proximal convoluted segment, 4) ciliated intermediate segment, 5) distal convoluted segment, and 6) initial collecting segment. The

proximal convoluted segment is further subdivided into two distinct portions, the transition between which is essentially abrupt histologically; scattered isolated ciliated cells occur along the second portion of this segment.

Bargmann's and Guyton's observations are in essential agreement except with respect to the presence of a ciliated intermediate segment. Guyton identified such a segment and illustrated it (see his fig. 12); Bargmann, on the other hand, denied its presence in his specimens. In a re-examination of Guyton's material I have fully confirmed his interpretation. In every instance so far studied, the distal convoluted segment is immediately preceded by a short portion of the nephron in which every cell is provided with cilia and is devoid of brush border. On histological grounds this portion should certainly be designated as a ciliated intermediate segment. On the other hand, this might perhaps be considered a more or less academic question in Lepidosiren in the following sense. Guyton and Bargmann have already reported the presence of isolated ciliated cells along the second portion of the proximal convoluted segment, and Guyton has described their increase in frequency as one passes from the proximal to the distal end of this second portion. At the distal end the typical cells of the second portion are gradually crowded out more and more by the ciliated cells until finally only the latter remain. The fully ciliated portion is quite variable in length and in some cases is exceedingly short. The steady increase in number of ciliated cells is such that Guyton's statement, "the transition from this second portion of the proximal to the ciliated intermediate segment is quite sharp," is hardly adequate. The pictures observed in this region are so variable that one gets the distinct impression that the ultimate complete exclusion of the typical cells of the second portion might be largely a matter of chance. However, a careful search of material from both of Guyton's specimens has failed to reveal a single instance in which a fully ciliated portion does not occur.

I have been unable to obtain additional specimens of Lepidosiren for a more extended study of the question. The disagreement between Guyton's and Bargmann's findings cannot be attributed to a sex difference; our specimens are of both sexes, so are Bargmann's. Neither apparently can it be explained on the basis of a species difference; there is no evidence up to the present time of more than one species of Lepidosiren.

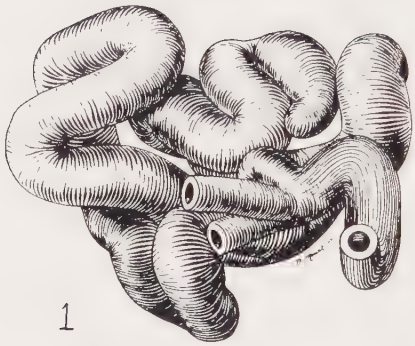

1

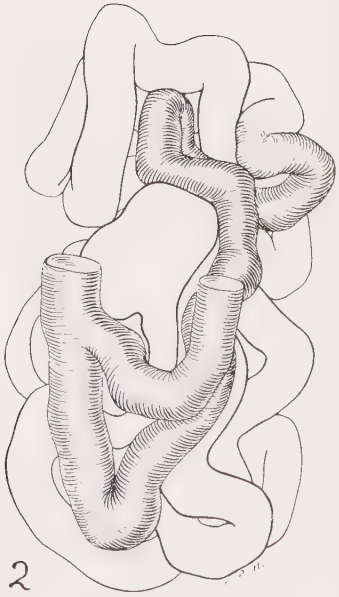

2

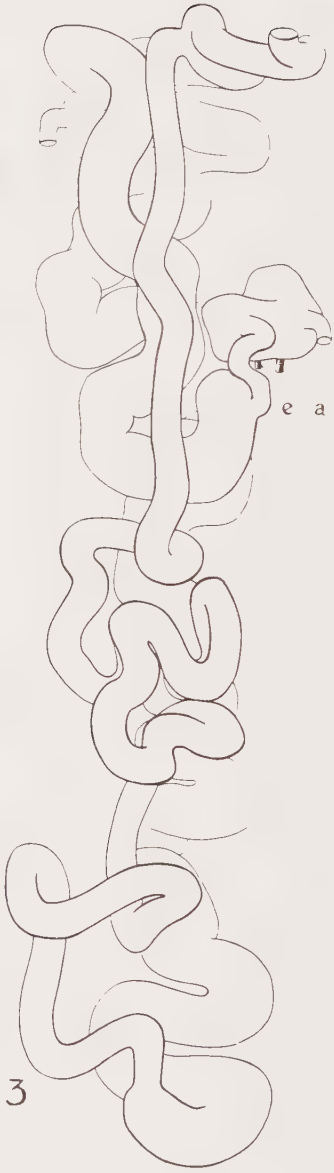

3

For three of the species under consideration—toadfish, eel and lungfish—a wax reconstruction of the nephron is available, and drawings of the wax models, from the sources indicated, are reproduced in figures 1 to 3. The measurements of the various subdivisions of the nephrons illustrated have been brought together in table 1. The detailed measurements for the toadfish nephron are published here for the first time. In this particular instance the initial collecting segment is

TABLE 1

Measurements of nephrons, reconstructed in wax, of Opsanus tau, Anguilla rostrata and Lepidosiren paradoxa

	OPSANUS TAU	ANGUILLA ROSTRATA	LEPIDOSIREN PARADOXA
Glomerulus	Absent	0.055 × 0.056	0.180 × 0.20
Ciliated neck segment	Absent	0.027 × 0.070	0.045 × 0.30
Proximal convoluted segment	0.050 × 2.485	0.042 × 3.656	0.115 × 9.05
First portion		*0.041 × 1.137*	*0.120 × 4.55*
Second portion		*0.042 × 2.519*	*0.110 × 4.50*
Ciliated intermediate segment	Absent	Absent	0.055 × 0.20
Distal convoluted segment	Absent	0.038 × 0.673	0.070 × 6.00
Initial collecting segment	0.035 × 0.015	0.047 × 0.200	0.065 × 1.40
Total length of nephron	2.500	4.655	17.14

All dimensions in millimeters; for all segments the average diameter is given first, the length second.

much shorter than in the majority of instances which I have examined. Defrise ('32 b) likewise reconstructed the toadfish nephron, and states that the length is approximately 1.0 mm., and that the diameter varies between 20 and 40 μ. Marshall's ('34) measurements are clearly taken, primarily at least,

Figs. 1 to 3 Drawings of nephrons, reconstructed in wax, from which the measurements given in table 1 were taken. Figure 1, Opsanus tau (from Grafflin, '31); figure 2, Anguilla rostrata (from Grafflin, '37 b); figure 3, Lepidosiren paradoxa (from Guyton, '35). Figures 1 and 2 are reproduced at the same magnification (× 160) for direct comparison. Because of the large size of the Lepidosiren nephron, figure 3 is reproduced at one-third of this magnification, or × 53⅓. The shaded portion of the nephron in figure 2 comprises the distal convoluted and initial collecting segments. In figure 3 the renal tubule takes origin from one of a pair of closely adjacent glomeruli (a and e, afferent and efferent vessels).

from maceration material, and I consider them to be abnormally high with respect to both length and diameter. Edwards ('33 b), without reconstruction, states that the initial collecting segment constitutes about one-tenth of the total length of the nephron. The measurements of the eel and lungfish nephrons are taken from Grafflin ('37 b) and Guyton ('35), respectively. Defrise ('34) reconstructed the nephron of Anguilla vulgaris in wax, but gives no accurate measurements. Cordier ('29) reconstructed the nephron of the African lungfish (Protopterus sp.), but likewise gives no measurements.[4] For the sculpin no wax reconstruction is available. The measurements of total length of the nephron, given by Nash ('31) and Grafflin ('37 a) from maceration material, must be considered abnormally high, and are in no sense comparable with the measurements obtained from wax reconstruction in the other species. The same criticism applies to the measurements of the subdivisions of the sculpin nephron given by Marshall ('34). Edwards ('35), without reconstruction, states that the first portion of the proximal convoluted segment in the sculpin is shorter than the second portion.

In the toadfish, sculpin, eel and lungfish we have four represensative types of nephron. In terms of their fundamental subdivisions they are all different, and exhibit a steady progression in complexity in the order given above. In order to emphasize the differences in their structure, these nephrons are schematically represented in figure 4. For the sake of clarity, the subdivision of the proximal convoluted segment—in the sculpin, eel and lungfish—into two histologically distinct portions has been neglected in the preparation of this figure (see below).

[4] Though his terminology is different, Cordier established the same essential structure of the nephron in Protopterus as Guyton subsequently established for Lepidosiren.

The problem of homologies among the differentiated portions of the proximal convoluted segment

As discussed above, the proximal convoluted segment in the toadfish exhibits only one cell type, whereas this segment in the sculpin, eel and lungfish shows a differentiation into two histologically distinct portions. The question arises as to

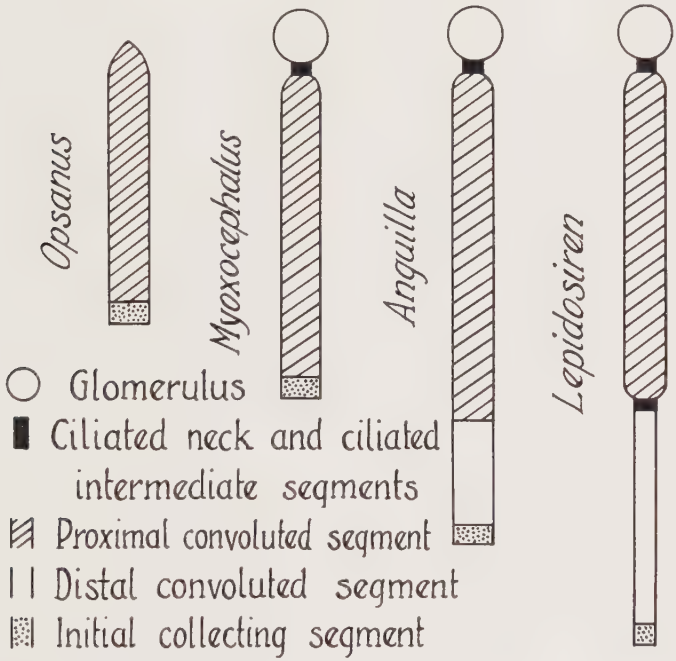

Fig. 4 Schematic representation of the nephrons of Opsanus, Myoxocephalus, Anguilla and Lepidosiren.

what fundamental homologies, if any, exist between these differentiated portions in the four representative nephrons under consideration. In the sculpin and eel it seems perfectly clear, on histological grounds, that the lightly staining first portions of the proximal convoluted segments in these two species constitute one homology; and that the deeply staining, more highly organized second portions constitute a second homology. Furthermore, there can be no doubt that the

proximal convoluted segment (of one cell type) in the toadfish nephron is homologous with the second portions of this segment in the sculpin and eel, and is markedly dissimilar in structure to the first portions in the latter two species.

The above homology in the toadfish and sculpin is implicit, though not expressed, in the observations of Defrise ('32 a) upon the morphology of the Golgi substance. The appearance of this substance in the toadfish (Golgi masses) is directly

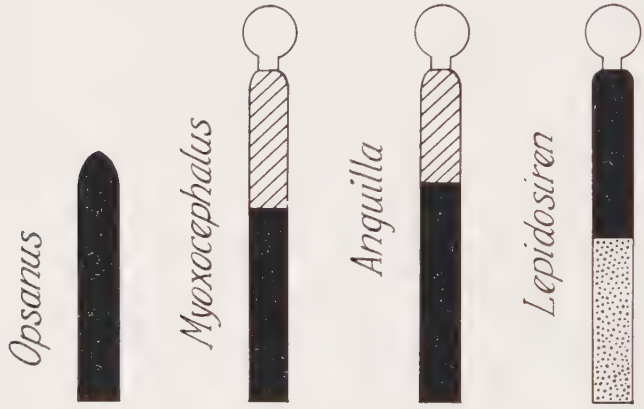

Fig. 5 Schematic representation of the differentiated portions of the proximal convoluted segment in Opsanus, Myoxocephalus, Anguilla and Lepidosiren. The portions shown in solid black are considered to be fundamentally homologous. The first portions of the segment in Myoxocephalus and Anguilla (diagonally lined) are considered to constitute a second homology. The second portion of the segment in Lepidosiren (stippled) is not homologous with any portion of the proximal convoluted segment in the teleosts.

comparable with that in the second portion of the sculpin, but entirely dissimilar to that in the first portion (Golgi rods). Defrise's ('34) subsequent observations upon the Golgi substance in the nephron of Anguilla (for re-interpretation of his conception of the structure of the nephron see Grafflin, '37 b) do not, however, bear out the homologies drawn between sculpin and eel. The first portion in the eel shows Golgi masses, the second portion Golgi rods. The above fundamental homologies have been drawn with a full knowledge of, and despite, this discrepancy.

If, now, we attempt to extend our homologies to include the lungfish, the problem is more complicated. In Lepidosiren the order of the lightly staining and deeply staining portions (speaking in very general terms) of the proximal convoluted segment, compared with the situation in the sculpin and eel, is reversed, the deeply staining portion following directly upon the neck segment. To the histological observations of Bargmann ('34) and Guyton ('35) upon these two portions are to be added the cytological data contained in figures 7 to 10. Histologically and cytologically, the structure of the second portion is so striking and unique that it most emphatically is not homologous with either of the differentiated portions of the proximal convoluted segment in the sculpin and eel. With respect to the first portion in Lepidosiren, it admittedly shows certain distinctive features not encountered in the nephrons of the teleosts. Nevertheless, if any fundamental homology exists, and I believe that it does, this first portion is homologous with the second portion of the proximal convoluted segment in the sculpin and eel.

For the sake of clarity, the above considerations with respect to homologies among the differentiated portions of the proximal convoluted segment are schematically illustrated in figure 5.

DISCUSSION

An abundance of information concerning the structure of the nephron in fishes has been supplied by Edwards (see particularly '28, '29, '33 b, '35). That there is a wide variation in the teleosts has been amply demonstrated by his observations and by the work of others (for a broad statement of the problem see Marshall, '34). The one portion of the nephron which is always present in the fishes is the proximal convoluted segment. For the teleosts two generalizations concerning the other subdivisions of the nephron emerge from the work of Edwards: 1) that in typical marine teleosts, the nephrons of which may be glomerular or aglomerular, a distal convoluted segment is regularly absent; 2) that in typical

fresh water teleosts, the nephrons of which are glomerular, a distal convoluted segment is regularly present (Edwards, '32, '33 a, '33 b, '35).[5] From the data of Edwards and of Policard and Mawas ('06), a specialized neck segment may



Fig. 6 Drawing of wax model of nephron in fresh water catfish, Ameiurus nebulosus, reproduced at × 160 for direct comparison with figures 1 and 2.

be present or absent, and when present may or may not be ciliated; also, a ciliated intermediate segment may or may not be present.

[5] Several years ago I reconstructed in wax the nephron of the fresh water catfish, Ameiurus nebulosus. This reconstruction served as a basis for no. 4 in Marshall's schema (Marshall, '34, fig. 1), and from it the dimensions of the essential subdivisions of the nephron were taken, as recorded in his table 1. A drawing of the wax model, to show the general morphology of the nephron, is given in figure 6. Histologically the nephron is very complicated, and will require a far more thorough study than I have yet been able to carry out. Until such a study is carried out, final judgment concerning the structure of the nephron in this species should be reserved, particularly with respect to the presence of a true ciliated intermediate segment. The reason for publishing this drawing at the present time is that I will have no opportunity to complete the study for some time to come.

The subdivision of the proximal convoluted segment (in the glomerular teleosts) into histologically distinct portions was discovered by Edwards and has been repeatedly emphasized by him. He has concluded that in the fresh water teleosts this segment is consistently subdivided into two portions; and from his data the first portion is typically more lightly staining, the second more deeply staining, comparable to the two portions in the eel, with which they are presumably homologous. Edwards' observations upon the glomerular marine teleosts indicate a lack of uniformity in the differentiation of the proximal convoluted segment, although at least two distinct portions are regularly present. In the aglomerular teleostean nephrons the proximal convoluted segment shows no such differentiation, but exhibits only one type of cell (see discussion above; Edwards, '35; von Möllendorff, '36). One would be inclined to believe that this segment is presumably homologous in all of the aglomerular nephrons, but final judgment must be reserved until more adequate data are available.

If, now, we consider, on the basis of the foregoing statements, the four species particularly discussed above, we may conclude 1) that the toadfish and sculpin nephrons are to be regarded as two representative types (aglomerular and glomerular) of marine teleostean nephrons; 2) that the nephron of the euryhaline eel is to be regarded as one representative type of the fresh water teleostean nephrons; 3) that although the Lepidosiren nephron, in terms of its fundamental subdivisions, is comparable to a second representative type of fresh water teleostean nephrons, the histological structure of its proximal convoluted segment is such that this nephron is not to be regarded as strictly homologous with any nephron so far observed in the teleosts.

With respect to the proximal convoluted segment in the vertebrates above the fishes, the following facts are pertinent: 1) There is as yet no evidence to indicate the subdivision of this segment into histologically distinct portions in amphibia,

reptiles or birds (Edwards, '33 b, '35). 2) The available data do indicate a subdivision of this segment in the mammals into at least two distinct portions (for discussion see Foote, '36). The situation in the mammals is being actively investigated in this laboratory at the present time, but the study is far from complete. In view of the wide gap between the fishes and the mammals, and of the inadequacy of our information, any attempt to extend to the mammals the homologies drawn above for the fishes would be premature. Obviously, a great deal more work must be done before any adequate story of the evolution of the vertebrate nephron can be written. In particular, the proximal convoluted segment in the nephrons of amphibia, reptiles and birds should be re-investigated from the standpoint of its finer histology and cytology.[6]

SUMMARY

The structure of the nephron in fishes is discussed primarily with respect to four species: Opsanus tau (toadfish), Myoxocephalus octodecimspinosus (sculpin), Anguilla rostrata (common eel), and Lepidosiren paradoxa (South American lungfish). In terms of their fundamental subdivisions the four nephrons are all different, and exhibit a steady progression in complexity in the order given. The nephrons are discussed from the standpoint of representative types. On histological grounds it is concluded 1) that the first portions of the proximal convoluted segment in the sculpin and eel are homologous; 2) that the proximal convoluted segment (of one cell type) in the toadfish is homologous with the second portions of the proximal convoluted segment in the sculpin and eel, and with the first portion of this segment in the lungfish; 3) that the second portion of the proximal convoluted segment in the lungfish is not homologous with any portion of this segment so far observed in the teleosts.

[6] MacNider has suggested that the mammalian kidney, as a result of glomerular obliteration by a disease associated with modification in its blood supply, may in areas revert back to a histological structure normal for the aglomerular fish kidney, Opsanus tau (Proc. Soc. Exp. Biol. and Med., 1933, vol. 31, p. 293).

LITERATURE CITED

BARGMANN, W. 1934 Untersuchungen über Histologie und Histophysiologie der Fischniere. I. Dipnoer: Lepidosiren paradoxa. Zeit. f. Zellforsch. u. mikr. Anat., Bd. 21, S. 388–411.

CORDIER, R. 1929 Le tube urinaire du Protoptère (Dipneuste). Compt. rend. de l'Assoc. des Anat., 24e Réunion, Bordeaux, pp. 157–165.

DEFRISE, A. 1932 a Cytophysiological studies of the nephrocytes of unisegmental aglomerular and glomerular nephrons. Anat. Rec., vol. 54, pp. 185–195.

——— 1932 b Struttura del nefrone aglomerulare di Opsanus tau. Boll. Soc. Ital. di Biol. Sper., vol. 7, pp. 1043–1047.

——— 1932 c Citofisiologia di nefroni aglomerulari. Monitore Zool., vol. 43 (supplement), pp. 115–118.

——— 1934 Ricerche di citofisiologica renale. Il nefrone bisegmentale. Arch. Ital. di Anat. e di Embriol., T. 33, pp. 693–717.

EDWARDS, J. G. 1928 Studies on aglomerular and glomerular kidneys. I. Anatomical. Am. J. Anat., vol. 42, pp. 75–107.

——— 1929 Studies on aglomerular and glomerular kidneys. III. Cytological. Anat. Rec., vol. 44, pp. 15–27.

——— 1932 The excretion of iron salts by the kidney of vertebrates. Ibid., vol. 52 (supplement), p. 12.

——— 1933 a Functional sites and morphological differentiation in the renal tubule. Ibid., vol. 55, pp. 343–367.

——— 1933 b (Assisted by C. Schnitter). The renal unit in the kidney of vertebrates. Am. J. Anat., vol. 53, pp. 55–87.

——— 1935 The epithelium of the renal tubule in bony fish. Anat. Rec., vol. 63, pp. 263–279.

FOOTE, J. J. 1936 Segmental differentiation in the proximal convoluted tubule of the mammalian nephron. Proc. Soc. Exp. Biol. and Med., vol. 34, pp. 196–198.

GRAFFLIN, A. L. 1931 The structure of the renal tubule of the toadfish. Bull. Johns Hopkins Hosp., vol. 48, pp. 269–270.

——— 1937 a The structure of the nephron in the sculpin, Myoxocephalus octodecimspinosus. Anat. Rec., vol. 68, pp. 145–163.

——— 1937 b Observations upon the structure of the nephron in the common eel. Am. J. Anat., vol. 61, pp. 21–62.

GUYTON, J. S. 1935 The structure of the nephron in the South American lungfish, Lepidosiren paradoxa. Anat. Rec., vol. 63, pp. 213–229.

MARSHALL, E. K., JR. 1929 The aglomerular kidney of the toadfish (Opsanus tau). Bull. Johns Hopkins Hosp., vol. 45, pp. 95–101.

——— 1934 The comparative physiology of the kidney in relation to theories of renal secretion. Physiol. Rev., vol. 14, pp. 133–159.

MARSHALL, E. K., JR. AND A. L. GRAFFLIN 1932 The function of the proximal convoluted segment of the renal tubule. J. Cell. and Comp. Physiol., vol. 1, pp. 161–176.

von Möllendorff, W. 1936 Zur Histophysiologie der Nieren von Hippocampus guttulatus und Lepadogaster Candollii. Zeit. f. Zellforsch. u. mikr. Anat., Bd. 24, S. 204–226.

Nash, J. 1931 The number and size of glomeruli in the kidneys of fishes, with observations on the morphology of the renal tubules of fishes. Am. J. Anat., vol. 47, pp. 425–445.

Policard, A. and J. Mawas 1906 Le canalicule urinaire des téléostéens. Bibl. Anat., vol. 15, pp. 215–221.

PLATE 1

EXPLANATION OF FIGURES

Lepidosiren paradoxa: cytological details of the cells of the first and second portions of the proximal convoluted segment. The delicacy of the preparations is such that repeated attempts to obtain adequate photomicrographs have failed. I am indebted to Miss Piotti for the painstaking fidelity with which she has reproduced the appearances in the original sections. The material was fixed in Champy's fluid, sectioned at 5 μ, and stained with iron hematoxylin and orange G.

7 Cross section of first portion of proximal convoluted segment, showing a fortunate, and apparently complete, demonstration of the delicately filamentous mitochondria. $\times$ 920.

8 A single cell of the first portion of the proximal convoluted segment, to which attention was attracted by the striking character of the brush border. The appearance is analogous to the 'Porensaum' pictures of von Möllendorff. The cytoplasm and chondriome are markedly modified. This cell represents an isolated finding in the present material. $\times$ 2060.

9 and 10 Portions of two cells of the second portion of the proximal convoluted segment, to show the markedly vacuolated cytoplasm and the mitochondria, which are relatively few in number. Cordier ('29) demonstrated an apical concentration of the mitochondria in the cells of the homologous portion of the nephron in Protopterus. An analogous picture has not been observed in the present material. $\times$ 1300.

7
E. Rott.

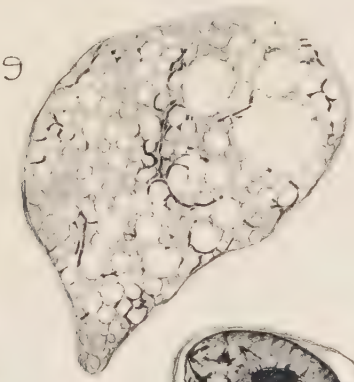
9

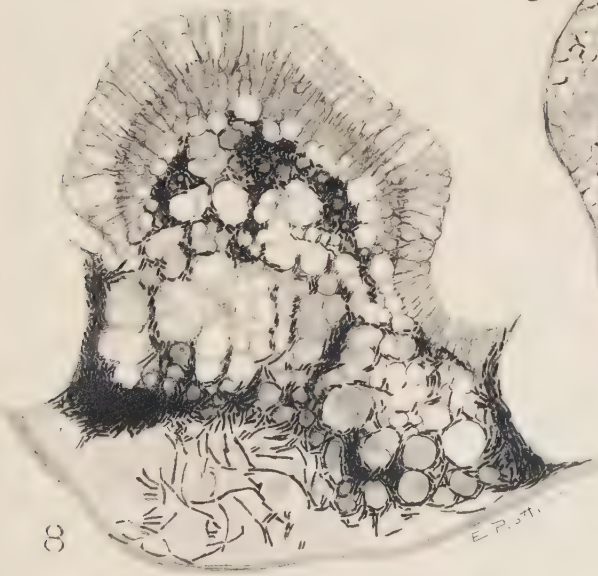
8
E. Rott.

10

THE DEVELOPMENT OF THE PARATHYROIDS IN THE DOG WITH EMPHASIS UPON THE ORIGIN OF ACCESSORY GLANDS

MELVIN CRAWFORD GODWIN

Department of Histology and Embryology, Cornell University, Ithaca, and Department of Anatomy and Histology, Medical School of West Virginia University, Morgantown

THREE PLATES (TWENTY-TWO FIGURES)

The purpose of this developmental study is to determine the mode of origin of the varying number of accessory parathyroid glands which have been demonstrated in a number of the common laboratory mammals and man. Erdheim ('06) reports parathyroid accessories in all of ten rats studied. Hoskins and Chandler ('25) report accessories in 10% of the rats examined. Shapiro and Jaffe ('23) find accessories to be common in the cat. Nicholas and Swingle ('25) report accessories in 36% of 107 cats. In the human, Millzner ('31) found accessories in 36% of forty-two cases and Brewer ('34) has shown that parathyroid tissue may be present in the human thymus. No systematic study primarily concerned with the presence of accessory parathyroid tissue seems to have been made in the dog. However, in the dog as well as in other forms there is ample evidence both anatomical and physiological to indicate their presence. Marine ('14) reports that there is enough accessory tissue present to maintain life in 5 to 6% of dogs, while Reed, Lackey and Payte ('28) find only one accessory parathyroid in thirty-three dogs. De Winiwarter ('26, '27, '32, '33, '35) finds a varying number of accessory parathyroids in the dog, cat, guinea pig, and other small animals.

The location of the accessory parathyroids as one might expect from their origin is quite variable. They are most frequently reported above and dorsal to the larynx, along the carotid artery, within and in the immediate vicinity of the thyroid gland, at a variable level in the anterior mediastinum, and within or associated with the thymus.

A number of questions arise in a consideration of the accessory parathyroid structures. Are any of them derived from supernumerary pouches? Are they fragments of the conventional parathyroids III and IV, and if so how do they reach the unusual locations in which they are sometimes found? Are any of them formed by a transformation of other pharyngeal derivatives—thymus, thyroid, and ultimobranchial body? The results of this embryological study indicate that accessory parathyroids arise from fragments of the conventional embryonic primordia of pouches III and IV.

MATERIALS AND METHODS

The embryological material used in this study largely consists of the series of dog embryos in the collection of the Department of Histology and Embryology of Cornell University, Ithaca. This material includes forty embryos of 4 to 28 mm. crown-rump length. In addition the head and neck of embryos of 32, 33, 38, 39, 40, 52, 54 mm. crown-rump length was examined. Also the thyroid region alone was examined in fetuses of 73, 75, 75, 75, 80, 85 mm. crown-rump length. The post-natal material consists of serial sections of fifty lobes of the thyroid gland taken from dogs of ages ranging from birth to adults.

DESCRIPTION OF EMBRYOS

Parathyroid III. The pharynx of the dog is quite typical in that it forms four pharyngeal pouches and an ultimobranchial body. The origin of parathyroid III is typical and was first observed at the 7.5-mm. stage. It is first evident as a slightly thickened deeper-staining area upon the dorsoanterior face of the third pouch and slightly medial to the

contact of the pouch with the cervical sinus. During the growth of the early parathyroid cords small cell clusters at the edge of the primordium at times sprout away from the main mass of the gland. Later in development they may become entirely separated and form small accessory structures. Their later position may be quite variable depending upon their original position and also upon how they are caught in the rather extensive growth shiftings which occur.

In the dog embryo of about 12 mm. crown-rump length the ductus pharyngeo-branchialis of complex III has just lost its connection to the pharyngeal wall. As complex III shifts ventrally, medially, and relatively caudally a portion of parathyroid III is at times caught upon the superior laryngeal nerve and in this manner retarded in its caudal shifting (fig. 1). It may remain permanently in this location or may in certain instances shift somewhat caudally. Figure 2 illustrates an accessory parathyroid III which has no doubt arisen in the manner described above. This parathyroid in the adult would apparently have been situated dorsal to the carotid artery and cephalic to the level of the thyroid gland.

The primordium of parathyroid III is closely associated (fig. 3) with that of thymus III until the embryo attains a crown-rump length of approximately 15 mm. Soon thereafter this relation is lost and it is during this separation that accessory parathyroids frequently arise. Small clusters of parathyroid cells break off from the principal gland and shift caudally in close association with the cephalic portions of the rapidly growing thymus (figs. 4, 5). This is perhaps the most common and easily understood process by which accessory parathyroids arise. Not infrequently the accessory material becomes loosened from its association with the thymus during its descent (fig. 6) and may be left stranded at varying levels (fig. 7). Such instances fully explain the origin of the accessories present in the anterior mediastinum of the adult.

The manner of origin of accessory parathyroid tissue which is embedded within or closely associated with the thymus—

exlusive of that which arises in the manner described above —is the most difficult to follow and to understand. As previously mentioned, small groups of parathyroid cells may become partially or wholly free from the principal gland early in development. During the descent of complex III as a whole these fragments shift caudally more rapidly than does the complex itself. As a result small accessory pieces may be seen at increasingly more caudal levels in older embryos (figs. 3, 8). Sometimes the accessories are very small indeed and may easily be overlooked. Figure 9 shows one close against the wall of the thymus consisting of only a few cells. The cells are identical with those of the principal gland; the small carmine-stained nuclei in both have a very characteristic brilliant red difficult to describe. The only other cells with which they might easily be confused are those of the numerous small ganglia of the autonomic nervous system. Small accessories were found associated with the thymus in older embryos at a surprisingly caudal level (fig. 10). Figure 11 shows a small accessory wedged in the angle between two portions of the rapidly expanding thymus III. Figure 12 shows another in an older embryo being engulfed between thymic folds. Parathyroid material in such a situation furnishes the material basis for understanding the presence of parathyroid tissue apparently within the thymus in the postnatal dog.

The principal parathyroid III, after it has become separated from the thymus, may usually be found on the lateral aspect of the thyroid near its cephalic pole (fig. 13). Its position is of course variable and although in the great majority of cases it is situated within the level of the cephalic third of the thyroid gland it may in certain instances be found more caudally placed—even at the extreme caudal pole. I have never seen a single case in either an embryo or postnatal dog in which any of the principal parathyroids were not closely associated with the thyroid gland. It may be added at this point that accessory parathyroids III were found far removed from the thyroid in each of the seven embryos of

33 to 54 mm. of which an examination of the head and neck only was made.

It might be of interest to call attention to the possibility of a portion of thymus III remaining attached to the principal parathyroid. This is very difficult to determine in the embryo and must be quite rare as only one such instance was noted in the post-natal material.

Parathyroid IV. A fourth pharyngeal pouch with a small branchial membrane is formed in the dog (Godwin, '37). This pouch is somewhat atypical and soon after its contact with the cervical sinus is broken it is apparently typically absorbed into the walls of the caudal pharyngeal complex (complex IV). In certain instances, however, soon after the branchial contact is broken a small pocket which projects ventrally and medially from the complex may be present. This pocket when present apparently represents a rudimentary and transitory (?) ventral diverticulum of the fourth pouch.

The first origin of parathyroid IV may be found in embryos of approximately 8.5 mm. At this stage complex IV is connected to the pharynx by a still open but quite narrow duct. On the dorso-lateral surface of the complex the parathyroid may be identified as a definitely thickened area of small darker-staining cells. It is to be regretted that no embryo was available which made it possible to establish the exact relations of the parathyroid IV to the transient (?) ventral diverticulum.

In embryos of about 12 mm. the club-shaped complex IV is usually connected to the pharynx by a solid strand of cells. Parathyroid IV may be easily recognized on the dorso-lateral surface of the complex about one-third of the way down its total length. For a time its primordium has the shape of a cone with the apex at the internal surface of the complex and the base forming a portion of the external surface (fig. 14). As the primordium enlarges it tends to spread open the walls of the conical hole which it occupies. Also its edges begin to spread along the surface of the complex, especially in a caudal

direction (fig. 15). In certain instances a broad thin sheet of parathyroid cells extends caudally for a surprisingly long distance (fig. 16). This peculiar expansion is of considerable importance in the understanding of conditions found in the post-natal thyroid gland.

During the period of fusion and inclusion of complex IV with the thyroid cell cords the enlarging parathyroid primordium undergoes a process of constriction and fragmentation which is very difficult to illustrate. Parathyroid fragments formed as a result of this process (fig. 17) may be and often are, as will be seen subsequently, caught in the growth shiftings and separated by a considerable distance in the adult.

During the period of fusion of complex IV with the thyroid, parathyroid IV usually looses its connection with the remainder of the complex, but this is not always true. In any case the connecting segment or stalk which unites the parathyroid to the complex is destined to form cystic ducts of varying position and character in older stages.

Description of the older embryonic material which was studied would serve no useful purpose, since the foundation for understanding conditions found in post-natal material has been laid in embryos of 28 mm.

DESCRIPTION OF POST-NATAL MATERIAL

No attempt has been made to follow accessory parathyroids III in the post-natal dog which are not associated with the thyroid gland. There can be no doubt that they are present since they were present in every embryo and have been reported by various investigators. However, it must be realized that it is practically impossible to examine an animal as large as a dog in sufficient detail to determine the presence or absence of all accessory parathyroid tissue. Since this is true the presence and location of accessory parathyroids, exclusive of those associated with the thyroid, as determined by the study of complete series of embryos has been considered to be sufficient for all practical purposes. In addition it might

be added that all the essential problems concerning the origin of accessory tissue which have not been considered in the embryonic material are met within the thyroid gland.

In the post-natal dog the parathyroid III is usually found upon the lateral surface at the level of the cephalic one-third of the thyroid lobes. Not infrequently it is located at the extreme cephalic pole of the thyroid amid the loose connective tissue which surrounds the branches of the superior thyroid artery. The parathyroid may, however, be located at any level even at times near the extreme caudal pole. It usually rests in a slight impression in the thyroid but does not tend to become deeply embedded. It might be of value to add that in every instance the main parathyroid was so closely associated with the thyroid that it would not escape removal with that structure unless precaution was taken to prevent it. Accessory parathyroids III are frequently present upon the surface of the thyroid and when found are usually large and quite close to the parent gland. The principal parathyroid almost constantly has a small duct or cyst within or associated with it. This is formed from the connecting segment and its cavity represents a part of the original pouch III. In one instance small salivary glands were found which opened into a cyst partially included within the parathyroid gland. In only one instance a small nodule of thymus was present with the main parathyroid III.

Parathyroid IV has received some consideration in connection with another subject (Godwin, '37). In that article the number of accessory parathyroids IV present in the post-natal material studied is represented in tabular form. From one to fourteen accessories were found in each lobe.

The main parathyroid IV in the dog is usually located on the medial surface in the caudal part of the cephalic half of the thyroid gland. As would be expected from its development it tends to be near the dorsal border and may at times be on the lateral surface near the dorsal border. Although the location is fairly constant it is subject to considerable variation. In a few cases it was found quite near the caudal

pole. The main parathyroid IV usually has a duct or cyst within or connected with it. This duct is the persistent stalk or connecting segment of complex IV and its cavity is a portion of the fourth pharyngeal pouch. It may be lined by a flat, cuboidal, columnar, pseudostratified columnar, or stratified squamous epithelium or as is frequently the case a combination of two or more of these various types. The space within the parathyroid may be quite small and simple or large and extensively ramified (figs. 18, 19). Sometimes a number of small disconnected cysts are present within the parenchyma of the parathyroid usually close by the large one but at times somewhat removed. In a few cases the duct extends a considerable distance into the thyroid parenchyma and has small accessory parathyroids scattered along its wall. Other accessories may be widely scattered in the thyroid parenchyma or on the surface of the thyroid. No instance was found either in the embryonic or post-natal material in which all the parathyroid IV material was not within or closely associated with the thyroid gland. In no case, however, was the principal parathyroid IV completely buried within the thyroid parenchyma.

The parathyroids IV of the left lobe of a 13-day-old dog will be described in detail to illustrate their location and distribution. A group of three parathyroids—two large and one rather small—is partially embedded in the thyroid near the point where a large artery enters the cephalo-dorsal edge of the lobe (fig. 20). Two of these glands are regarded as accessories. The third accessory is a very small one deep in the center of the upper third of the lobe at the side of the artery and connective tissue which enters the thyroid by the group of three parathyroids previously mentioned. The fourth accessory is slightly ventrad of the third and somewhat more caudad. It is not set off from the thyroid follicles which completely surround it by more connective tissue than surrounds a thyroid follicle (fig. 21). Passing still farther ventrad and caudad a small fifth accessory is found in the connective tissue that accompanies a large artery. The sixth

is a small gland situated in the center of the caudal half of the lobe. Like the fourth it is completely surrounded by thyroid follicles with no connective tissue septum or large vessels close by. The distribution of these parathyroids serves to illustrate the enormous growth shiftings and displacements which must occur.

In a few cases parathyroids were found along the duct leading into the thymus IV which is sometimes present, between lobules of the thymus, or apparently within the thymus tissue itself. Figure 22 illustrates an accessory parathyroid apparently embedded within the thymus IV tissue.

SUMMARY AND DISCUSSION

Most mammals have two pairs of parathyroids derived from the third and fourth pharyngeal pouches. However, the rat (Zuckerkandl, '03; Rogers, '27) has only parathyroid III, while Selle ('35) finds only a parathyroid IV in the Pacific pallid bat. De Winiwarter ('33) has recently reported that the guinea pig has a parathyroid III and V with occasionally a parathyroid IV. Careful study of suitable stages has shown only four pharyngeal pouches and an ultimobranchial body to be present in the dog. Careful study has also failed to reveal evidence indicating that parathyroid tissue ever arises from any part of complex III or IV other than the conventional parathyroid primordia of pouches III and IV.

It seems that the origin of the parathyroid is in some manner dependent upon the development of the pharyngeal pouch. In the rat, for example, parathyroid IV does not appear and one might suggest that it could not form since a pouch IV does not form. The determination of the pouches is itself poorly understood. In exogastrulated amphibian embryos, in which the entoderm lies upon the surface of the mesoderm (Holtfreter, '33), the entoderm pouches inward rather than outward as in the normal animal. Apparently this is due to the influence of the mesoderm upon the entoderm. It might well be that the number of pouches formed in different vertebrates is a function of the strength of the stimulus of the

mesoderm upon the entoderm, upon the length of the duration of its action, and upon the length of the period of reactability of the entoderm. The factors which determine the origin of the parathyroids remain obscure. However, as Groschuff ('00) suggested, the degree of parathyroid development seems to be correlated with that of the pharyngeal pouch. How significant this correlation is remains to be determined. However, in the dog the early small size is rapidly overcome and in the adult the parathyroid IV material is equal if not greater in amount than that derived from parathyroid III.

Quite early small fragments of parathyroid III become detached from the main anlage. The process by which such accessory parathyroid material is carried far caudad and becomes buried within or closely associated with the thymus deserves comment. It seems that the inertia of the large complex III prevents it from shifting caudad as rapidly as the mesenchyme surrounding it. The small fragments which early separate from the main anlage are passively carried caudally by the shifting of the mesenchyme over the complex. As a result they may come to lie at various levels alongside the expanding thymus. As the thymus grows the small accessories are caught between its expanding lobes (figs. 11, 12, 22) where they may be found in the adult. Parathyroids may appear to be actually within the thymus tissue, but critical examination indicates that they did not arise there but rather that they have been surrounded by the growth expansion of the thymus.

De Winiwarter ('26, '27, '33, '35) believes that parathyroid tissue can arise by a transformation of thymus, thyroid, and ultimobranchial material. No support for this conclusion has been found. The method by which the parathyroids become associated with the thymus during development has been given in detail. Merely because a parathyroid is found within the thymus does not mean that it is derived from it. The author has found thyroid tissue completely enclosed by thymus tissue, but this does not mean that it formed from the thymus or that the thymus formed from the thyroid. De

Winiwarter believes that the dual origin of the parathyroids is necessary to explain the wide distribution of parathyroid tissue within the thyroid as well as within thymus III and IV. The early origin of parathyroid IV was studied in particular. As soon as the primordium could be recognized its growth was apparently only from the original cells and not from a transformation of cells surrounding the anlage. It has been shown in the description of the embryonic material that the parathyroid IV undergoes a fragmentation process. This is due at least in part to the peculiar manner in which it grows down the side of complex IV (fig. 16). When the ultimobranchial portion of the complex begins to expand rapidly as it is being fused with and included within the thyroid its complicated folding and buckling serves to break up and widely displace portions of the parathyroid material. The growth of the thyroid cords also is responsible for a part of the parathyroid distribution. A small separation in the embryo may mean a considerable interval in the adult. Although accessory parathyroids within the thyroid are not uncommon in the embryo, they are sometimes quite frequent in postnatal thyroids (Godwin, '37). The apparent discrepancy here is clearly due to the difficulty in distinguishing very small parathyroid masses mixed with the thyroid cords in embryonic material.

Accessory parathyroids are frequently associated with ultimobranchial material whether included or unincluded within the thyroid, but here again there is nothing to indicate that they arise as a result of a transformation of ultimobranchial material. Untransformed ultimobranchial material may at times bear a certain resemblance to parathyroid tissue and it is probable that this similarity has resulted in some confusion.

It has been suggested that accessory parathyroid tissue might arise in response to a physiological stimulus or that other tissues serve as a physiological substitute for the parathyroids. Whether or not the parathyroids are essential for life may as yet be considered an open question. This question

is complicated in extirpation experiments by the extreme difficulty in knowing whether or not all parathyroid tissue has been removed. Every dog embryo studied possessed accessory parathyroid material which would not be removed by extirpation of the thyroid gland. This means that it is practically impossible to be sure of complete parathyroidectomy in the dog. Judging from the anatomical and physiological evidence available it seems possible that similar conditions exist in other common animals.

Careful study of the parathyroids of the dog failed to demonstrate the follicles filled with colloid described in many of the current texts. The early idea that the parathyroid glands are 'thyroid rests' still exerts an influence as is indicated by the following statement from Cajal ('33): "If the thyroids of a cat are extirpated, the parathyroids produce vesicular forms with a tendency to reconstruct the absent organ." A number of parathyroid glands of the dog were examined about 6 weeks after the removal of the thyroid lobes and no colloid-filled vesicles were present. It is possible that in some cases vesicular portions of the ultimobranchial body have been mistaken for parathyroids. It is also possible and quite probable that the small vesicles not infrequently present within the parathyroid, which arise from the stalk or connecting segment of complex III or IV, have been interpreted as 'follicles.' Such vesicles occur in a variety of forms, some of which may be very misleading. However, when the epithelial origin of the parathyroids is kept in mind the appearance of vesicles is easily understandable.

CONCLUSIONS

1. There is no evidence that parathyroid tissue in the dog ever arises from any source other than the primordium of pouches III and IV.

2. The principal parathyroids III and IV were in every case associated so closely with the thyroid that they would be removed with it unless precautions were taken to prevent it.

3. Accessory parathyroid III material unassociated with the thyroid gland was present in every embryo.

4. Accessory parathyroid III material may be present near the superior laryngeal nerve, along the carotid artery both cephalad and caudad to the thyroid gland, in the anterior mediastinum, and within or associated with the thymus III.

5. Early fragmentation of parathyroid IV with subsequent growth shiftings is entirely adequate to account for the number and position of the accessory parathyroids IV found within or associated with the thyroid gland or thymus IV of the dog.

6. From one to fourteen accessory parathyroids IV were found in fifty lateral thyroid lobes studied.

LITERATURE CITED

Brewer, L. A., III 1934 The occurrence of parathyroid tissue within the thymus: Report of four cases. Endocrinology, vol. 18, pp. 397–408.

Cajal, Ramón S. 1933 Histology. Williams and Wilkins Co., Baltimore.

Erdheim, J. 1906 Zur Anatomie der Kiemenderivative bei Ratte, Kaninchen und Igel. Anat. Anz., Bd. 29, S. 609–623.

Godwin, M. C. 1937 Complex IV in the dog with special emphasis on the relation of the ultimobranchial body to interfollicular cells in the postnatal thyroid gland. Am. J. Anat., vol. 60, pp. 299–339.

Groschuff, K. 1900 Über das Vorkommen eines Thymussegmentes der vierten Kiementasche beim Menschen. Anat. Anz., Bd. 17, S. 161–170.

Holtfreter, J. 1933 Die total Exogastrulation, eine Selbstablösung des Ektoderms vom Entomesoderm. Arch. Entwmech., Bd. 129, S. 670–793.

Hoskins, M. M. and S. B. Chandler 1925 Accessory parathyroids in the rat. Anat. Rec., vol. 30, pp. 95–98.

Marine, D. 1914 Observations on tetany in dogs. J. Exp. Med., vol. 19, p. 89.

Millzner, R. J. 1931 Normal variations in the position of the human parathyroid glands. Anat. Rec., vol. 48, pp. 399–405.

Nicholas, J. S. and W. W. Swingle 1925 An experimental and morphological study of the parathyroid glands of the cat. Am. J. Anat., vol. 34, p. 469.

Reed, C. I., R. W. Lackey and J. I. Payte 1928 Observations on parathyroidectomized dogs, with particular attention to the regional incidence of tetany, and to the blood mineral changes in this condition. Am. J. Physiol., vol. 84, pp. 176–188.

Rogers, W. H. 1927 The fate of the ultimobranchial body in the white rat (Mus norvegicus albinus). Am. J. Anat., vol. 38, pp. 349–375.

Selle, R. M. L. 1935 The embryology of the thyroid, parathyroid, and thymus of the Pacific pallid bat (Antrozous pacificus Merriam). Am. J. Anat., vol. 56, pp. 161–191.

Shapiro, S. and H. Jaffe 1923 On the occurrence of accessory parathyroids and their relation to survival of animals after parathyroidectomy. Endocrinology, vol. 7, p. 720.

De Winiwarter, H. 1926 Observations sur l'appareil parathyroïdien de quelques mammifères. L'Assoc. des Anat., T. 21, pp. 576–585.

——— 1927 Thymus, thyroïd, parathyroïdes, corps branchial ultime et leurs relations réciproques. Extrait de Liége Medical, no. 6, pp. 5–23.

——— 1932 Ilots thymiques des thyroïdes et parathyroïdes. Compt. Rend. Ass. Anat., Liége, pp. 1–8.

——— 1933 Recherches sur l'évolution des dérivés branchiaux et l'histogenèse du thymus (Cobaye). Arch. de Biol., T. 44, pp. 741–808.

——— 1935 Recherches sur les dérivés branchiaux (Chat). I. Evolution des dérivés branchiaux. II. Histogenèse du thymus. III. Anomalies. Arch. de Biol., T. 44, pp. 369–427.

Zuckerkandl, E. 1903 Die Entwicklung der Schilddrüse und der Thymus bei der Ratte. Anat. Hefte, Bd. 21, S. 1–28.

PLATES

PLATE 1

EXPLANATION OF FIGURES

1 Frontal section of a 12 mm. embryo showing a small group of parathyroid III cells against the superior laryngeal nerve. The cervical vesicle is present at the right edge. The thyroid is stretched along the aortic sac and common carotid arteries. A small portion of the pharyngeal cavity is present in the upper center. × 68.

2 Parasagittal section of a 17-mm. embryo showing a large accessory parathyroid III caudad to the superior laryngeal nerve and dorsal to the common carotid artery. The principal parathyroid III is in the lower center. × 60.

3 Parasagittal section of a 13-mm. embryo showing an accessory parathyroid III at the side of the cephalic portion of the thymus. The principal parathyroid III is at the upper center. The cavity of the cervical vesicle which is here fused to the thymus is evident in the center of the cell mass at the left of the cephalic end of the thymus. × 192½.

4 Frontal section of a 12-mm. embryo showing a small accessory parathyroid III on the medial surface of the most cephalic part of the thymus III. The principal parathyroid III is at the center of the right edge. The thyroid is stretched along the common carotid artery. × 68.

5 Transverse section of a 17-mm. embryo showing an accessory parathyroid III dorsal to the cephalic portion of the thymus III. The common carotid artery and vagus nerve are at the upper left corner. The pericardial cavity is at the lower right. × 192½.

6 A parasagittal section of a 17-mm. embryo showing an accessory parathyroid III at the left of the cephalic pole of the thymus III. The carotid artery is at the upper center. The pericardial cavity is at the right. × 68.

7 Parasagittal section of an embryo of 40-mm. showing a small accessory parathyroid III which lies low in the neck against the wall of the common carotid artery. × 480.

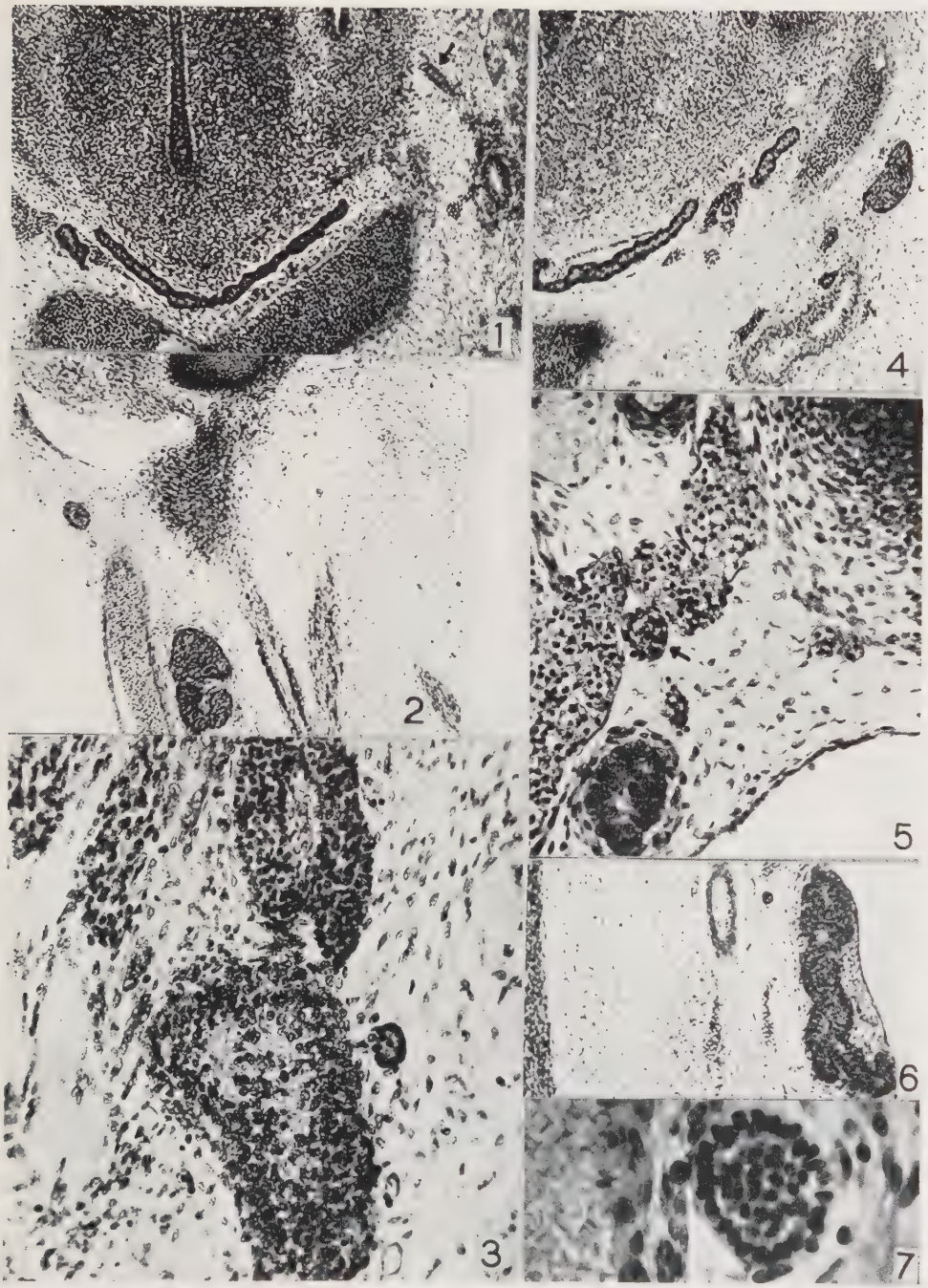
1
2
3
4
5
6
7

PLATE 2

EXPLANATION OF FIGURES

8 Frontal section of a 12-mm. embryo showing a small accessory parathyroid III near the medial surface of the thymus. The principal parathyroid III shows at the upper left; the thyroid is at the right edge, and the common carotid artery lies between them. × 137½.

9 Transverse section of a 12-mm. embryo showing a very small accessory parathyroid III at the surface of the thymus III. × 272.

10 A parasagittal section of an embryo of 17 mm. showing a small accessory parathyroid III near the dorsal edge of the thymus. The pericardial cavity is at the right. × 137½.

11 A frontal section of a 12-mm. embryo showing a very small accessory parathyroid III in the angle between the folds of thymus III. The thyroid shows at the upper right. × 137½.

12 A sagittal section of a 28-mm. embryo showing an accessory parathyroid III between folds of the thymus III. × 137½.

13 A transverse section of a 17-mm. embryo showing the principal parathyroid III at the lateral surface of the cephalic portion of the lateral thyroid cords. On the medial surface of the cords the parathyroid IV forms the medial portion of the duct-like cephalic part of complex IV. × 50.

14 Frontal section of a 12-mm. embryo showing the pyramid-shaped parathyroid IV in the lateral wall of the cephalic portion of complex IV. The esophagus shows at the upper left. × 137½.

15 Parasagittal section of a 13-mm. embryo showing the parathyroid IV expanding along the surface of the complex IV. The thyroid is present above the common carotid artery. × 137½.

16 Transverse section of a 12-mm. embryo showing a thin sheet of parathyroid IV cells upon the surface of the ultimobranchial portion of complex IV. The thyroid is present at the lower edge. × 137½.

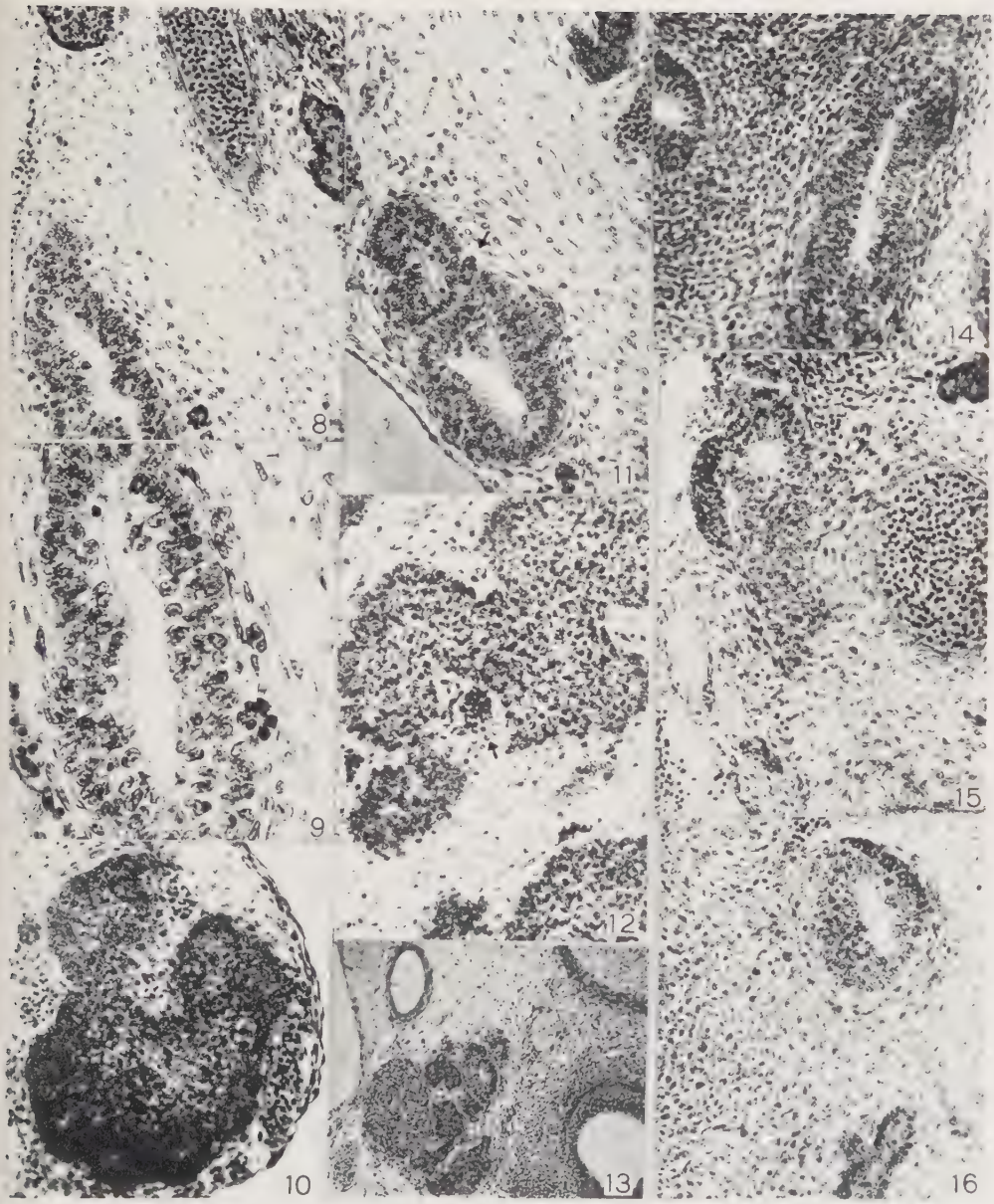
8
9
10
11
12
13
14
15
16

PLATE 3

EXPLANATION OF FIGURES

17 A parasagittal section of a 28 mm. embryo showing the principal parathyroid IV and two accessories associated with the thyroid cords. × 192½.

18 A section of a parathyroid of an 80-day-old dog showing three small cysts at the edge of parathyroid IV. × 100.

19 A section of a parathyroid of an adult dog showing a number of isolated and communicating cysts in the parathyroid IV. × 100.

20 A section of the thyroid gland of a 13-day-old dog showing the principal parathyroid IV and two accessories. The small accessory at the right edge of the large gland is on the wall of a cyst which appears to be a thyroid follicle. The body at the lower left is not a parathyroid; it is unincluded ultimobranchial material. × 40.

21 A section of the thyroid of a 13-day-old dog showing a small parathyroid deeply buried in the thyroid parenchyma. × 192½.

22 A section of thymus IV of a 62-day-old dog showing an accessory parathyroid IV buried within thymus IV tissue. × 100.

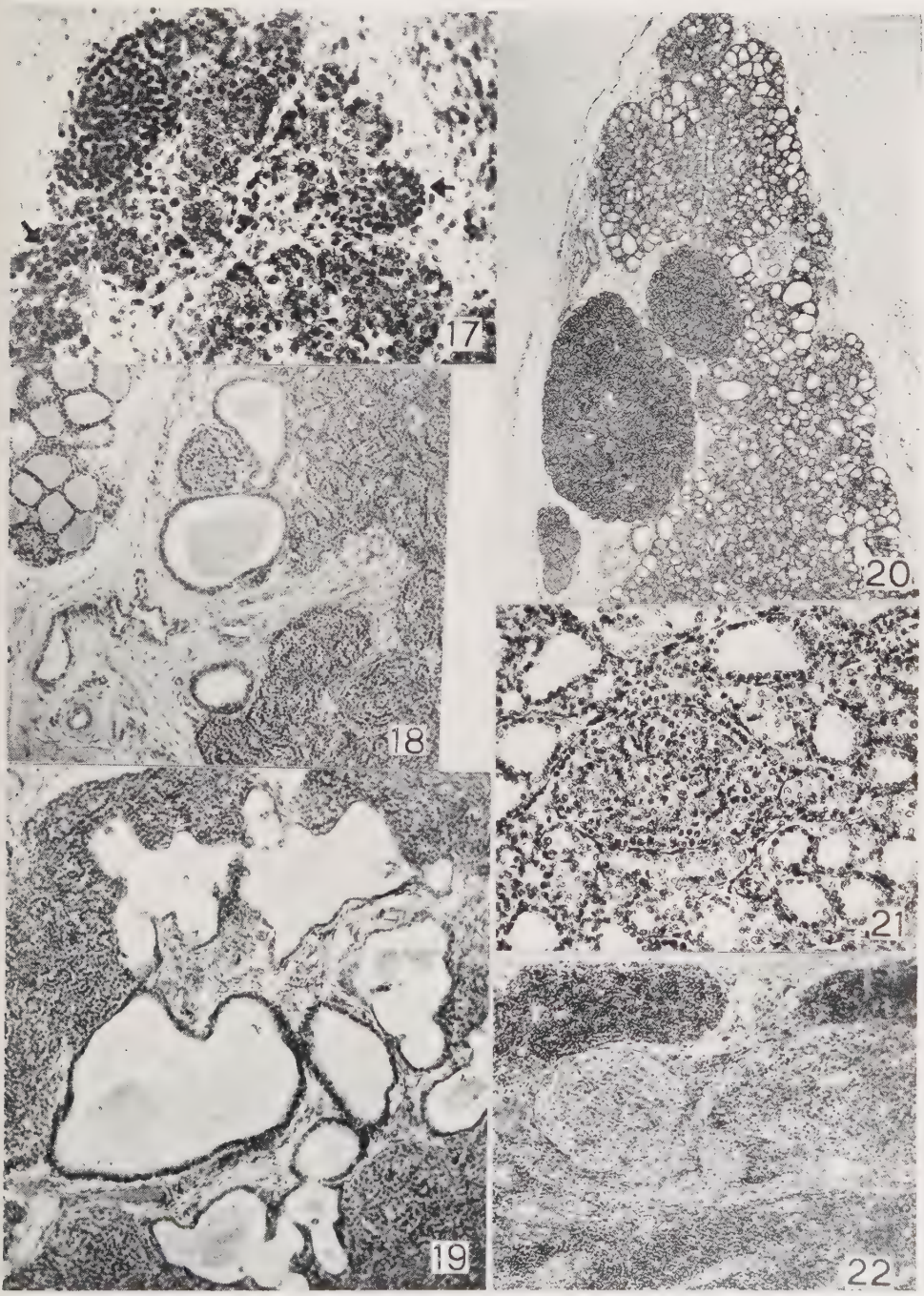
17
18
19
20
21
22

MORPHOLOGIC COMPARISON OF THE PARIETAL AND THE VISCERAL PERITONEAL EPITHELIUM IN FETUS AND ADULT [1, 2, 3]

REINO H. PUUMALA

Department of Anatomy, College of Medicine, University of Illinois, Chicago

FIVE FIGURES

INTRODUCTION

The bibliography on the anatomy of the peritoneum has been presented by Hertzler in his two-volume work published in 1923. Since then, little has been written on the morphology of the peritoneal epithelium.

The present paper represents a small part of an extensive program of investigation which is being conducted under the direction of Prof. Otto F. Kampmeier by different members of his department on the anatomical pathways of drainage, including not only the venous and lymphatic systems, but also the serous cavities. The writer began with the aim of studying comparatively the walls of different body cavities, such as joint, meningeal and coelomic, but soon restricted his effort to observations on the peritoneum when he discovered decided differences between its visceral and parietal layers in the size and form of their cells—differences which become

[1] Submitted for publication, September, 1936.

[2] Submitted in partial fulfillment of the requirements for the M.S. degree in anatomy, in the Graduate School of the University of Illinois, 1936.

[3] After this paper had been sent to press, Prof. William Snow Miller's book on 'The Lung' appeared. His figures 103 to 106, illustrating the mesothelia of the parietal and visceral pleurae, fixed in the stretched and the in situ conditions, confirm the opinion expressed herein regarding the effect of tension on the form of the cells.

marked during the progressive stages of fetal growth and persist in the adult.

The author is deeply indebted to Doctor Kampmeier for his many helpful suggestions and encouragement in the course of the work.

MATERIAL AND METHODS

The chief material used were pig embryos and fetuses, ranging from 14 mm. to 132 mm. in length, with ages from 20 to 65 days computed on the basis of tables by Warwick, Bruce and Lester ('28). The adult human material, corroborating the findings in the pig, was obtained from fresh autopsy examinations on cases with no intraperitoneal pathology.

The peritoneal, pleural, and pericardial sacs of the embryos, secured from freshly killed sows, were treated with a 0.75% silver nitrate solution. Injection was done gently through a 27-gauge needle, its position being made certain by aspiration. Then the needle was passed through to puncture the opposite side, and was withdrawn sufficiently to continue the injection. The introduction of the silver solution was continued until the escaping fluid no longer contained flocculated material. After the injection, the specimens were fixed in 10% formalin until ready for preparation.

After fixation, the body cavities were opened and small areas removed to obtain both parietal and visceral peritoneum: 1) from the anterior body wall so as to include the parietal peritoneum in the right lower quadrant of the fetus, and 2) from the mesentery, the gut surface, liver and diaphragm. Sections were also obtained from the pleural and pericardial surfaces. These small pieces of tissue were then exposed to the action of ultraviolet light until the peritoneal surface became a dark golden brown from the reduction of the silver. In comparing the employment of artificial ultraviolet light and sunlight, the latter was found to be more effective.

The reduced tissues were carefully placed on a small block of ice on the stage of a freezing microtome. The surface to

be studied was placed downward, that is, away from the knife. Then the surplus tissue was shaved off until a thin translucent film remained on the ice. This was picked up by gently pressing a warm glass slide on the ice block. With a fine canula and absorbent paper the excess water was removed, and the preparation was ready for mounting. The tissues were mounted in glycerin and ringed in with balsam.

The adult tissues were not fixed in formalin, but the preparations were made by the same freezing technique. The tissues were dropped into silver solution, 1%, and after 3 hours they were removed for reduction by ultraviolet light. The specimens were cut and the films mounted in the same manner. Pieces of the original blocks were saved for cross sectioning.

The blocks of reduced silvered tissue were placed into 10% gelatin, and this allowed to congeal. The embedded blocks were then hardened in 10% formalin for 5 or 6 hours. Thin transverse sections were cut by the freezing method and mounted in glycerin.

Preparations were obtained from pig embryos and fetuses of the following sizes: 14, 19, 20, 25, 29, 40, 43, 50, 55, 60, 65, 75, 82, 90, 100, 105, 120 and 132 mm.; from a full-grown pig; and from several human adults. To keep down the extra cost of publication, photomicrographs of only five of these are illustrated comparatively.

OBSERVATIONS

The general conception regarding the peritoneal cells, or the cells forming the surface lining of the peritoneum, is that they are flat, polygonal cells of more or less uniform shape and size, arranged in a sheet of mosaic pattern. The term peritoneal epithelium is a better one than the designation mesothelium, traditionally used. Toldt, according to Hertzler, was the first to describe the transformation of the mesodermal cells from a cuboidal to the flattened shape of the peritoneal epithelium. Hertzler observed that this process of flattening was well advanced in a human fetus of 6 weeks. Neither of these writers makes any mention of surface views

of such early stages. It is held that peritoneal cells vary greatly in size and shape in different areas, and seem to change shape in the direction of visceral distentions and contractions.

In studying the peritoneum of embryos and fetuses, it was noted that in the younger stages the cells covering the visceral and parietal surfaces were similar, and as the age of the fetus increased there was a progressive change in corresponding areas. These areas are compared in the following series of photomicrographs (all taken at the same magnification: $\times$ 750) of which the upper of each pair represents the visceral, and the lower the parietal surface. With the exception of figure 1, A, and figure 4, A, which show the peritoneal cells from the surfaces of the liver and mesentery, respectively, the visceral peritoneum illustrated represents the gut surface. The parietal peritoneum, displayed in the lower (B) of each pair of photographs, represents the abdominal lining of the lower right quadrant.

In comparing the surface views of visceral and parietal peritoneum, as illustrated in figure 1, A and B, taken from a 14-mm. pig embryo (approximately 20 days old), it is observed that the epithelial cells of the parietal layer already are smaller than those of the visceral. The cells of the visceral layer are more regular in outline, with straighter intercellular lines. Though these lines are relatively fine in both preparations—the black blotches in A, figure 1, representing silver deposits along the intercellular boundaries—they tend to be more wavy in the parietal surface. In the younger stages, as this figure shows, the position of the nucleus is not distinct in either surface. In the 43-mm. stage (approximately 37 days) figure 2, A and B, the visceral surface (A) appears much like that of the preceding stage. The parietal cells, on the contrary, display bolder outlines, giving the impression of double lines here and there. Moreover, the parietal cells are beginning to show an elongation in one direction. On the parietal surface, too, the nuclear position is indicated in some of the cells. This is an additional point of difference between the silver preparations of visceral and parietal peritoneum, the former seldom revealing the location of the nucleus.

Comparison of the visceral and parietal peritoneum surfaces in a 65-mm. pig fetus (approximately 45 days) shows the differences to have become more pronounced. The cell boundaries

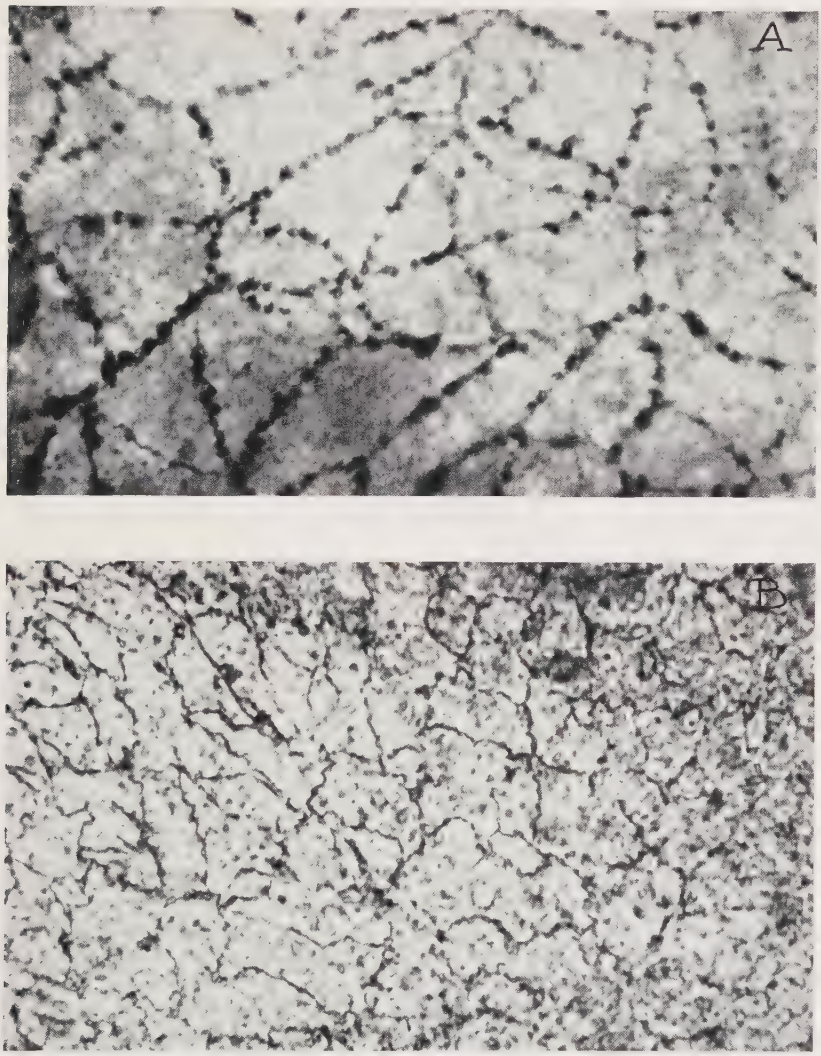

Fig. 1 Photomicrographs of surface views of visceral, A, and parietal, B, peritoneal epithelium from a 14-mm. pig fetus (approximately 20 days); silver nitrate preparation. × 750.

of the visceral surface are more sinuous, and the cells of the parietal surface are smaller and more elongate.

At this point it is convenient to call attention to the interesting fact, evident in all of the preparations, that there are

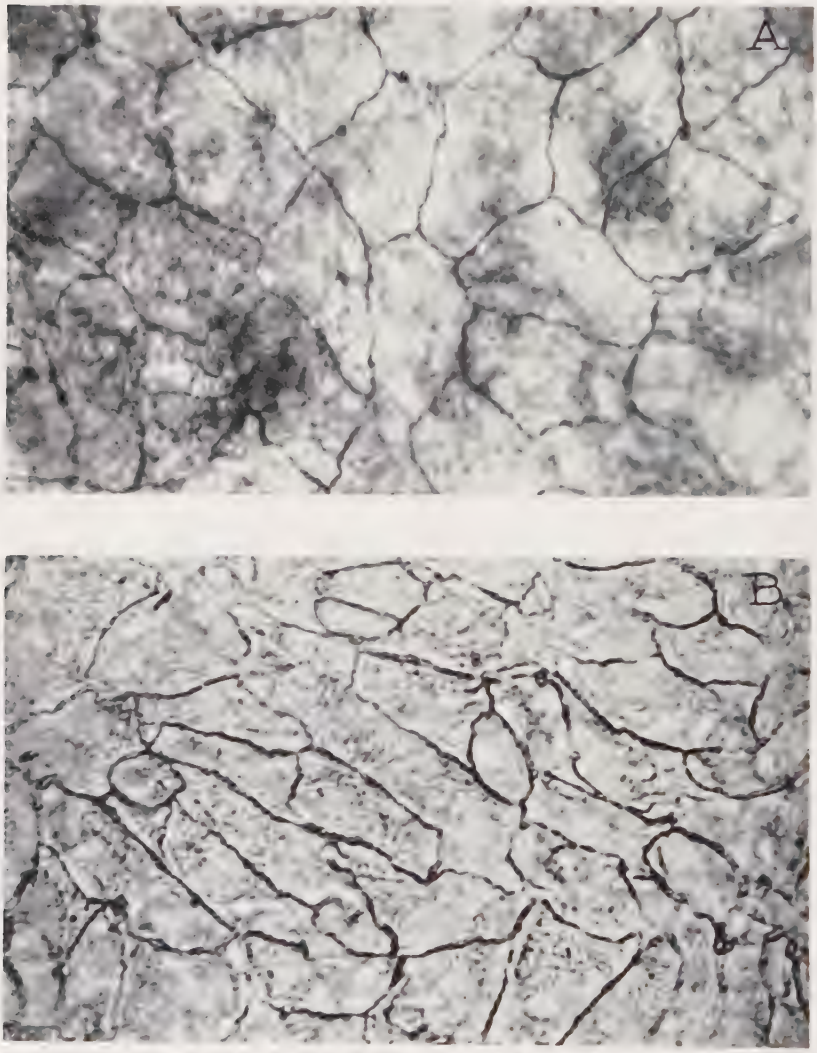

Fig. 2 Photomicrographs of surface views of visceral, A, and parietal, B, peritoneal epithelium from a 43-mm. pig fetus (approximately 37 days); silver nitrate preparation. × 750.

roughly twice as many cells per unit area of parietal surface than of visceral surface. This can be determined by counting the number of cells in the field of the photomicrograph. On the basis of these counts an approximate ratio is obtained for each stage, which is recorded in the accompanying table.

TABLE 1

Numerical differences of visceral and parietal peritoneal cells per unit area (6.5 × 10.7 cm., as defined in accompanying photomicrographs)

MATERIAL	LENGTH	AGE	VISCERAL CELL COUNT	PARIETAL CELL COUNT	V:P RATIO	SEE FIGURE
	mm.					
Pig fetus	14	20 days	34	75	1 to 2.2	1
Pig fetus	19	25 days	24	46	1 to 1.9	
Pig fetus	43	37 days	29	45	1 to 1.5	2
Pig fetus	65	45 days	37	71	1 to 1.9	
Pig fetus	75	47 days	27	58	1 to 2.0	3
Pig fetus	82	50 days	22	54	1 to 2.4	
Pig fetus	100	54 days	25	50	1 to 2.0	
Pig fetus	105	55 days	27	45	1 to 1.6	
Adult pig	...	.....	34	73	1 to 1.7	4
Human male	...	34 years	43	71	1 to 1.6	5

In the 75-mm. stage (approximately 47 days) the intercellular boundaries of both visceral and parietal peritoneal cells are distinctly double-lined as revealed in figure 3, A and B. This character is repeated in all of the subsequent stages. The morphological differences between the cells of the two areas are the same as in the previous stages.

In the next stage, an 82-mm. pig fetus (approximately 50 days), the visceral cells show no essential change, but the parietal cells are characterized in addition to their elongate axis by broad hazy outlines in which the parallel lines are still evident. This type of change has progressed further in the next stage examined, a 105-mm. pig fetus (approximately 55 days), in which the parietal cell outlines are more blurred.

The characteristic difference between visceral and parietal peritoneum described for the preceding stages of the pig fetus persist in all of its later stages.

Turning now to the character of the visceral and parietal peritoneal cells of the adult pig, as shown in surface view, their differences are depicted in figure 4, A and B. Here, the blurred double-lined margins of the parietal cells resemble

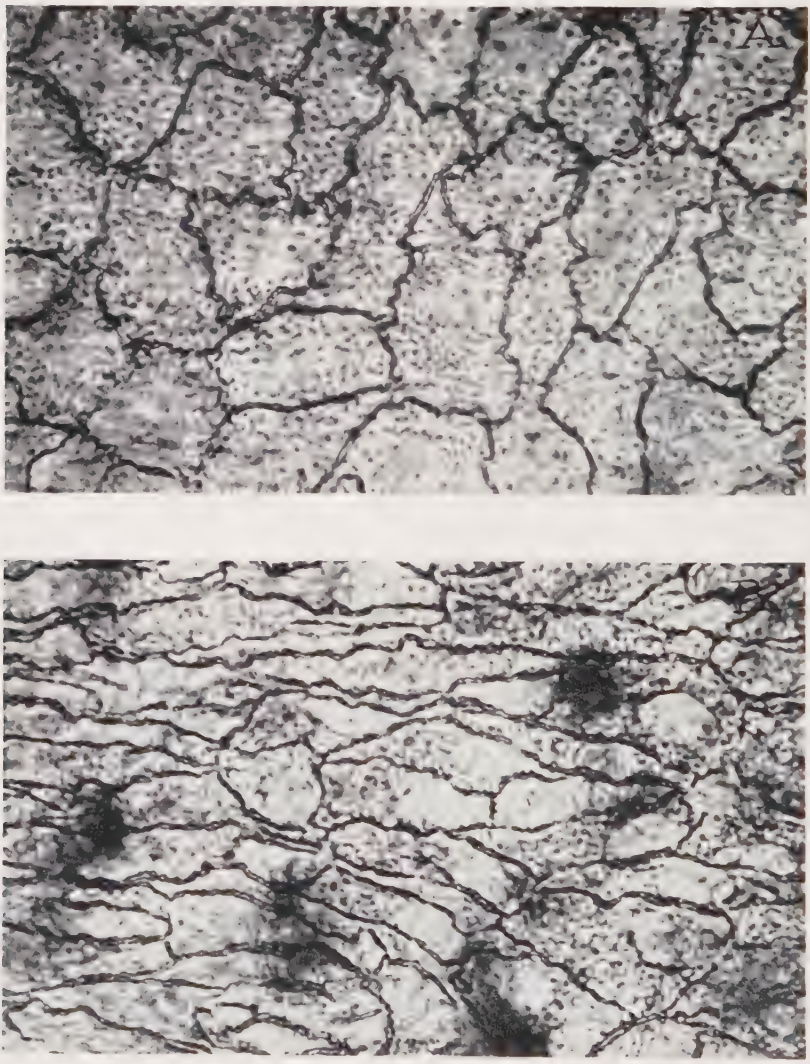

Fig. 3 Photomicrographs of surface views of visceral, A, and parietal, B, peritoneal epithelium from a 75-mm. pig fetus (approximately 47 days); silver nitrate preparation. × 750.

those of the later fetal stages of the pig. But the form of the cell is different, being less elongate and more polygonal. In the preparation the contours of the visceral cells appear a little more delicate and more sharply defined, though possessing double lines throughout.

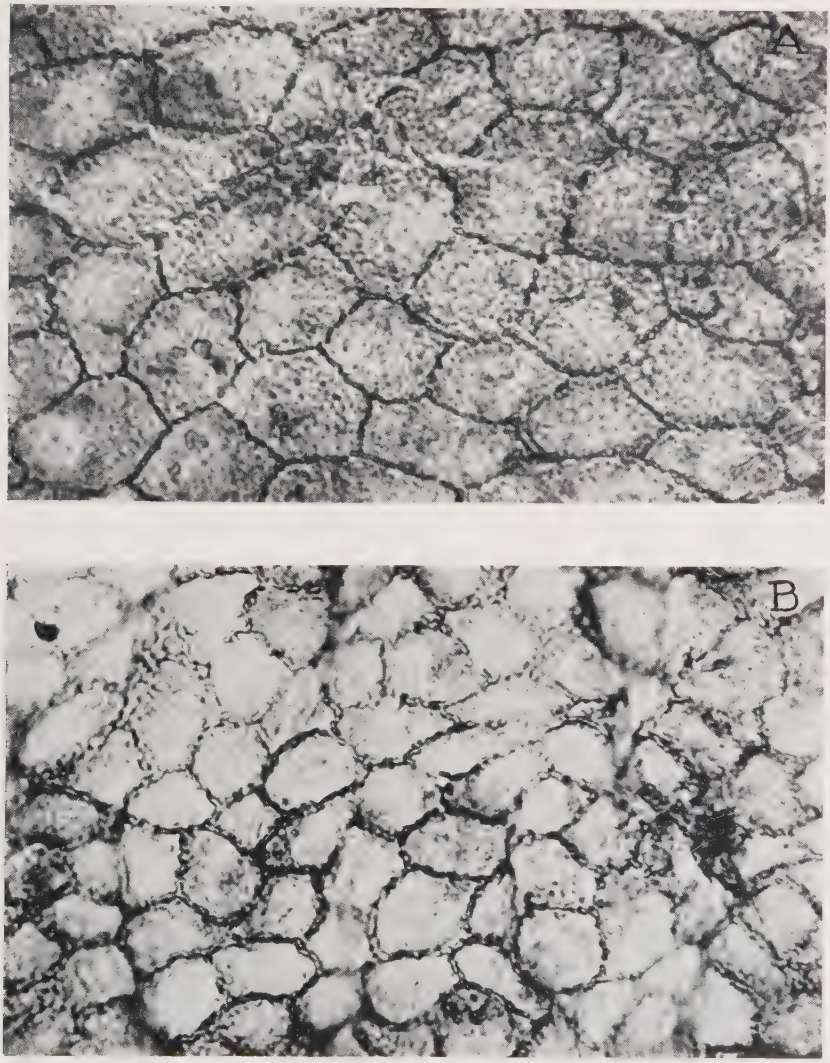

Fig. 4 Photomicrographs of surface views of visceral, A, and parietal, B, peritoneal epithelium from a full grown pig; silver nitrate preparation. × 750.

In the human adult, the differences between the visceral and the parietal peritoneal epithelia are as clearly expressed (fig. 5, A and B) as in the pig. But the visceral cells (A) show more serrations or dove tailing.

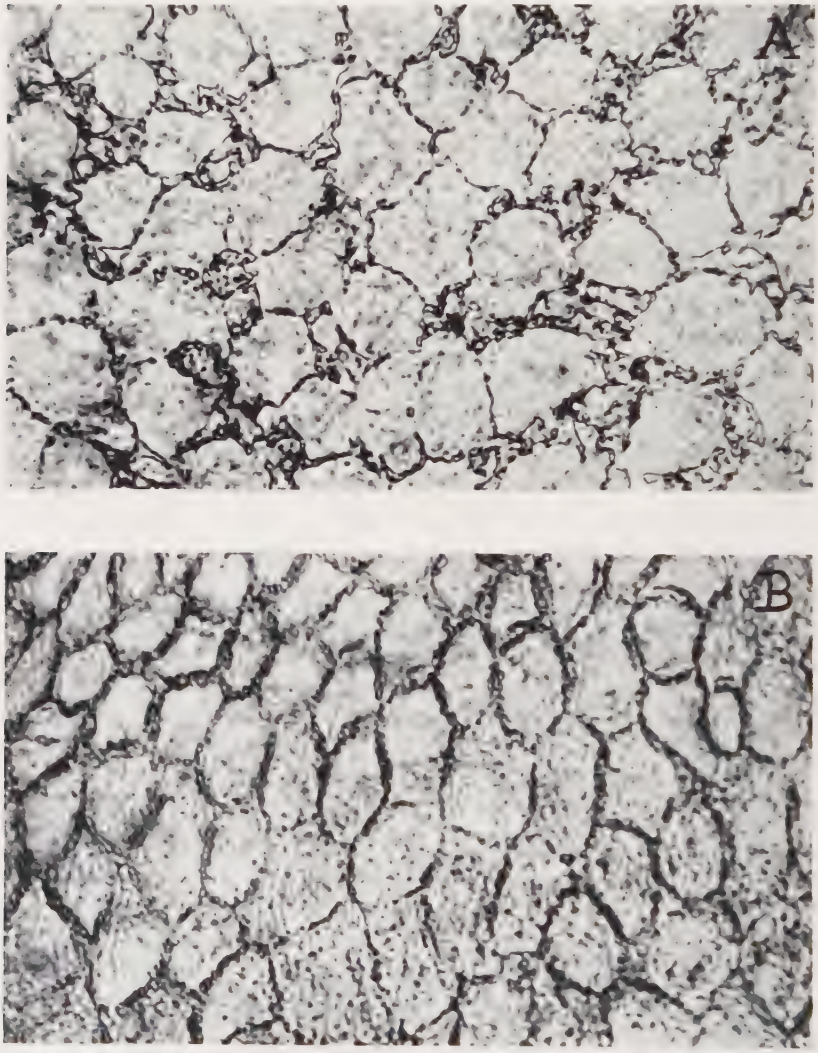

Fig. 5 Photomicrographs of surface views of visceral, A, and parietal, B, peritoneal epithelium from a human male (34 years); silver nitrate preparation. × 750.

Transverse sections of the visceral and parietal peritonea of the human adult demonstrate clearly the difference between the two: the thicker and more globular form of the parietal cells and their tendency to 'shingling' or overlapping of edges.

DISCUSSION

Nothing further need be said regarding the persistent differences in cell form and size between the visceral and the parietal epithelium, since they are so distinctly portrayed in the photographs. Their consequent differences, too, in the number of cells per unit area are expressed sufficiently clearly in figure and table.

There remains the endeavor to explain the distinctions between the visceral and parietal epithelium in the appearance of their cell outlines. Artifacts obtained with silver nitrate staining have been demonstrated by Hertzler. But he also quotes Subotin's statement (1882) that there is a shingling effect of the endothelial cells of blood vessels. The writer believes it is the partial overlapping of adjacent cells which accounts in part for the relative blurring of cell boundaries in surface views of parietal epithelium. This interpretation is suggested in transverse sections in which the parietal cells are seen to be more oval or globular with corresponding depressions at the points of contact with adjacent cells, while the visceral epithelium appears to be of uniform thickness throughout and its cells spindle shaped.

The reactions of the stain at the cell boundaries has not been satisfactorily explained. According to Hertzler it is the formation of reduced silver chloride in the intercellular cement. The writer believes that the appearance of these lines is due to fine granular silver deposited on the surface of the cell, so that when the cell edge is viewed surface-wise the superimposition of these granules in the intercellular depression gives the eye the effect of lines. The less overlapping there is at the margins, the more sharply defined will be the cell outline. When the two cell edges do not come in absolute opposition, the space between being filled with albuminous material will stain differently, and give this intercellular

space a demarcation by parallel lines, when viewed from the surface.

The question arises why should the parietal peritoneal cells be more globular? When the surface of such cells are fixed by silver nitrate and the subepithelial tissues contract, the cells are crowded and pulled together more with the tendency of their edges to slide over each other. This occurs in more pronounced fashion in the parietal peritoneum where the subepithelial connective tissue possesses more elastic fibers than are found in the visceral peritoneum.

Another question arises. Why are the parietal cells, as shown in the figures of the preparations from the fetal pig, elongate in a definite direction? It is impossible to give a positive answer at this time, but a possible explanation may be suggested in another question. Is their elongation an effect of the direction of tension of the subepithelial tissue during growth, or is it an artifact resulting from the fixation of these tissues?

SUMMARY

The parietal and visceral peritoneal surfaces were studied in pig fetuses of 14-mm. to 130-mm. stages, as well as in the full-grown pig and in the human adult. A difference in size between parietal and visceral peritoneal cells appears early, the parietal being persistently smaller in all fetal stages and in the adult. During the fetal period the parietal cells tend to elongate in a definite direction. Cross sections demonstrate the more globular appearance of the parietal cells, and the tendency of the edges to overlap. Possibly it is this feature which causes the contours of the parietal cells to appear somewhat blurred as compared with the sharp outlines of the visceral cells.

LITERATURE CITED

Hertzler, A. E. 1919 The Peritoneum, vol. I. C. V. Mosby Co., St. Louis, Mo.

Warwick, B. L. 1928 Prenatal growth of swine. J. Morph. and Physiol., vol. 46, pp. 59–84.

Robinson, Byron 1897 The Peritoneum, part 1. W. T. Keener Co., Chicago.

Miller, W. S. 1937 The Lung. Chas. C. Thomas, Springfield, Illinois, and Baltimore, Maryland.

HYPERTROPHY OF INTERSTITIAL CELLS IN THE TESTES OF MICE RECEIVING ESTROGENIC HORMONES [1]

W. U. GARDNER

Department of Anatomy, Yale University School of Medicine

ONE TEXT FIGURE AND ONE PLATE (FOUR FIGURES)

The estrogenic hormones have been shown to have an inhibiting effect upon the development of the testes and the ovaries. These observations have been attributed to a reciprocal effect of the sex hormones upon the pituitary (Moore and Price, '32). Lane ('34) observed that the pituitaries of rats which had received estrogenic hormone produced upon implantation a luteinizing effect upon the ovaries of recipients. Wolfe ('35) also found that the administration of estrogenic hormone in rats induced the persistence of large corpora lutea. Under the influence of estrogenic hormone the pituitary presumably produces an effective amount of luteinizing hormone (L.H.) which has been recently shown to stimulate the hypertrophy of the interstitial cells in the testes of rats (Greep, Fevold and Hisaw, '36). Recent experiments have indicated the existence of a distinct interstitial cell stimulating fraction in the anterior pituitary (Evans et al., '36).

Burrows ('35, '36) described changes in the testes of mice receiving large amounts of estrogenic hormones. The spermatogenic function was impaired, and after long periods of treatment completely repressed. In some animals the atrophic tubules were widely separated by an increased number of large interstitial cells.

[1] This investigation has been supported in part by a grant from the Committee for Research in Problems of Sex of the National Research Council administered by Prof. Edgar Allen.

Further observations on the effect of large amounts of estrogenic hormones on the stimulation of interstitial cell hypertrophy are reported in the present paper. The mice used in the present experiment were from five different strains (A, C_3H, CBA, N and F).[2] Various estrogenic chemicals have been used; namely, theelin, theelol,[3] keto-estrin benzoate, hydroxy-estrin-benzoate, equilin-benzoate and equilin.[4] As the changes to be described in the testes of the mice of the A strain have occurred only in those animals receiving at least 500 i.u. of hydroxy-estrin benzoate or 0.1 mg. equilin benzoate weekly over extended periods, those alone will be described in detail. All hormones were in solution in oil. The doses of theelin, equilin and theelol administered were probably too small to induce the changes to be described in the interstitial cells of the testes. One hundred or 250 i.u. of hydroxy-estrin benzoate weekly has proven inadequate.

All injections were made subcutaneously. The testes were fixed in Bouin's fluid, and either sectioned serially or two or more serial slides from the central portions of each testis were retained. One slide of each testis was stained with hematoxylin and eosin and one with Masson's technique.

Fifteen male mice from the A strain were given weekly injections of 500 i.u. of hydroxy-estrin benzoate for periods of 76 to 250 days. The injections were started when the animals were from 7 to 32 days of age. The testes of these mice (with the exception of the one animal treated for less than 100 days) showed variable amounts of interstitial cell hypertrophy and tubular damage. At autopsy these testes were yellowish-brown in color. In those animals in which the injections were started at 7 days of age the testes varied from about one-half normal to approximately normal size (fig. 1). The size was not greatly altered in the animals in which injections were started following weaning.

[2] The mice were generously supplied by Dr. L. C. Strong. The letters used to designate various strains are those in use in his colony.

[3] The theelin and theelol were generously supplied by Parke, Davis and Co., through the courtesy of Dr. Oliver Kamm.

[4] The equilin and equilin-benzoate were generously supplied by Prof. A. Girard at the request of Dr. G. M. Smith.

Large, vacuolated interstitial cells were present in great numbers, in some areas completely replacing the tubules. These cells were approximately twice the size of normal interstitial cells (figs. 4 and 5). Though there had been an apparent cell multiplication, the incidence of mitotic figures was not high. The tubules of all of the testes showed more or less damage. Primary spermatocytes were present in many of the remaining tubules in most of the testes. Complete spermatogenesis was observed in some areas of the tubules of one mouse which had received 7500 i.u. in 101 days beginning at 28 days of age. Usually spermatogenesis was inhibited at the primary spermatocyte stage. Abnormal

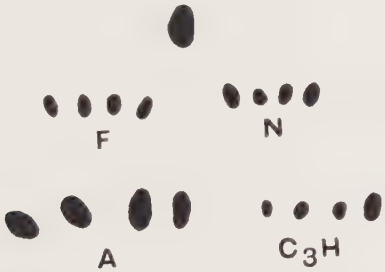

Fig. 1 Silhouettes of testes of a normal male mouse of the C_3H strain, and of four mice from each of four other strains following the injection of large amounts of estrogenic hormones for extended periods. The testes of the mice of the A strain were of normal size or only slightly smaller than normal. × 1.

primary spermatocytes were frequently found, apparently free in the tubules.

Eight male mice of a second strain (C_3H) were similarly given weekly injections of 500 i.u. of hydroxy-estrin benzoate for periods of 119 to 287 days starting at ages ranging from 3 to 39 days. The testes of the mice of this strain were very small in those animals in which the injections were started during the first week of life (fig. 1). The testes of the older animals were uniformly reduced to about one-half normal size. Evidence of increased size of the glandular interstitial cells was obtained in only one mouse though the number was apparently not increased (fig. 3). The interstitial cell response in mice of this strain to large amounts of estrogenic

hormone was definitely different from that of the former strain.

The seminiferous tubules showed a marked reduction in size, roughly proportional to the decreased size of the testes (fig. 3). Some of the tubules from animals treated for longer periods were lined almost entirely by Sertoli cells. In others spermatogonia and primary spermatocytes were found. The tubular damage was no more pronounced than that in the mice of the A strain similarly treated.

Eight mice from each of two other strains (N and F) and five mice of the CBA strain received similar amounts of hydroxy- or keto-estrin benzoate over comparable periods. In all of these mice the testes were smaller than normal (fig. 1). The glandular interstitial cells had neither increased in number nor size. The seminiferous tubules, in places, contained only Sertoli cells. In other regions a few spermatogonia and primary spermatocytes were found as previously mentioned in mice of the C_3H strain.

A second estrogenic hormone, equilin benzoate, has been injected into six male mice of the A strain for periods of 16 to 34 weeks at the rate of 0.1 mg. weekly. In three mice so treated large circumscribed areas of interstitial cells existed in the testes. Throughout the remainder of the testes thickened bands of interstitial cells widely separated the tubules. The testes of the three other mice in this group resembled those of the animals of the same strain receiving hydroxy-estrin benzoate.

Some tubules had been completely replaced in the interstitial cell areas. Others persisted as small spaces devoid of epithelium. Such tubules were present only occasionally in the testes of mice receiving hydroxy-estrin benzoate (fig. 5).

DISCUSSION

The interstitial cells were considered to be glandular cells, probably Leydig cells. The nuclear structure and cytoplasm were similar to those of the smaller glandular interstitial cells

of normal testes. The cytoplasm was vacuolated. The Leydig cells though enlarged and present in increased numbers in the testes of mice of the A strain following injection of estrogenic hormones did not produce sufficient male hormone to maintain normal seminal vesicles and prostates. Two possible explanations for the absence of demonstrable physiological activity seem worthy of consideration.

The changes in the testes occurred only following extended periods of treatment and after the male accessory reproductive organs had either failed to develop normally in the animals started at birth and/or had shown changes characteristic of estrogenic hormone administration. The smooth muscles of the seminal vesicles increased in thickness. The epithelium of the seminal vesicles had undergone squamous metaplasia in the proximal portions. The epithelium of the distal portions was low and indicated lack of secretory activity. Secretion was not observed in the lumen of the glands. The coagulating glands showed more or less marked squamous metaplasia and in the C_3H and F strains, some leucocytic infiltration. Similar observations have been reported by Burrows ('35). It is possible that such glands may be refractory to male hormone in normal or slightly increased amounts. On the other hand it is possible that the enlarged interstitial cells were storing or unable to liberate their products of secretion even though intracellular secretion had occurred.

Though a careful cytological study has not been made upon the pituitaries of the mice from the five strains, no striking variations have been observed among the several strains. They show the usual chromophobe increase or degranulation of the chromophilic cells and a slight increase in gross size.

Scrotal hernias were observed in many mice, occurring most frequently in mice from the A strain (Gardner, '36 a, b). As this condition was found to depend on the presence of testes of approximately normal size and the development of interpubic ligaments to replace the pubic symphyses the occurrence of hernias might be expected most frequently in this

strain. In the other strains, though scrotal hernias frequently appeared if injections were started at or after weaning age, they usually regressed and eventually disappeared as the testes decreased in size. Occasionally the testes permanently recede to the abdominal cavity, the scrota regressing. When the injections were started early in life the testes occasionally failed to descend and scrota failed to develop. This seldom occurred in male mice of the A strain when only 500 i.u. of hormone were given weekly. The characteristic response was observed in each strain whether the testes were 1) scrotal, 2) in the scrota with herniated viscera or 3) abdominal.

The changes in the testis might be attributed to endocrine factors. Considering the previously mentioned experiments undertaken by other investigators the results here reported might be interrupted to indicate that some estrogenic chemicals act upon the pituitary, stimulating the formation of increased amounts of a hormone (luteinizing hormone or interstitial cell stimulating hormone) capable of transforming the interstitial cells. This stimulation of the Leydig cells in the A strain of mice affected the number of cells and as the cells were larger than normal probably either increased the secretory activity of these cells or inhibited the liberation of the secretory products.

Whether the increased numbers of Leydig cells arose through division of existing glandular cells or multiplication and differentiation of other interstitial elements could not be determined. The transformation of Sertoli cells into Leydig cells could not be demonstrated.

SUMMARY

1. The testes of mice from one strain (Strong's A strain) showed a more or less extensive replacement of the seminiferous tubules with an increased number of large glandular interstitial cells following the injections of hydroxy-estrin-benzoate or equilin-benzoate.

2. The pyhsiological activity of these cells could not be determined.

3. Extensive damage of the seminiferous tubules occurred in mice from four other strains which received similar amounts of hydroxy-estrin benzoate but the glandular interstitial cells had not increased in number.

LITERATURE CITED

BURROWS, H. 1935 Pathological conditions induced by estrogenic compounds in the coagulating gland and prostate of the mouse. Am. J. Cancer, vol. 23, pp. 490–512.

——— 1936 A comparison of the changes induced by some pure oestrogenic compounds in the mammae and testes of mice. J. Path. and Bact., vol. 42, pp. 161–168.

EVANS, H. M., K. KORPI, M. E. SIMPSON, R. I. PENCHARZ AND D. H. WONDER 1936 On the separation of the interstitial cell stimulating, luteinizing and follicle-stimulating fractions of the anterior pituitary complex. U. of Calif. Pub. Anat., vol. 1, pp. 255–274.

GARDNER, W. U. 1936 a Sexual dimorphism of the pelvis of the mouse, the effect of estrogenic hormones upon the pelvis and upon the development of scrotal hernias. Am. J. Anat., vol. 59, pp. 459–483.

——— 1936 b Interstitial cell hypertrophy in the testes of mice receiving estrogenic hormones. Anat. Rec., vol. 67 (Suppl. no. 1), p. 49.

GREEP, R. O., H. L. FEVOLD AND F. L. HISAW 1936 Effects of two hypophyseal gonadotropic hormones on the reproductive system of the male rat. Anat. Rec., vol. 65, pp. 261–271.

LANE, C. E. 1934–1935 Some influences of oestrin on the hypophyseal gonad complex of the immature female rat. Am. J. Physiol., vol 110, pp. 681–685.

MOORE, C. R. AND D. PRICE 1932 Gonad hormone functions and the reciprocal influence between gonads and hypophysis with its bearing on the problem of sex hormone antagonism. Am. J. Anat., vol. 50, pp. 13–73.

WOLFE, J. M. 1935 Reaction of the ovaries of mature female rats to injections of oestrin. Proc. Soc. Exp. Biol. and Med., vol. 32, p. 757.

PLATE 1

EXPLANATION OF FIGURES

2 A photomicrograph of the testis of a normal male mouse of the C_3H strain. × 180.

3 A photomicrograph of the testis of a mouse of the C_3H strain which had received 15,000 i.u. of hydroxy-estrin benzoate in 212 days beginning at 3 days of age. × 160. The tubules had greatly decreased in size and contained only Sertoli cells, spermatogonia and a few abnormal primary spermatocytes. The glandular interstitial cells showed no increase in numbers or evidence of secretory activity.

4 A photomicrograph of a testis from a mouse of the A strain which had received 12,000 i.u. of a hydroxy-estrin-benzoate in 165 days beginning at 28 days of age. × 82.5. The small tubules contained Sertoli cells, spermatogonia and a few primary spermatocytes and are widely separated by hypertrophied glandular interstitial (Leydig) cells. The relative gross size of this testis is indicated in figure 1, being the first to be left in the A group.

5 A photomicrograph of a testis from a mouse of the A strain removed at 227 days of age after the injection of 16,000 i.u. of hydroxy-estrin-benzoate beginning at 22 days. × 165. The atrophic tubules are widely separated by Leydig cells. The epithelium of one tubule has completely disappeared.

2

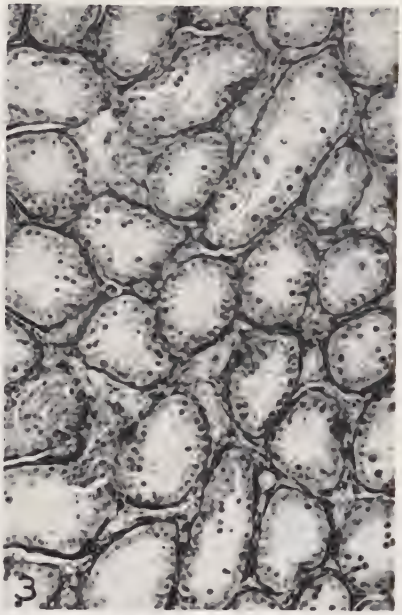
3

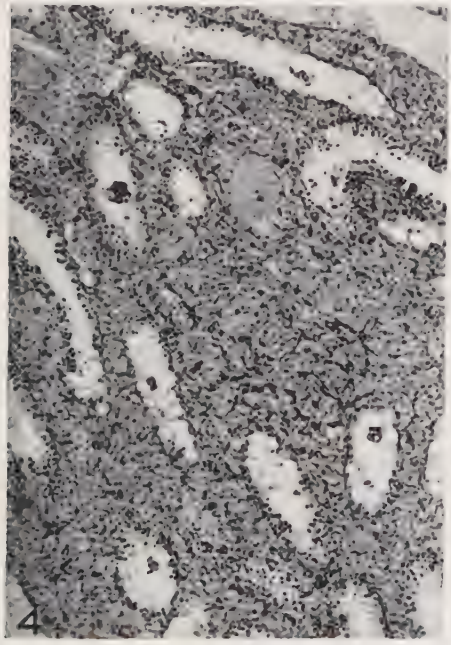
4

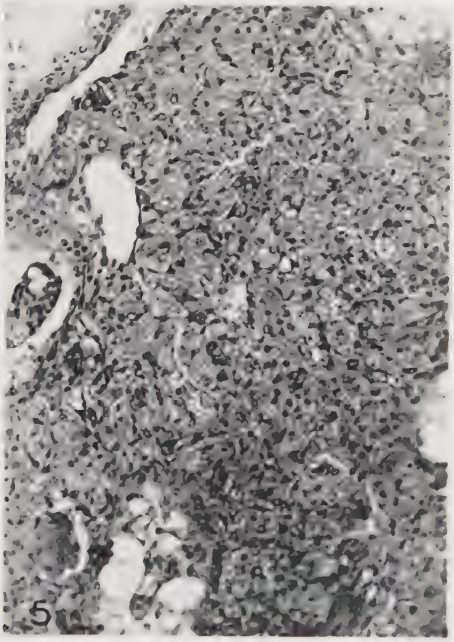
5

THE DEVELOPMENT OF GUT AND ITS DERIVATIVES FROM THE MESECTODERM AND MESENTODERM OF EARLY CHICK BLASTODERMS

THOMAS E. HUNT
Department of Anatomy, University of Alabama

THREE PLATES (ELEVEN FIGURES)

INTRODUCTION

It was suggested previously (Hunt, '32) that the question of whether cells in the early chick blastoderm are capable of self-differentiation and are localized in organ forming areas, might be answered by transplanting parts of a single germ layer. This procedure would obviate the possible induction of one germ layer by another during the period of growth of the grafted piece. However, since the blastoderm could be split into only two layers, the nearest approximation to such an experiment proved to be the transplantation of parts of the mesectoderm[1] and mesentoderm. In the subsequent grafts it was found, quite surprisingly, that gut and its derivatives developed from the mesectoderm but not from the early mesentoderm. As a consequence of this unexpected observation, emphasis was shifted from the original problem to an analysis of the derivation of definitive gut entoderm.

The results to be reported[2] are at variance with the long accepted theory that gut develops from the primary entodermal sheet which is invaginated prior to incubation and are

[1] The term 'mesectoderm' is used, here, in the sense defined by Webster's International Dictionary (2nd ed., 1934): "a cell layer not yet differentiated into mesoderm and ectoderm but destined to give rise to both." Accordingly, this use of the term should not be confused with that sometimes employed by students of amphibian embryos to designate mesenchymal cells of ectodermal origin.

[2] A preliminary account of this work was presented before the American Association of Anatomists in 1934.

so unorthodox that interpretations have been made with considerable hesitation. However, the conclusion is inescapable that the mesectoderm may give rise to certain parts of the digestive tract and that the primary entoderm does not possess a similar capacity. That this is certainly true for chorio-allantoic grafts will be shown in the present paper. That it is likewise valid for normal development is suggested by evidence obtained from vital staining experiments to be submitted in the next paper of this series. (In press.)

MATERIAL AND METHODS

The method of obtaining 9-day grafts by transplantation of donor tissue to the chorio-allantoic membrane of 8- or 9-day chick hosts has been adequately described by Willier ('24), his students and others. Since Dalton ('35) believes certain variations in the technique are important, it is to be noted that in the present work all cuts and dissections were made with Knapp knife needles and that transfer of the piece to be grafted, from Petri dish to membrane, was accomplished with the aid of a small pipette. In using this method of transfer the transplanted piece is damaged only slightly, if at all, provided the mouth of the pipette is of a correct size and adequate skill is employed. One of the more important advantages of the pipette technique is that the piece is immersed in saline at all times until placed on the membrane.

In preparing donor tissue from the younger specimens the blastoderm was separated into mesectoderm and mesentoderm by freeing the latter at the periphery of the area pellucida and gently peeling it from the former (figs. 1 and 2). Separation was comparatively easy and if not complete the blastoderm was discarded. To obtain pieces from pre-streak blastoderms it was usually necessary to incubate the eggs for a few hours in order for the primary entoderm to develop into an intact sheet. In advanced streak and head-process stages the mesentoderm could not be peeled away, especially at the streak, but had to be dissected loose and as a result

it was usually broken at some point. In such cases the few entodermal cells which remained with the mesectoderm were removed piecemeal or the blastoderm was discarded. Since there is no division into layers at the anterior end of the advanced streak, separation at such a level was arbitrary and some of the intermediate cells in the streak, which might possibly be entodermal, were transplanted with the mesectoderm. It is assumed, however, that only the deepest layer of cells constitutes the primary entodermal sheet. Before making the transplant of the mesectoderm all of the area opaca was removed and discarded.

The mesoderm transplanted with the entoderm was variable in amount and depended somewhat on the stage of development. In the earliest stages the amount was insignificant but as development of the mesoderm progressed and fusion of the germ layers at the streak occurred, more of it was likely to have been included with the entoderm. Although several attempts were made to dissect away the mesodermal cells, complete removal proved to be impossible.

RESULTS

As the work progressed, it became apparent that the mesectoderm and the mesentoderm have capacities for differentiation of gut and its derivatives which change with the age of the embryo. In order to study this age difference the grafts were obtained from blastoderms in stages ranging from the pre-primitive streak to the head-process, inclusive. In addition, an attempt was made to localize in a general way the area of the blastoderm capable of giving rise to digestive tract and, finally, to determine the time at which a definitive, gut-forming entoderm is established.

Altogether about 1300 transplants were made. Of this number approximately 500 hosts had died before the grafts were removed. The following table shows the number of grafts obtained, the number of grafts on which this report is based and the total number of transplants made to viable hosts. The grafts not tabulated either were necrotic or demonstrated very little differentiation.

Grafts of the mesectoderm of the entire area pellucida

These grafts were obtained only from pre-streak and short streak (up to 1.5 mm.) blastoderms, since in later stages it was not possible to separate an intact mesentoderm from the area pellucida.

The most striking features to be noted in this series (table 2 A) are the frequent occurrence of gut and the presence of liver, pancreas, thyroid gland and respiratory tract. There can be little question that the structures identified as gut actually are a part of the digestive tract. Although there are few morphological characteristics which serve as accurate

TABLE 1

REGION TRANSPLANTED	GRAFTS OBTAINED	GRAFTS TABULATED	TRANSPLANTS MADE TO VIABLE HOSTS
Entire mesectoderm, pre-streak	24	11	52
Entire mesectoderm, short streak	19	13	36
Mesectoderm, anterior streak levels	64	41	102
Mesectoderm, posterior streak levels	44	32	130
Mesectoderm of streak	37	27	88
Mesectoderm lateral to streak	50	42	158
Primary entoderm, pre-streak	0	0	29
Mesentoderm, short streak	0	0	65
Mesentoderm, long streak	11	11	103
Mesentoderm, head process	10	10	30
Totals	259	187	793

criteria for distinguishing gut in grafts, some are considered reliable. Below the esophagus the general appearance of the digestive tract of a 9-day chick is that of an epithelial tube surrounded by a mesenchymal tunica propria, a tunica muscularis and a tunica serosa. In many grafts all of these features are seen except the serosa which is usually lacking. In some, the muscular tunic is likewise absent from the epithelial tube and as a consequence gut can be identified only by means of its association with related structures such as liver.

The presence of liver, thyroid, respiratory tract and pancreas offers indubitable proof that the mesectoderm has the capacity to form so-called entodermal structures. Identification of liver is made with assurance, since it has a very

TABLE 2

Summary of structures appearing in grafts

	NUMBER OF GRAFTS	LENGTH OF STREAK IN MILLIMETERS	GUT WITH TUNICS	GUT WITHOUT TUNICS[1]	UNIDENT. EPITH. TUBES[2]	ORAL EPITHELIUM	PHARYNX	ESOPHAGUS	STOMACH	INTESTINE	RECTUM	THYROID	RESPIRATORY TRACT	LIVER	PANCREAS	HEART	MESONEPHROS	CARTILAGE	SKELETAL MUSCLE	SKIN	FEATHER GERMS	CENT. NERVOUS TISSUE	GANGLION CELLS	EYE	EPIPHYSIS	NOTOCHORD
A	11	0.00	8	3		1			1	3			1	3	1	6	2	5		3	2	5	4	1		1
Mesectoderm	1	0.45	1				1			1																
of entire	2	0.75	1	1						2				2		2		1				1				
area	7	0.90	6	1		4	3		2	5	2	2	2	3	1	3	1	3	2	2	1	2	3			2
pellucida	1	1.35	1				1			1			1					1		1		1	1			1
	2	1.50	1	1		1				2	1			1		1		1								
Totals	24		18	6		6	5		3	14	3	2	4	9	2	12	3	11	2	6	3	9	8	1		4
	2	1.05	2				1			2		1	1	1		2		1	1			2	1	1		
	3	1.20	1	2		2	1			2			1	3	1	1		2		1	1	3	1	2		
B	4	1.35	4			2	2		1	3		2	1	4	2	3		1		1		4	1	1		1
Mesectoderm	2	1.50	1	1		1	1			2				1		1		1		1	1	1	2	1		
of anterior	2	1.65	2							1		1		1		1	1	2	1	2	1	2	2	1		
streak level	7	1.80	7			4	4	1	2	6	1	4	5	2		7	4	6	4	5	5	7	6	2	1	5
	9	1.95	8	1		2	2	1		5		1	5	3	1	5	4	7	5	5	5	8	6	2	3	5
	3	2.10	1		2	1				2			1				1	3	2	2	2	3	2		1	3
	9	H-p[3]			9												1	9	4	6	6	9	6	2		3
Totals	41		26	4	11	12	11	2	3	23	1	9	14	15	4	20	11	32	17	23	21	39	27	12	5	17
C	1	1.65	1							1								1		1						
Mesectoderm	10	1.80	10							7	2		1	2		3		1	1	2	2	1	2			1
of levels	7	1.95	5		2					2	1					1	1	4		5	5	1				
posterior to	7	2.10	5		2					1				1		1	2	3	2	3	3	2	3			2
the pit	7	H-p[3]	5		2					5							5	7	4	6	6	4	4			1
Totals	32		26		6					16	3		1	3		5	8	16	7	17	16	8	9			4
	2	0.90	2			1	1		1	2		1	1	2	2	2		2	1	1	1	2	2	1		1
	2	1.20	2							2		1		2	1	2						2	1			
D	3	1.50	3							3	1	1	2	3		3		2	1	1	1	3	3			
Mesectoderm	5	1.65	5			2	2	1	3	4	2		1	2		3	1	5	3	5	4	5	3	3		3
of streak	8	1.80	4	4						5				4		6	1	5	1	3	2	5	4	1	1	3
	3	1.95	2	1						2			2				2	3	1			3	3			1
	4	2.10	2		2					2						1	1	4	2	3	3	4	4	1	1	3
Totals	27		20	5	2	3	3	1	4	20	3	3	6	13	3	17	5	21	9	13	11	24	20	6	2	11
	1	0.90	1							1	1															
	4	1.20	3	1						3				1		1										
E	7	1.50	5		2					3												1				
Mesectoderm	7	1.65	5		2					5	1									1	1					
lateral to	7	1.80	5		2					4	1							4		5	3	3		2		
streak	6	1.95	5		1					4	1					1		4	1	3	3	3	4			
	7	2.10	5		2					4						1		4	1	3	2	3	1			
	3	H-p[3]	3							2	1							2		1		2				
Totals	42		32	1	9					26	5			1		3		14	2	13	9	12	5	2		
	2	1.65			2																					
F	4	1.80		1	3									1		2										
Mesentoderm	5	1.95	2		3					1	1			1		1										
	10	H-p[3]	9	1					3	8		4		7	3	8		3								
Totals	21		11	2	8				3	9		5		9	3	11		3								

[1] Listed only when gut with tunics is not present.
[2] Listed only when gut is not identified.
[3] H-p indicates head-process stage.

characteristic appearance in chorio-allantoic grafts (fig. 8). In this series its association with heart tissue follows regularly the correlation discussed by Willier and Rawles ('31). The recognition of thyroid (fig. 9) and respiratory tract has been based on the description of Rudnick ('32, '33). The frequency with which these structures occur is undoubtedly greater than is indicated in the table, since some not recorded were too slightly differentiated to be identified with certainty. Pancreas, which appears only occasionally, is characterized by cuboidal epithelium surrounding an open lumen, the branching tubules being embedded in a richly vascular mesenchyma. It is frequently mixed with liver (fig. 10).

It is of interest to note the divisions of the digestive tract observed. In most cases the gut resembles upper intestine with a characteristic stellate lumen and an epithelium that has two or three layers of nuclei. In three cases some of the gut is similar to rectum (fig. 7) in that the lumen is almost closed by thick, vacuolated epithelium. Whether this represents a true differentiation of a specific level or is due to conditions in the graft has not been determined. Other parts identified are oral cavity, pharynx and ventriculus, the latter characterized by a heavy muscular coat and thick epithelium showing a typical secretion on the surface.

Although additional structures such as nervous tissue, mesonephros, skeletal muscle, cartilage, feather germs and skin are present in some of the grafts, they will not be discussed in the present paper. In may be pointed out, however, that notochord, considered by some to arise from the early entoderm, is present in many of these and other transplants from which the entoderm was entirely removed.

Grafts of the mesectoderm that include the anterior streak level

The grafts of this series (table 2 B) were of area pellucida mesectoderm from which posterior streak levels were excluded. Donor blastoderms ranged from the short primitive

streak through the head-process stage. In the earlier stages a transverse cut was made 0.15 to 0.4 mm. posterior to the primitive pit or its approximate future location. All of the mesectoderm anterior to the cut was included in the transplant except in a few instances in which the area anterior to the node was transplanted separately. In the head-process stage, the cut was made through the primitive pit and as much of the area anterior to it as could be freed from entoderm was transplanted. Complete removal of the entoderm in an intact piece proved impossible in the older stages and a few cells may sometimes have been left in place. Therefore, a review of the results obtained in grafts from these stages must be made with the reservation that some entoderm may have been included in the transplanted part.

In practically all of the grafts from blastoderms in stages up to and including the definitive streak, some part of the digestive tract is represented. The gut is most often small intestine with well-developed fibrous and muscular tunics (figs. 3 and 5). Occasionally a ventriculus or proventriculus is present. There are also what are considered to be oral or pharyngeal cavities continuous in some cases with a tube lined with columnar epithelium and surrounded by a thin layer of circular muscle. In all probability the latter represents esophagus.

In addition to the digestive tract proper its derivatives are often seen in grafts from the earlier blastoderms. Reference to table 2 B indicates that these structures occur in diminishing frequency as the head-process stage is approached, being entirely lacking in the grafts of the latter stage.

There is some question as to whether gut develops in head-process grafts. Tubules are present which have an epithelium that is sometimes similar to that of gut but muscular and serous tunics are absent. It is to be recalled that some entodermal cells may have been included in these transplants, which may explain the origin of the tubules if they are to be interpreted as parts of the gut. However, the absence of all

digestive tract derivatives does not support such an idea. Furthermore, it will be shown below that the mesentoderm at such a time has the capacity to differentiate gut—a fact which suggests that the definitive entoderm has been partially established, at least in the region of the head-process anterior to the pit.

Grafts of the mesectoderm posterior to the primitive pit

The grafts of this series (table 2 C) were obtained from strips 0.3 mm. to 0.5 mm. in antero-posterior width of the area pellucida mesectoderm posterior to the primitive pit. The anterior transverse cut passed either through the primitive pit (all head-process and a few younger stages) or from 0.15 mm. to 0.6 mm. posterior to it (younger stages).

A part of the gut considered to be intestine is present in practically all grafts that show differentiation. Although foregut has not been identified, liver and part of the respiratory tract have been seen occasionally in cases in which the anterior cut passed through the pit.

The grafts from the levels posterior to the pit of the head-process stage show better developed gut than do those from the more anterior level of similar blastoderms, even though there is greater certainty that all entoderm was removed from the posterior levels. It thus seems probable that in this stage the anterior mesectoderm is losing or has lost its capacity to form gut; whereas, more posteriorly the capacity is still retained.

Grafts of the mesectoderm of the primitive streak

Either the entire streak mesectoderm or its anterior part was transplanted for these grafts. Since differentiation is essentially the same in both types of transplants, they are treated as a single group. Cuts to remove the lateral mesectoderm extended from the anterior to the posterior margin of the area pellucida parallel to and at distances ranging between 0.18 and 0.24 mm. lateral to the center of the streak. Grafts were obtained only from early and definitive streak stages.

Part of the digestive tract occurs in practically all specimens (table 2 D). In several, especially those of earlier stages, there are pharynx, esophagus and ventriculus. Intestine is likewise found and is the only part of the gut that has been identified in grafts from the advanced definitive streak stage.

Derivatives of the gut occur more frequently in grafts from earlier than in those from later stages. Thus, it is again demonstrated that the mesectoderm gradually loses its capacity to form entodermal structures as later stages are approached.

Grafts of the mesectoderm lateral to the primitive streak

Most of these grafts were obtained from the same donors that contributed the primitive streak transplants described in the preceding section. The position of the cuts is given there. In addition a few grafts were obtained from blastoderms in the head-process stage.

In most cases exhibiting differentiation, part of the digestive tract is present (table 2 E). Only the intestine, including perhaps the rectum, has been identified. Except for the serosa the tunics are usually well developed.

A derivative of the digestive tract has been found in a single case, one in which a small mass of liver is associated with heart. Absence of heart in all but this one graft may explain the absence of liver (Willier and Rawles, '31). Although Rudnick ('32) noted heart and liver in grafts of lateral pieces which included all germ layers from definitive streak blastoderms, her cuts were made somewhat nearer the streak and her specimens probably did not include the younger stages. Also to be harmonized are the observations of Rudnick ('32) and Rawles ('36) that the thyroid and liver forming areas are located lateral to the node in the head-process stage. While thyroid and liver are not found in the grafts of the lateral mesectoderm of a comparable stage, they do appear in those of the lateral mesentoderm and, therefore, it is assumed that by this time the cells destined to form these structures have become a part of the definitive entoderm.

Grafts of the mesentoderm

The transplants of the mesentoderm were obtained from the same blastoderms that provided the grafts of the mesectoderm. In early stages the mesoderm remains with the ectoderm so that very little, if any, was included in the transplants of the primary entodermal sheet. In later blastoderms the mesoderm blends so completely with the entoderm, especially at the anterior end of the streak, that a variable amount was always included. Consequently, in succeeding paragraphs the grafts from younger blastoderms, which are free from mesoderm, will be designated primary entodermal and those from older blastoderms, mesentodermal.

Two hundred and twenty-seven transplants of either the primary entoderm or the mesentoderm were made to viable hosts. From these, only twenty-one grafts were recovered of which thirteen showed structures that may certainly be considered as digestive tract or its derivatives (table 2 F). Further, it is significant that these thirteen grafts were obtained from blastoderms in the late definitive streak or head-process stage and mostly from the latter. Even though the lack of grafts from earlier stages is evidence of a negative nature, it is believed that if primary entoderm has any capacity for differentiation, some indication should have been present in at least one of the many transplants.

Several mesentodermal grafts obtained from blastoderms in the definitive streak stage contain small, short tubules lined with columnar epithelium. It was not possible to determine whether such structures are gut formed by the transplanted entoderm or are tubules formed by the chorio-allantoic membrane. They are continuous with the epithelium of the latter in some cases but this may indicate secondary fusion rather than derivation. In any event they do not resemble a part of the gut. Digestive tract occurs definitely in only three of the 103 transplants from blastoderms with definitive streaks. Such a low frequency of occurrence indicates that the mesentoderm has a very slight capacity for differentiation in this stage.

Not until the head-process stage is reached does the differentiation of digestive tract and its derivatives occur in a large percentage of grafts of the mesentoderm. Ten such grafts were obtained from twenty transplants of either the area anterior to the pit or that lateral to the node and head process. None were obtained from more posterior levels. Gut, which occurs in all grafts, is considered to be intestine in most cases but ventriculus is also sometimes present. Pancreas (fig. 11), liver and thyroid occur with varible frequency. Liver and thyroid are also present in grafts from an area lateral to the node and head-process, an observation in close accord with the previously mentioned results of Rudnick and Rawles.

DISCUSSION

The results of these experiments are sufficiently clear cut, it is belived, to warrant the conclusion that the mesectoderm when transplanted to the chorio-allantoic membrane has the capacity to form digestive tract and its derivatives until gut-forming entoderm becomes established in the head-process stage. The question arises whether gut also develops from the mesectoderm in normal development or appeared in the grafts only because of the conditions of the experiment. The latter alternative would presume that regulation or regeneration of primary entoderm from mesectoderm had occurred which in turn gave rise to gut and its derivatives. It would be difficult to prove from the study of the grafts alone that this does not occur but the idea that the sequence is normal is supported by results to be described in a subsequent paper where it will be shown that the mesectoderm contributes cells to the entoderm in primitive streak stages. The lack of gut and its derivatives in grafts of the entoderm from early blastoderms likewise favors the same view, because it indicates that the primary entoderm cannot form digestive tract and that some other part of the blastoderm, i.e., the mesectoderm, has this function. Even if gut had developed in transplants of the early entoderm, it might still be said, without resorting to

regeneration as an explanation, that part of the gut arises normally from the primary entoderm and part from cells contributed by the primitive streak.

If the early entoderm of the chick does not have the capacity to differentiate gut, what may its function be? Although the present experiments do not offer any positive evidence on this point, they do tend to invalidate or support certain previous suggestions. According to Dalton ('35), the entoderm appears to be essential for mesoderm formation in those stages in which there is a rather rapid movement of the material of the ectoderm toward the middle of the streak. Inasmuch as the mesoderm not only continues to form but also to differentiate in grafts of the mesectoderm of blastoderms from pre-streak to definitive streak stages, such an idea is apparently not tenable. This does not imply, however, that the primary entoderm cannot "induce the form building movements which lead to the development of the primitive streak," as Waddington ('33) suggests. In the present study the primary entoderm was established as an intact layer in all of the blastoderms from which grafts of the pre-streak stage were made and, therefore, it is quite possible that the induction of the form-building movements had already been accomplished in the ectoderm prior to transplantation. On the other hand, the grafts show that the continued presence of the entoderm is unnecessary for the differentiation of structures in the mesectoderm. Thus, Waddington's conclusion that it does not induce specific structures is indirectly supported. In addition to his induction experiments, Waddington ('32) followed the development of the mesectoderm from middle and late primitive streak blastoderms on a culture medium and found a 'false or regenerated fore-gut' in two cases (227 and 402). Concerning these 'mesodermal membranes,' which in his photographs appear very much like early gut, he states, "In both cases the formation of a membrane may be due merely to the fact that the cells were in contact with the surface of a liquid filling the cavity below them." In the light of the present experiments, however, it appears

probable that these membranes do actually represent a formation of gut from the mesectoderm. In similar cultures of the mesentoderm he found no anatomical differentiation.

Some of Dalton's ('35) chorio-allantoic grafts also suggest that gut forms from parts of blastoderms from which the entoderm has been removed. His table 2 indicates that five of eight such grafts from early and definitive streak stages have gut but he does not state whether a specific region has differentiated nor whether gut derivatives were identified.

Willier (personal communication) has also obtained grafts of the mesectoderm and mesentoderm. In the former he did not find structures that could be identified with certainty as gut but this may be explained by the fact that most of his grafts were obtained from blastoderms in the definitive streak or older stages. The entoderm alone gave little or no differentiation in his grafts.

Although some attempt was made to localize the gut-forming area of the mesectoderm in the present experiments, it was done only in a general way. The streak and the region lateral to it both seem capable of giving rise to some part of the digestive tract provided the blastoderm has not developed too far. The vital staining experiments, to be discussed in the next paper ('37), indicate that some of the cells that are at first located in the ectoderm lateral to the streak subsequently are displaced medially and ventrally to the definitive entoderm, at least in the anterior end of the streak.

Sufficient data are not at hand to make a definite statement in regard to the location of areas that give rise to specific levels of the digestive tract. It seems, however, that the foregut is formed from material which lies only in the anterior part of the early streak and that the mid- and hind-gut may be derived from cells situated more posteriorly and laterally.

The grafts indicate that the period at which gut-forming entoderm is definitely established is probably about the beginning of the head-process stage; however, the staining experiments suggest that some definitive entoderm is established

sooner. Perhaps this slight discrepancy in time may be explained by presuming that a sufficient number of gut-forming cells must be present before their self-differentiation can be realized.

SUMMARY AND CONCLUSIONS

1. The attempt was made to obtain chorio-allantoic grafts of the entire or various isolated parts of the mesectoderm and mesentoderm from blastoderms ranging from pre-streak to head-process stages.

2. Grafts of the mesectoderm from blastoderms in pre-streak and short streak stages show that it has the capacity to form digestive tract and derivatives such as liver, thyroid, pancreas and respiratory tract.

3. Grafts of parts of the mesectoderm from blastoderms in definitive streak and head-process stages show that this capacity is gradually lost in anterior streak or head-process levels although a part of the gut may still form from a region posterior to the node level or from that lateral to the streak.

4. The mesentoderm lacks the capacity to differentiate gut and its derivatives in grafts from blastoderms in stages prior to the late definitive primitive streak.

5. It is concluded that the so-called entodermal structures observed in the grafts of the mesectoderm are derived directly from it and are not the products of regenerated primary entoderm.

6. The grafts indicate that the definitive entoderm does not become established until the head-process stage is reached or shortly prior to that time.

LITERATURE CITED

Dalton, A. J. 1935 The potencies of portions of young chick blastoderms as tested in chorio-allantoic grafts. J. Exp. Zool., vol. 71, p. 17.

Hunt, T. E. 1932 Potencies of transverse levels of the chick blastoderm in the definitive-streak stage. Anat. Rec., vol. 55, p. 41.

——— 1934 The differentiation in chorio-allantoic grafts of gut and liver from the mesectoderm of early chick blastoderms. Anat. Rec., vol. 58 (Suppl.), p. 21.

——— 1937 The origin of entodermal cells from the primitive streak of the chick embryo. Anat. Rec., vol. 68. (In press.)

RAWLES, M. E. 1936 A study in the localization of organ-forming areas in the chick blastoderm of the head-process stage. J. Exp. Zool., vol. 72, p. 271.

RUDNICK, D. 1932 Thyroid-forming potencies of the early chick blastoderms. J. Exp. Zool., vol. 62, p. 287.

——— 1933 Developmental capacities of the chick lung in chorio-allantoic grafts. J. Exp. Zool., vol. 66, p. 125.

WADDINGTON, C. H. 1932 Experiments on the development of chick and duck embryos, cultivated in vitro. Phil. Trans. Roy. Soc. Ser. B., vol. 221, p. 179.

——— 1933 Induction by the endoderm in birds. Arch. f. Entwmech. d. Organ., Bd. 128, S. 502.

WILLIER, B. H. 1924 The endocrine glands and the development of the chick. Am. J. Anat., vol. 33, p. 67.

WILLIER, B. H. AND MARY E. RAWLES 1931 Developmental relations of the heart and liver in chorio-allantoic grafts of whole chick blastoderms. Anat. Rec., vol. 48, p. 277.

PLATE 1

EXPLANATION OF FIGURES

1 Whole mount of the mesentoderm from a blastoderm with a short primitive streak. Note that some mesodermal cells of the streak remain with the entoderm and that the sheet is intact except at the periphery which was injured during preparation of the mount. × 19

2 Whole mount of the mesectoderm from the same blastoderm as shown in figure 1. × 19.

3 Intestine with characteristic epithelium and tunics which appears in graft 56-38 of the mesectoderm from the anterior streak level of a blastoderm with a streak 1.65 mm. in length. × 160.

1

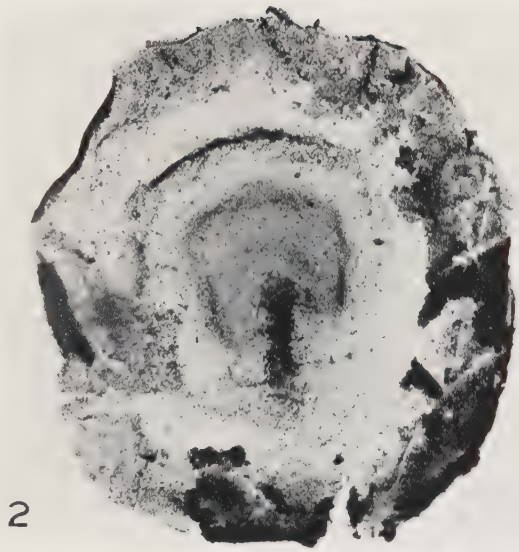
2

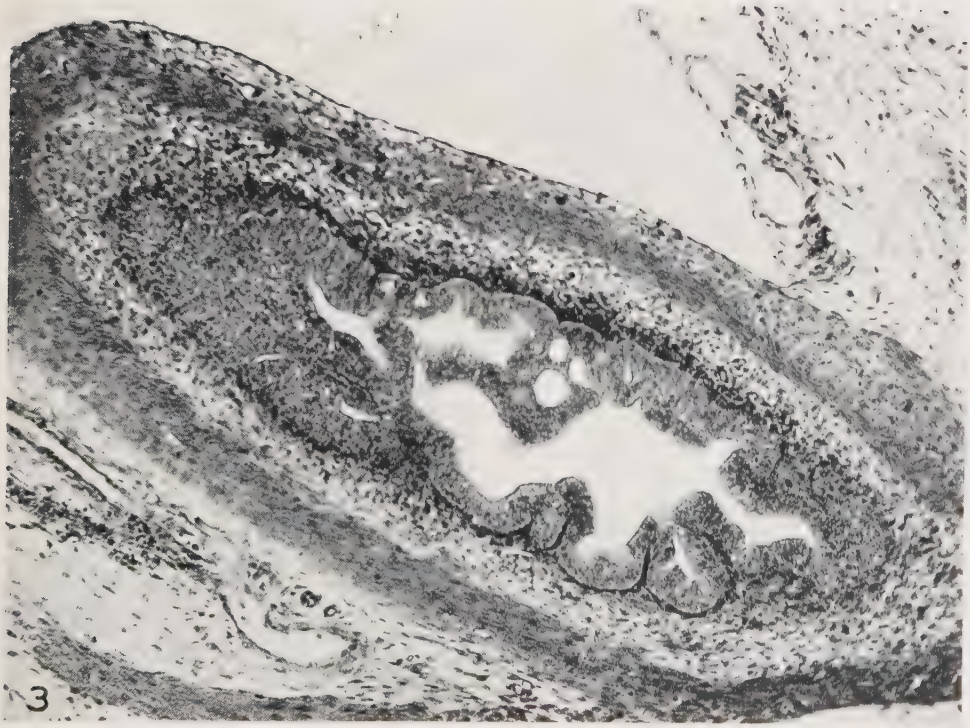
3

PLATE 2

EXPLANATION OF FIGURES

4 Intestine from a 9-day chick embryo. × 203.

5 Gut with epithelium and tunics similar to that shown in figure 4 which appears in graft 103-15 of the mesectoderm from the anterior streak level of a blastoderm with a streak 1.35 mm. in length. × 203.

6 Rectum from an 8-day chick showing tall vacuolated epithelium. × 81.

7 Rectal-like mucosa similar to that shown in figure 6 which appears in graft 61-17 of the mesectoderm lateral to the streak from a blastoderm with a streak 1.8 mm. in length. × 81.

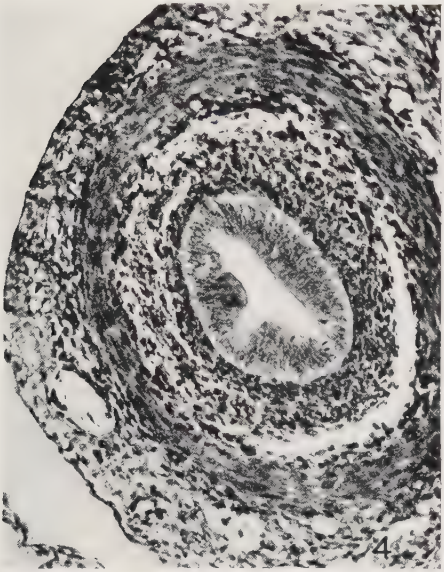
4

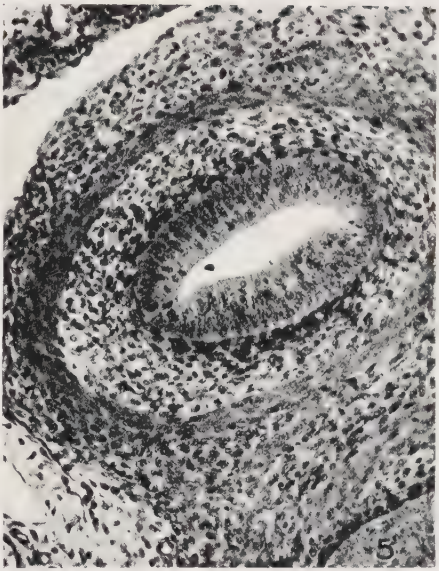
5

6

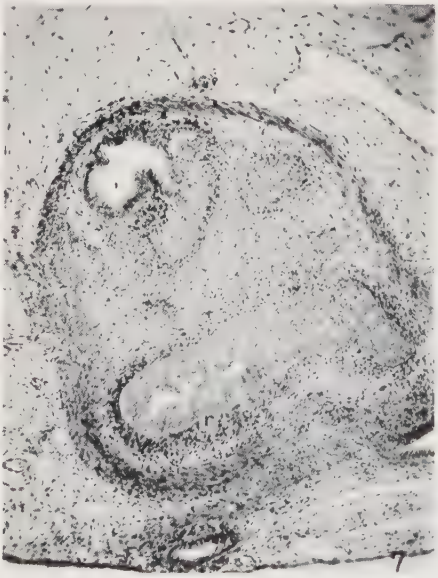
7

PLATE 3

EXPLANATION OF FIGURES

8 Liver (l) which appears in graft 55-84 of the mesectoderm from the anterior streak level of a blastoderm with a streak 1.65 mm. in length. × 224.

9 Thyroid (t) which appears in the same graft as that of figure 8. × 244.

10 Liver (l), pancreas (p), and heart tissue (h) which appears in graft 92-1 of the streak mesectoderm from a blastoderm with a streak 1.20 mm. in length. × 148.

11 Intestine and pancreas (p) which appears in graft 88-21 of the mesentoderm anterior to the node of a blastoderm with an advanced head-process. × 148.

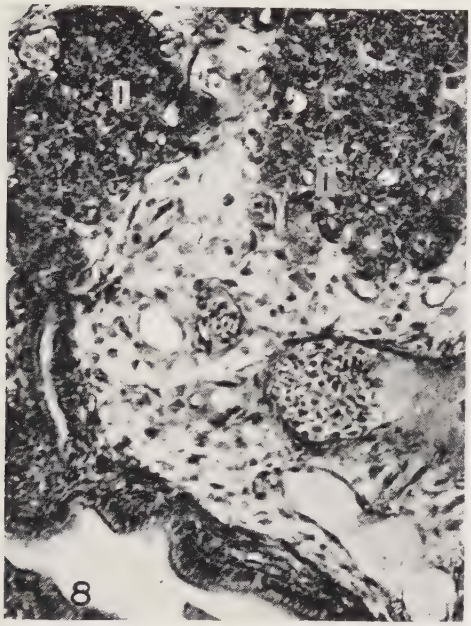
l
l
8

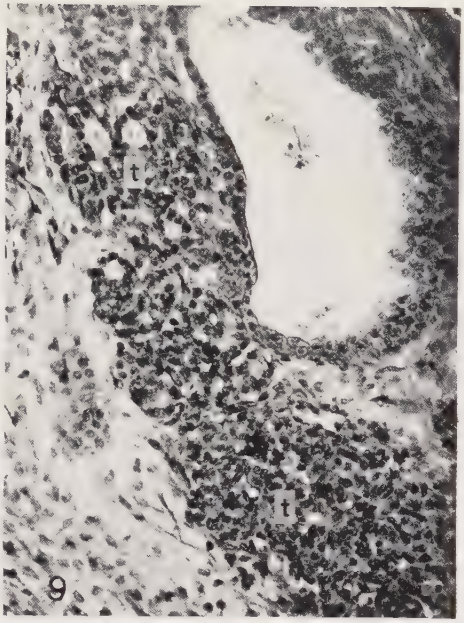
t
t
9

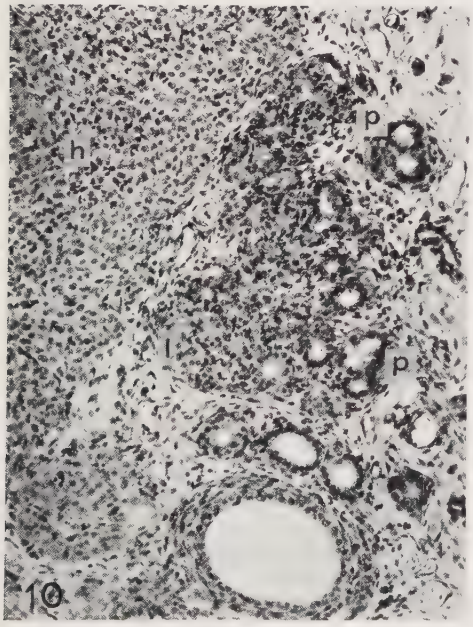
p
h
l
p
10

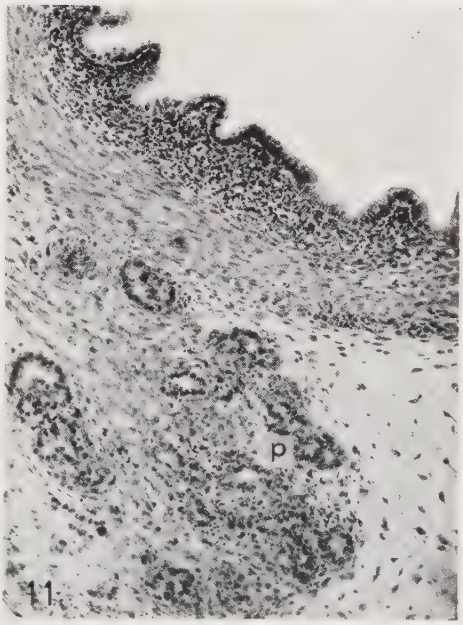
p
11

RECOVERY OF RATS UPON REFEEDING AFTER PROLONGED SUPPRESSION OF GROWTH BY UNDERFEEDING [1]

C. M. JACKSON

Department of Anatomy, University of Minnesota, Minneapolis

ONE FIGURE

There is still some uncertainty as to whether prolonged inanition may injure the young organism so as to render it incapable of later growth to normal adult size. Apparently permanent dwarfing of young rats by underfeeding was obtained by Jackson and Stewart ('20) and more recently by McCay , Crowell and Maynard ('35). On the other hand full recovery was observed by Osborne and Mendel ('14, '15) after long retardation chiefly by protein deficiency. Complete recovery was also claimed by Clemmesen ('33) following vitamin B-deficient diet, and by Guastalla and Rigoletti ('35) with comparable underfeeding experiments.

Jackson ('36) recently restudied the question with adequate controls and numbers sufficient for statistical treatment. Young rats were held at constant body weight for 15 weeks by a protein-deficient diet. On full refeeding with normal diet, the female survivors overtook the normal controls. The males failed to recover fully and remained slightly (but significantly) stunted. In order to determine whether the result depends upon the type of diet used, it seemed desirable to repeat the experiment under similar conditions, but with suppression of growth through underfeeding instead of protein-deficiency. Males only were used in the present study, since they seemed to be more susceptible to the effects of inanition.

[1] Aided by a grant from the research funds of the Graduate School, University of Minnesota.

MATERIALS AND METHODS

As in the previous study, the rats used were from the colony in the Institute of Anatomy derived originally from the Wistar albino experimental strain. In the present work 113 male rats were used. Of these, 45 were taken as normal controls, 1 of which was later discarded on account of disease. Of the 68 test rats, 29 died during the experiment, and were excluded, together with 1 badly diseased. This left 38 surviving test rats and 44 controls for consideration. All were weaned and weighed on the twenty-first day of age, when the experiment began. So far as possible the littermates were distributed between test rats and controls.

The test rats were placed in individual cages. Each was fed daily the following mixture of accessories: Casein 1.0 gm., dried yeast 0.2 gm., wheat germ 0.2 gm., cod liver oil 0.1 gm., salt mixture (McCollum 185) 0.1 gm. This amount (with city tap water ad libitum from a bottle in each cage) provides adequate nutrition for maintenance, excepting calories. In addition sufficient stock food in measured amounts was fed daily as required to hold the body weight approximately constant over a period of 15 weeks. The stock food consists of the following mixture: Crude casein, 15%; whole milk powder, 10%; sodium chloride, 0.8%; calcium carbonate, 1.5%; butter, 5.2%; ground whole wheat, 67.5%. To this mixture, 1% of cod liver oil was added. During the 15 weeks of growth repression, the test rats were weighed daily. Thereafter they were placed on the stock diet ad libitum (the same as the controls) and were weighed at intervals of 1 week or less.

The control rats were fed the regular stock diet ad libitum throughout, tap water being supplied from glass bottles with glass siphon outlets. Not more than three or four rats were placed in the same wire cage, about 1 cubic foot in volume. They were each weighed weekly. Records of the food consumed were kept. Where there was more than one rat in the same cage, it was assumed that the food was consumed equally by each individual. This estimate might be erroneous for an individual, but not for the average of the group.

Both test rats and controls were kept throughout the entire experimental period, from 3 to 60 weeks of age, in a constant temperature room at about 26°C. (79°F.), with a daily variation rarely exceeding 1°C.

At about 60 weeks of age, both test rats and controls were finally killed by chloroform and carefully autopsied with the same technique previously used. The means and coefficients of variation for the body and various parts are shown for the 38 test rats and the 44 controls in table 1. In the case of a few organs, the numbers were slightly (one to four) less, where organ weights were missing or excluded on account of marked abnormality. The last column gives the difference of the means (subtracting control from test data), and indicates the standard error of difference. If the difference is more than twice the standard error, it is considered as significant, with less than one chance in twenty that it is the accidental result of random sampling.

OBSERVATIONS

General appearance

The control rats remained healthy and normal in appearance throughout the experiment, excepting the one rat excluded on account of chronic lung disorder with notable decrease in body weight.

The test rats showed changes in general resembling those previously described for the rats subjected to protein deficiency, with progressive emaciation. The back becomes humped, the eyeballs prominent and the penis is usually extruded. The hair coat becomes thin. No evidences of vitamin deficiency (ophthalmia, rickets, polyneuritis, pellagra) were noted either during life or at autopsy.

The severity of the inanition is evident from the twenty-nine deaths, a mortality of 42%. The deaths occurred chiefly from enteritis and pneumonia during the latter part of the repression period. The thirty-eight surviviors, although somewhat emaciated, remained active and vigorous. Upon

TABLE 1

Growth after repression by underfeeding. Males. Weight in grams. Nose-anus and tail lengths in centimeters

ORGAN OR PART	FORTY-FOUR CONTROL RATS		THIRTY-EIGHT TEST RATS		DIFFERENCE OF MEANS ± S.E.
	Mean ± S.E.	Coefficient of variation	Mean ± S.E.	Coefficient of variation	
Body weight	477.3 ±8.3	11.5	400.3 ±8.5	13.0	—77.0 ±11.9[1]
Nose-anus length	25.25 ±0.11	2.9	24.09 ±0.14	3.5	—1.16 ± 0.18[1]
Tail length	23.18 ±0.15	4.4	22.34 ±0.15	4.0	—0.84 ± 0.21[1]
Head weight	30.22 ±0.31	6.7	27.85 ±0.33	7.2	—2.37 ± 0.45[1]
Skeleton, muscle and spinal cord	221.1 ±3.0	8.9	191.8 ±3.0	9.6	—29.3 ± 4.2[1]
Left humerus	0.5307±0.0084	10.5	0.4612±0.0066	8.8	—0.0695± 0.0107[1]
Left femur	1.2877±0.0173	8.8	1.1002±0.0128	7.2	—0.1876± 0.0215[1]
Integument	78.8 ±1.6	13.2	69.3 ±1.8	17.6	—9.5 ± 2.4[1]
Brain	2.118 ±0.015	4.7	2.084±0.014	4.1	—0.034 ± 0.020
Hypophysis	0.0110±0.0003	15.6	0.0107±0.0002	14.7	—0.0003± 0.0004
Eyeballs	0.4064±0.0023	3.7	0.3944±0.0023	3.5	—0.0120± 0.0033[1]
Submaxillary glands	0.6114±0.0085	9.2	0.5941±0.0082	8.5	—0.0173± 0.0118
Thyroid gland	0.0402±0.0011	18.1	0.0324±0.0013	25.2	—0.0078± 0.0017[1]
Thymus	0.212 ±0.010	29.7	0.171 ±0.007	26.6	—0.041 ± 0.012[1]
Heart	1.408 ±0.021	9.8	1.283 ±0.020	9.4	—0.126 ± 0.029[1]
Lungs	2.144 ±0.084	24.6	2.026 ±0.102	30.6	—0.118 ± 0.132
Liver	17.35 ±0.40	15.2	15.87 ±0.34	13.4	—1.47 ± 0.53[1]
Spleen	0.871 ±0.015	11.5	0.787 ±0.021	16.5	—0.084 ± 0.026[1]
Suprarenals	0.0387±0.0010	17.9	0.0349±0.0006	10.9	—0.0038± 0.0012[1]
Kidneys	3.344 ±0.064	12.2	3.284 ±0.071	13.3	—0.060 ± 0.095
Stomach with contents	2.86 ±0.20	47.5	3.00 ±0.25	50.0	+0.14 ± 0.32
Stomach, empty	1.500 ±0.022	9.6	1.448 ±0.025	10.7	—0.052 ± 0.034
Intestines with contents	23.65 ±0.82	23.1	20.93 ±0.59	17.3	—2.72 ± 1.01[1]
Intestines empty	4.565 ±0.100	14.3	4.606 ±0.070	9.1	+0.041 ± 0.122
Testes	2.959 ±0.062	13.8	2.951 ±0.074	15.2	—0.008 ± 0.096
Epididymides	1.162 ±0.023	12.9	1.203 ±0.026	13.2	+0.040 ± 0.035

[1] Significant difference.

full refeeding at the end of the 15 weeks of underfeeding, they grow rapidly and within 2 or 3 weeks became fairly normal in appearance.

Although the fatalities among the malnourished test rats seemed to indicate an increased susceptibility to infections, no evidence of a weakened resistance appeared among the survivors at autopsy. On the contrary, the lung disorder appeared rather more conspicuous in the control rats. Similarly middle ear infection, with pus evident on removing the tegmen tympani, was noted at autopsy in 26 of the 44 controls (or 59%), but in only 14 of the 38 test rats (or 37%). This difference may be insignificant; but it possibly represents the result of a selective process, the rats more susceptible to infection having been eliminated by death during the experiment.

Body weight

As shown by the growth curve in figure 1, the forty-four controls increased from an average weight of about 54 gm. at 3 weeks to 477 gm. final at 60 weeks of age. The growth curve for these males terminates about 100 gm. above the usual final average normal weight for the colony in general, kept in an ordinary stock room with considerable fluctuation in room temperature.

The thiry-eight test rats averaged about 53 gm. in initial body weight at 3 weeks of age. They were held nearly constant during the period of 15 weeks, with a slight increase to an average of 56 gm. at 18 weeks of age. Upon full refeeding at this time, rapid growth ensued at a rate even above the normal at corresponding body weight, as is evident on comparing the curves in figure 1. During the first 2 weeks of refeeding, the test rats gained about 93 gm. in average weight, or nearly double the amount (55 gm.) previously gained by the controls during the corresponding period between 3 and 5 weeks of age. But this abnormally rapid rate of increase soon declines and the growth of the test rats lags correspondingly behind that of the controls. At 60 weeks of

age the final average for the thirty-eight test rats, 400 gm., although above the colony norm (on account of the favorable influence of the constant temperature room), is markedly below the average of 477 gm. for the forty-four controls. The difference of 77 gm., or about 16%, represents a dwarfing

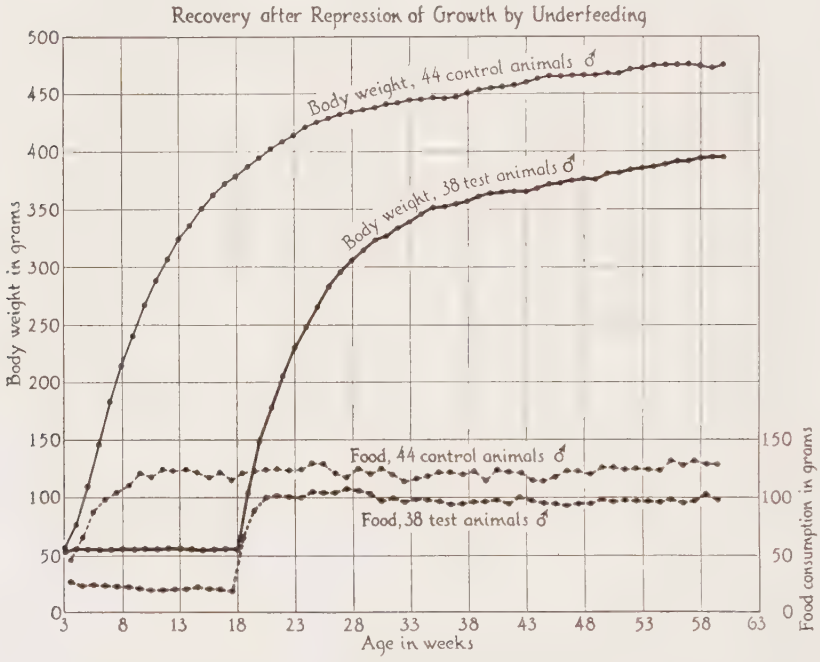

Fig. 1 Growth curves showing the average body weight of the control rats from 3 to 60 weeks of age; and of the test rats, held at nearly constant weight by underfeeding from 3 to 18 weeks of age, then fully refed up to 60 weeks of age. The corresponding curves for average weekly intake of food per rat in test and control animals are also represented.

of unquestionable statistical significance. There is some individual variability among the test rats, but very few of these reach the average weight of the controls. The coefficient of variability (table 1) was 13.0 in the test rats, which was but slightly higher than that of 11.5 in the controls.

Food intake

The corresponding food intake during the experiment is also shown in figure 1. The consumption of stock food for the controls increased rapidly from an initial average of about 44 gm. weekly per rat to about 120 gm. in 2 months, remaining nearly stationary thereafter.

For the test rats, the restricted food intake (including stock food and accessories) necessary to hold the body weight nearly constant decreased from an average of 27.72 gm. per rat during the first week to 19.17 gm. during the fifteenth week—a decrease of about 31%. This decreased consumption, which appears characteristic during maintenance of young animals at constant weight, is discussed more fully by Jackson ('37). Upon refeeding, as shown by the curve in figure 1, the (ad libitum) stock food intake of the test rats, increases very rapidly, corresponding to the gain in body weight. The food consumption increases within 3 weeks to about 100 gm. weekly per rat, after which it remains fairly constant. During the latter part of the experiment the difference in food intake between test rats and controls is fairly proportional to their difference in body weight.

Test of reproduction

At various times between the ages of 7 and 13 months, tests of reproductive capacity were made by placing each male rat at least once with a fertile female in estrus. Positive results were indicated by microscopic finding of spermatozoa in the vaginal plug. Of 43 controls thus tested, 30 individuals gave positive results, 13 negative. Of 35 test rats similarly tested, all except one gave positive results. Since inanition in general tends to depress the reproductive system, it is clear that the test rats had fully recovered from any previous injury to this system. That their reproductive performance actually surpassed that of the controls is not easily explainable. Possibly, as mentioned previously in discussing the infections found at autopsy, the test rats may represent a selected group

in which the weaker members have been eliminated. Howver, in the protein-deficiency experiment, no difference in reproductive capacity between test rats and controls was noted (Jackson, '36).

Organs and parts

Variability. As shown in table 1, the coefficients of variation for the various organs and parts in general do not differ appreciably in the test and control groups. In most of the parts the variation appears slightly less in the present data than was found for corresponding organs in the previous experiment with protein-deficiency, but in both cases most of the coefficients agree fairly well with the normal for the colony, found by Freudenberger ('33). The present experiment shows no evidence of any general increase in variability as a result of the earlier period of inanition.

Organ weights. Despite the significantly lower body weight in the test rats, no significant difference between test and control rats appears in the average weights of the brain, hypophysis, submaxillary glands, lungs, kidneys, stomach (both empty and with contents), intestines (empty), testes and epididymides (table 1). This means that in the test rats these organs are slightly larger than the normal for corresponding body weight, but the differences are not sufficient to produce any serious disproportion. For the nose-anus and tail lengths, and weights of skeleton, muscle and spinal cord (combined), humerus, femur, integument, eyeballs, thyroid, thymus, heart, liver, spleen, suprarenals and intestines with contents, the averages of the test group are in each case significantly below those of the controls. In general, however, these averages are not much different from the normal for the corresponding body weight.

DISCUSSION

No female rats were used in the present experiment, but it appears that in male rats the final depression in body weight is relatively greater following underfeeding than was found

in the previous study where growth was suppressed by protein deficiency. In the latter, the ultimate average weight of the male test rats (357 gm.) was only about 7% below that of the controls (383 gm.). In the present experiment the average for the test rats (400 gm.) remains about 16% below the controls (477 gm.). Even this may be considered as a relatively slight degree of dwarfing, in view of the severity of the earlier inanition. The most striking aspect of the result is perhaps the remarkable capacity for recuperation shown in the growth of the survivors, even though they do not finally reach the normal maximum weight.

An incidental finding in the present investigation is the notably greater body weights attained in both test rats and controls, in comparison with those found in the preceding study (Jackson, '36). The conditions for the male control rats were identical in both series, with the exception that in the earlier experiment the rats were kept in the ordinary colony room, whereas those of the present study were kept in the constant temperature room throughout the period from 3 to 60 weeks of age. This emphasizes the importance of environmental temperature as a factor in nutrition.

The present experiment with underfeeding, like the previous study with protein-deficiency, confirms the observation by Osborne and Mendel ('15) that reproductive capacity is not necessarily destroyed by prolonged inanition, and also their discovery ('16) that following a period of suppression growth may proceed at an exaggerated rate. I have now in progress a further investigation to determine more accurately the character of this excessive growth rate and the organs and parts concerned.

Earlier studies by myself and others (reviewed by Jackson, '25) have shown that the dystrophic growth changes during a prolonged underfeeding period result in abnormal proportions with marked changes in the various parts of the body. Under these conditions, some organs increase notably while others decrease, even during constant body weight. The present data indicate that when the malnourished survivors are amply refed

the disproportions become equalized and the various parts tend to assume their normal relative size within a few months. Even though the body may be dwarfed and fail to reach its normal maximum weight, the various organs will in general reach weights nearly normal for the corresponding body weights.

SUMMARY

On weaning at 3 weeks of age, young male rats were kept at nearly constant weight (about 54 gm.) by underfeeding for 15 weeks. A high mortality resulted.

The surviving test rats were fully refed and at first grew with abnormal rapidity. Soon the growth rate lagged, however, and the final average body weight remained about 16% below that of the normal controls. This dwarfing effect was more pronounced than that obtained in a previous experiment with growth repression through protein deficiency.

The food intake was measured and showed a characteristic decline in the test rats while maintained at constant weight. In the refed rats and controls the food consumption became somewhat proportional to the body weight, remaining nearly stationary during the latter part of the experiment.

Breeding tests showed even better reproductive performance in the surviving test rats than in the normal controls.

At final autopsy (60 weeks of age), despite the lower body weight, the test rats showed no significant difference from the controls in average weights of brain, hypophysis, submaxillary glands, lungs, kidneys, empty stomach and intestines, testes and epididymides. Body and tail lengths, and weights of the remaining organs were significantly lower in the test rats, but in general nearly normal for corresponding body weight.

The variability in body weight and length, and in the weights of the various organs and parts, was nearly the same in test rats and controls.

LITERATURE CITED

CLEMMENSEN, S. 1933 On arrest of growth and preserved capacity for growth in young rats suffering from partial B-deficiency. Acta Path. et Microbiol. Scand., vol. 10, pp. 315–328.

FREUDENBERGER, C. B. 1933 Variability in body length, body weight and organ weights of the rat. Anat. Rec., vol. 56, pp. 47–56.

GUASTALLA, R. AND L. RIGOLETTI 1935 Iponutrizione di lunga durata e rinutrizione di giovani ratti albini. Arch. per le Sc. Med., vol. 59, pp. 193–228.

JACKSON, C. M. 1925 The effects of inanition and malnutrition upon growth and structure. P. Blakiston's Son and Co., Philadelphia.

——— 1936 Recovery in rats upon refeeding after prolonged suppression of growth by dietary deficiency of protein. Am. J. Anat., vol. 58, pp. 179–193.

——— 1937 The food intake of young rats held at nearly constant body weight by restriction of the dietary protein. J. Nutrition, vol. 13, pp. 669–678.

JACKSON, C. M. AND C. A. STEWART 1920 The effects of inanition in the young upon the ultimate size of the body and of the various organs in the albino rat. J. Exp. Zool., vol. 30, pp. 97–128.

MCCAY, C. M., M. F. CROWELL AND L. A. MAYNARD 1935 The effect of retarded growth upon the length of life span and upon ultimate body size. J. Nutrition, vol. 10, pp. 63–79.

OSBORNE, T. B. AND L. B. MENDEL 1914 The suppression of growth and the capacity to grow. J. Biol. Chem., vol. 18, pp. 95–106.

——— 1915 The resumption of growth after long continued failure to grow. J. Biol. Chem., vol. 23, pp. 439–454.

——— 1916 Acceleration of growth after retardation. Am. J. Physiol., vol. 40, pp. 16–20.

A NOTE ON THE DEFINITION OF GLISSON'S CAPSULE

GEORGE C. WHITNEY

Department of Anatomy, The University of Rochester School of Medicine and Dentistry

In 1654 Francis Glisson published his 'Anatomia Hepatis.' As translated, he wrote of a portion of the connective tissue of the liver:

It first befell me (unless I am mistaken) to discover this part.

This part can, I say, by reason of its varying duty and function, be called by different names. For in so far as it encloses the portal vein and the bile duct in itself it is known correctly as their common capsule . . . . Since it is even more dense in that part of it which covers the biliary branches and seems at least seven times as wide; and since some part of it evidently intervenes between the portal vein and the bile duct (especially in the greater branches of these) and also since an important function of this (as will be mentioned later) is in transferring blood in some way as an auxiliary to the portal vein, it not unsuitably deserves to be called the sheath or the external tunic of the porta . . . .

I submit that this is derived from the tunic of the liver, arising from the peritoneum in this way: in truth it is joined to that better known extended sheath and more extended. But if, however, they (the anatomists) wish (while it is said to arise from the peritoneum) it to be also of similar substance to the peritoneum itself or necessarily to be derived from the same to such an extent as it could by no means be, or to exceed the peritoneum in the manner of its origin, we sensibly come to an opposite opinion. For it is a part more vascular and much more dense than the peritoneum; indeed you will hardly find elsewhere in the body as a whole another part of similar substance to it. It is less white than a vein, for it is suffused with a more purple color and is less transparent;

moreover, it approaches the strength of a vein, which it attains, and approximately the firmness of an artery in its strength.

Where first it receives the trunk of the portal vein it is united to the tunic of the liver (and this ultimately by way of the peritoneum as we have said) on all sides. For this capsule itself extends to the porta of the liver where the portal vein enters; and as soon as this vein enters the liver, it becomes covered with this capsule, which when it reaches the cavity of the former is necessary indeed and is united to the tunic of the liver there surrounding the place.

As soon as this capsule has surrounded the portal vein and the bile duct, it spreads out to the pattern of the portal vein and in turn divides together with that even to its farthest capillary, and attains the same distribution straight on through the whole liver: and what is more, a further description of it is not necessary; indeed what we have already said above concerning the ramifications of the portal vein may properly be applied to the capsule also.

This capsule, having accompanied the small branches of the portal vein, extends even to the gall bladder itself and invests all that part of it which is buried in a depression in the liver; and there in the space of this small depression is bound at the margins to the tunic of the liver . . . . and by the strength of this connection it is brought about that the gall bladder is strongly united to the liver.

To summarize the above account, the structure known today as Glisson's capsule, meets the portal vein and bile duct at their entrance into the liver, sheathing them and extending with them throughout the course of their branches. It is derived from the peritoneum and joined to it at the porta hepatis, but by its dense structure is distinct from the peritoneum. Extensions of the capsule from the parenchyma of the liver unite firmly with the capsule of the gall bladder and fix it in place.

Thomas Bartholin in 1677 repeated Glisson's description almost verbatim. Isbrand de Diemerbroek's 'Anatomy of Human Bodies,' first published in 1672, and translated by Salmon in 1689, identified the capsule with the external capsule of the liver. Von Hellwig carried matters a step farther in 1744, when he described Glisson's capsule as the sum total of the connective tissue of the liver.

Thus it is not surprising that in the textbooks of our century there should appear an almost unbelievable diversity of definition. Roughly dividing the modern authorities into general groups, it may be seen that there are in general three different usages of the term Glisson's capsule. These may be exemplified by the definitions from several of the current medical dictionaries.

The 'American Illustrated Medical Dictionary' (17th ed., '35) defines Glisson's capsule as "the sheath of connective tissue which envelopes the hepatic artery and duct and the portal vein." Here is in part a repetition of the original discoverer's report on the structure, a usage echoed by comparatively few of the authorities consulted. Jordan and Kindred ('26), the many editions of Gray, Poirier and Charpy, Koelliker ('02), Braus ('24), and Sharpey-Schafer ('20) are in essential agreement with this usage.

By Stedman's 'Practical Medical Dictionary' (11th ed., '30) the capsule is defined as a "thin layer of connective tissue surrounding the structures in the porta hepatis and forming a layer on the surface of the liver." This is, perhaps, the common usage of the day and has been termed the 'embryological' view since it is met with in the works of Arey ('34) and Bailey and Miller ('29). Neither of these texts, however, refers to the intra-hepatic extent of the capsule. A frequent variation from this usage is expressed by Waterston in Cunningham's textbook ('31), who describes the connective tissue of the liver parenchyma as being continuous with Glisson's capsule, which is a fibrous sheath beneath the liver capsule proper. Jackson in Morris's textbook ('33) and Ramón y Cajal ('33) agree essentially with this definition.

Böhm, Davidoff and Huber ('00) and Hill ('15) consider the capsule of Glisson as the tunic of the liver but add that it gives off supporting interlobular septa, while Schaffer ('33) considers that the term applies to the tunic only. Piersol (1895) in a more comprehensive definition states that the capsule comprises the tunic of the liver, the connective tissue covering the vessels throughout their extent, and the intrahepatic interlobular connective tissue.

The conception of the capsule as interlobular connective tissue alone is summarized in the definition of Glisson's capsule found in 'Gould's Medical Dictionary' (4th ed., '35): "The interlobular connective tissue of the liver, enveloping the portal vein, hepatic artery, and hepatic duct." Some agreement in part with this definition has been cited above. Jordan ('34) divides the connective tissue of the liver into two parts: the capsule of the organ and Glisson's capsule, which he says forms a framework throughout the liver, enclosing its lobules. With this definition Maximow and Bloom ('34) substantially agree.

However desirable the retention of eponymic titles may be, in times of increasing and improving knowledge their misuse may lead to confusion. Few more striking examples of this will be found than the confusing usage of the name of Glisson in association with the connective tissue of the liver. The need for revision and clarification is too obvious to need further expression.

LITERATURE CITED

AREY, LESLIE B. 1934 Developmental Anatomy, 3rd ed., W. B. Saunders C., Philadelphia.

BAILEY, F. R. AND A. M. MILLER 1929 Textbook of Embryology, 5th ed., Wm. Wood and Co., New York.

BARTHOLIN, THOMAS 1677 Anatome quartum renovata. London.

BÖHM, A., M. DAVIDOFF AND G. C. HUBER 1900 A Text Book of Histology. W. B. Saunders Co., Philadelphia.

BRAUS, HERMAN 1924 Anatomie des Menschen, Bd. II. Julius Springer, Berlin.

CUNNINGHAM, D. J. 1931 Textbook of Anatomy, 6th ed., Wm. Wood and Co., New York.

DE DIEMERBROECK, ISBRAND 1689 The Anatomy of Human Bodies. Translated by William Salmon, London.

GLISSON, FRANCIS 1654 Anatomia Hepatis. London.

GRAY, HENRY 1930 Anatomy of the Human Body. Edited by W. H. Lewis. Lea and Febiger, New York; also editions of 1878, 1883, 1887, 1896.

VON HELLWIG, CHRISTOPHE 1744 Nosce te ipsum. Frankfort and Leipzig.

HILL, C. 1915 A Manual of Normal Histology and Organography. W. B. Saunders Co., Philadelphia.

JORDAN, H. E. 1934 A Textbook of Histology, 7th ed., D. Appleton-Century Co., Inc., New York.

JORDAN, H. E. AND J. E. KINDRED 1926 A Textbook of Embryology. D. Appleton and Co., New York.

KOELLIKER, A. 1902 A. Koelliker's Handbuch der Gewebelehre des Menschen, Bd. III, Wilhelm Engelmann, Leipzig.

MAXIMOW, ALEXANDER A. AND WILLIAM BLOOM 1934 A Textbook of Histology, 2nd ed., W. B. Saunders Co., Philadelphia.

MORRIS, HENRY 1933 Human Anatomy, 9th ed., edited by C. M. Jackson, P. Blakiston's Son and Co., Philadelphia.

PIERSOL, G. A. 1895 Textbook of Normal Histology, 4th ed., J. B. Lippincott Co., Philadelphia.

POIRIER, P., AND A. CHARPY 1914 Traité d'Anatomie Humaine. Mason et Cie, Paris.

RAMÓN Y CAJAL, SANTIAGO 1933 Histology, tr. from 10th ed. by M. Fernán Nuñez, Wm. Wood and Co., Baltimore.

SCHAFFER, JOSEF 1933 Lehrbuch der Histologie und Histogenese, 3rd. ed., Wilhelm Engelmann, Leipzig.

SHARPEY-SCHAFER, SIR EDWARD 1920 The Essentials of Histology, 11th ed., Lea and Febiger, Philadelphia.

A CASE OF RETROCAVAL URETER

JAMES C. WREN
Department of Anatomy, University of North Carolina

Retrocaval ureter is a rare anomaly in man if one can judge from the number of cases reported in the literature. Dial ('36) records two cases and makes reference to twelve others, all that he had been able to find reported. A case encountered here in the course of routine dissection in the laboratory of gross anatomy brings the number to fifteen.

The cadaver in which the condition occurred was an adult male. The right kidney was in its normal position, and the renal pelvis was of usual size and appearance. Aside from its course, the ureter presented no abnormalities. This is in contrast to some of the preveiously reported cases in which definite dilatation in the region of the renal pelvis and constriction in the postcaval portion were observed. In the present case, the renal artery and vein were normally placed, and there were no aberrant vessels in the area other than the vena cava, the anomalous development of which accounts for the retrocaval position of the ureter.

The course and relations of the ureter were briefly as follows: From the renal pelvis, the ureter passed downward and medialward to the lateral border of the inferior vena cava. After passing posterior to the vessel, it emerged between the aorta and inferior vena cava at the level of the fourth lumbar vertebra. The ureter coursed for a short distance between the great vessels lying in the interval between the psoas major muscle and the vertebral column. In this region, the inferior vena cava was separated from the aorta by about 2 cm. At the level of the fifth lumbar vertebra, the ureter turned lateralward to pass anterior to the vena

cava. It then turned downward to cross the common iliac vessels at a point nearer the midline than is the usual case.

Retrocaval ureter is not properly an anomaly of the ureter but of the venous system resulting apparently from an abnormal persistence in the developing vena cava of portions of channels that are part of the earlier fetal venous plexus but that normally disappear before the definitive condition is reached. The embryology of the inferior vena cava is quite complex, and a brief account of its ontogeny will afford a probable explanation of such a condition.

According to Butler ('27), the inferior vena cava is composed of four embryonic segments, namely: 1) A hepatic portion from the common hepatic vein, the liver sinusoids, and an indepedent vein in the caval mesentery, 2) a subcardinal segment from a portion of the right subcardinal vein, 3) a renal portion from an anastomosis between the right subcardinal and the right supracardinal veins, and 4) a supracardinal segment from the lumbar portion of the right supracardinal vein. Butler's paper and the papers by McClure and Butler ('25), McClure and Huntington ('29), and Reagan ('29) may be consulted for more complete information concerning the development of the inferior vena cava.

On the basis of the relation of the ureter to the components entering into the formation of the inferior vena cava, the reported cases of retrovocal ureter may be classified into four types (Rotter, '35; Dial, '36). Some abnormal persistence of the posterior cardinal vein is involved in each type. The case that has occurred most frequently is due to unilateral persistence of the posterior cardinal vein on the right side forming the postrenal portion of the adult inferior vena cava. The present case belongs to this category as do nine of those previously reported (Hochstetter, Kolisko, Gladstone, Kenkyel, Skamnakis, Jacobson, two cases, and Dial, two cases). Bilateral persistence of the posterior cardinal vein with a bilateral retrocaval ureter constitutes another type (Gladstone). Three cases of a third type in which the ureter

passes through a ring formed by a unilateral persisting posterior cardinal vein and the postrenal portion of the right supracardinal have been reported (Wicke, von Gierke, and Rotter). Finally, a fourth type resulting from a unilateral persistence of the right posterior cardinal and the left supracardinal veins has been described. The picture in this type is one of a double vena cava, one on each side, with the ureter passing posterior to the right vein (Rotter).

LITERATURE CITED

BUTLER, E. G. 1927 The relative role played by the embryonic veins in the development of the mammalian vena cava posterior. Am. J. Anat., vol. 39, pp. 267–353.

DIAL, W. A. 1936 Retrocaval ureter and right aorta. Anat. Rec., vol. 65, pp. 239–245.

GLADSTONE, R. J. 1905 Acardiac fetus (acephalus omphlositicus). J. Anat. and Physiol., vol. 11, p. 71.

——— 1911 A case in which the right ureter passed behind the abdominal aorta, and the bearing of these abnormalities on the development of the abnormal veins. J. Anat. and Physiol., vol. 45, pp. 225–231.

——— 1929 Development of the inferior vena cava in the light of recent research, with especial reference to certain abnormalities, and current descriptions of the ascending lumbar and azygos veins. J. Anat., vol. 64, pp. 70–93.

HOCHSTETTER, FERDINAND 1893 a Beiträge zur Entwicklung des Venesystems der Amnioten. 3 Säuger. Morph. Jahrbuch., Bd. 4, S. 543–648.

——— 1893 b Entwicklung des Venesystems der Wirbeltiere. Ergeb. d. Anat. u. Entwgschte., Bd. 3, S. 460–489.

JACOBSON, V. C. 1927 Postcaval ureter: 2 cases in man. Arch. Path. and Lab. Med., vol. 3, pp. 203–211.

KENGYEL, H. 1928 Über eine eigenartige Ursache der Hydronephrose (Ungewöhnlicher Verlauf der Hinteren Hohlvene). Ztschr. f. Urol. Chir., Bd. 25, S. 417–423.

KOLISKO, FRITZ 1909 Ein Fall abnormen Verlaufes des rechten Ureters. Anat. Anz., Bd. 34, S. 520–524.

MCCLURE, C. F. W. AND E. G. BUTLER 1929 The development of the inferior vena cava in man. Am. J. Anat., vol. 35, pp. 331–383

MCCLURE, C. F. W. AND G. S. HUNTINGTON 1929 Mammalian vena cava posterior; ontogenetic interpretation of atypical forms of vena cava posterior (inferior) found in the adult domestic cat (Felis domestica) and in man. Am. Anat. Mem., no. 15, 55 pp. The Wistar Institute, Philadelphia.

Reagan, F. P. 1929 Century of study upon the development of eutherian vena cava inferior. Quart. Rev. Biol., vol. 4, pp. 179–212.

Rotter, Hans 1935 Dorsaler Ureterverlauf bei Abnormitäten der unteren Hohlvene. Ztschr. f. Anat. u. Entwgschte., Bd. 104, S. 456–474.

Skamnakis, S. N. 1931 Eine Anomalie der Vena cava inf. und abnormer Verlauf des rechten Ureters. Anat. Anz., Bd. 73, S. 50–56.

von Gierke, E. 1928 Abnormer Verlauf des rechten Ureters bei Entwicklung anomalie der unteren Hohlvene. Ztschr. f. Urol. Chir., Bd. 25, S. 279–285.

Wicke, Adolph 1927 Über einen Fall Inselbung im Bereiche der hinteren Hohlvene (Vena cava posterior) und Durchtritt des rechten Harnleiters beim Erwachsen. Ztschr. f. Anat. u. Entwgschte., Bd. 84, S. 524.

NEW BOOKS AND PUBLICATIONS

SURGICAL ANATOMY, by Grant Massie. Third edition. 1937. Pages x + 468. 153 illustrations, some of them in color. Size, 6 × 9½ inches. Index. Cloth. Price, $6.50. Lea and Febiger, Philadelphia.

Anatomical and clinical information neatly combined in this book make it invaluable both to the senior medical student and to the practising surgeon. Diagnostic and operative procedures are explained along with brief anatomical descriptions of each region of the body. By judicious additions and alterations this edition has been brought up-to-date while retaining the good features of former editions. The ever present problem of nomenclature has been met by printing in brackets the BNA terms and using in the text such terms descriptive of positions as are obviously better than their old equivalents. The illustrations are well selected and reproduced. The regional divisions are head and neck, upper limb, abdomen and pelvis, lower limb, thorax and the vertebral column.

SHORT-WAVE DIATHERMY, by Tibor de Cholnoky. 1937. Size, 6¼ × 9½ inches. Pages xiii + 310. 38 illustrations. Index. Bibliography. Cloth. Price, $4.00. Columbia University Press, New York.

Short waves are the most significant contribution of recent times to the application of electricity in medical treatment. The therapeutic value in some pathological conditions cannot be questioned although some of the extravagant claims advanced by manufacturers of short wave apparatus have yet to be demonstrated. This book is timely since it offers the first complete survey in English of work done in this field. The introduction outlines briefly the history of short wave diathermy from the first studies of Maxwell in 1865 to date. This is followed by a discussion of physical aspects: principles of construction of short wave machines; spark gap and tube machines; measurements. Experimentation on animals, bacteria and other organisms revealed the general and mechanical principals in short wave technique which are applied in treatment of numerous diseases of man.

DIGEST OF TREATMENT, vol. 1, no. 1, July, 1937. Editor, William E. Kirsch. General editorial advisor, George E. Rehberger. Editorial staff, W. Osler Abbott, Kendall A. Elsom, L. Kraeer Ferguson, Samuel B. Hadden, Frank O. Hendrickson, Boland Hughes, Louis B. Laplace, Clifford B. Lull, Donald M. Pillsbury, John P. Scott. Published monthly. Size, 5½ × 7½ inches. 80 pages. 40 articles. Subscription price, $5.00; Canada, $5.50; Foreign, $6.00. J. B. Lippincott Company, Philadelphia.

The purpose and nature of this new magazine are described as follows: Our purpose in presenting a monthly periodical 'Digest of Treatment,' free from any suggestion of advertising bias, is threefold: first, to bring to the practitioner, in brief form, the newer developments in the technic of treatment; second, to stimulate an interest in the worthwhile current medical literature today; and third, to bring to those physicians who have become defined as specialists, a well-rounded viewpoint regarding branches of medicine other than their own. Each month, medical editors, every one a clinical practitioner, carefully select, from over 200 journals, materials to be condensed. In their selections they choose both the favorable and unfavorable reports, realizing that the physician is keenly interested in the unbiased evaluation of the therapy he contemplates trying. The digests and condensations, selected and made by men of clinical experience, fill a need expressed by physicians many times.

THE FUNCTIONAL DIFFERENTIATION OF THE HEPATIC CELLS OF THE CHICK EMBRYO

A. J. DALTON

Laboratory of Histology and Embryology, Western Reserve University School of Medicine

ONE TEXT FIGURE AND TWO PLATES (FIVE FIGURES)

INTRODUCTION

In an examination of livers from a series of chick embryos, Potvin and Aron ('27) found no evidence of glycogen previous to the twelfth day of incubation. Their further finding that the definitive islets of Langerhans are first evident in the pancreas of 10-day embryos appeared to support the previously expressed opinion of Aron ('22) that the origin of the glycogenic function of the liver was associated with the appearance of insulin in the blood stream. On the other hand, Nordmann ('29) found that liver cells removed from 9-day embryos and isolated in tissue culture acquire the capacity to synthesize and store glycogen and that blood plasma is not essential to this activity.

Since the hepatic cells of the 9-day chick embryo, isolated in tissue culture, are capable of glycogen synthesis and storage, the lack of glycogen in normal hepatic cells previous to the twelfth day of incubation is rather puzzling. It was decided, in the present study, to repeat the work of Potvin and Aron, using a different method for the identification of glycogen. In addition, an attempt has been made to determine the time when glycogen first appears in hepatic cells grown on the chorio-allantois. It seemed possible that the results of such an experiment might give some evidence as to the effect of the constituents of the blood stream of the host on the functional differentiation of the hepatic cell.

THE ANATOMICAL RECORD, VOL. 68, NO. 4
JULY, 1937

MATERIAL AND METHODS

All of the embryos used in this investigation were of the Single Comb White Leghorn variety. The method used to identify glycogen has, with but three exceptions, been the same throughout. Normal and graft livers were fixed in an excess of absolute alcohol, embedded in celloidin, sectioned at 12 μ, and stained for glycogen by Best's carmine method. The staining and differentiation times were carefully controlled. Preliminary trials were made with the alternative paraffin-1% celloidin method (Lee, '28) followed by Best's carmine stain. This latter technique was found to be rather unsatisfactory because the liver cells were badly distorted and shrunken and it was suspected that in many instances some of the glycogen was lost from the sections. Three grafts which were examined by means of this technique showed the presence of glycogen and have been included in the results.

To test the reliability and constancy of the method, the stain was checked from time to time during the investigation against tissue known to contain glycogen (embryonic cardiac muscle), and against tissue known to contain little or no glycogen (tubules of the mesonephros of a 10-day embryo). In addition, the stain was tested on control sections of the same material with the action of diastase of saliva. As a further check, the right and left lobes of many of the normal livers were fixed separately, embedded in different blocks, and stained separately. In each case the two lobes appeared to contain identical amounts of glycogen.

OBSERVATIONS

All of the tests made of the reliability of the technique used for the identification of glycogen gave such clear-cut results that I have complete confidence in the method. It is accurate enough to allow roughly quantitative comparisons to be made.

In the normal series, the amount of glycogen was found to vary considerably, both in livers of the same and of different ages of incubation. An attempt to indicate this has been made

in table 1. With the exception of the sixth day, livers in sections of which but one or two cells contained glycogen have been grouped with those which were entirely negative.

TABLE 1

Glycogen in livers of chick embryos

AGE OF EMBRYO IN DAYS	NUMBER OF LIVERS STUDIED	AMOUNT OF GLYCOGEN PRESENT	DISTRIBUTION OF GLYCOGEN
6	1	Traces	In a few cells
7	5	5 + —	In cells near certain[1] large veins
8	10	10 +	In cells near certain large veins
9	22	17 +	Most in cells near certain large veins
		3 + —	In cells near certain large veins
		2 —	
10	24	15 +	Most in cells near certain large veins
		2 + —	In cells near certain large veins
		7 —	
11	20	10 +	Most in cells near certain large veins
		3 + —	In cells near certain large veins
		7 —	
12	22	2 +	Throughout liver
		5 + —	Most in cells near certain large veins
		15 —	
13	20	7 +	Throughout liver
		7 + —	Throughout liver
		6 —	
14	6	4 +	Throughout liver
		2 + —	Throughout liver
15	6	5 +	Throughout liver
		1 + —	Throughout liver
16	6	4 +	Throughout liver
		2 + —	Throughout liver
17	6	6 +	Throughout liver
18	6	6 +	Throughout liver

[1] All vessels were not surrounded by this concentration of glycogen and it was not found possible to distinguish between hepatic portal and hepatic veins.

As the table indicates, glycogen may be identified in the hepatic cells of the chick embryo as early as the sixth day of incubation. At this time, however, it is present only in traces, i.e., in not more than one or two cells of a single section. Although there is a wide variation in the amount of glycogen

present in hepatic cells of livers of the same age of incubation, a trend toward a gradual increase is evident from the sixth to the ninth day. From the ninth to the thirteenth day, a decrease in glycogen content occurs. Graph A, figure 1, shows this decrease expressed in terms of the percentage of the livers containing glycogen.

By the end of the seventh day, many of the cells surrounding certain of the large veins contain glycogen. This is the

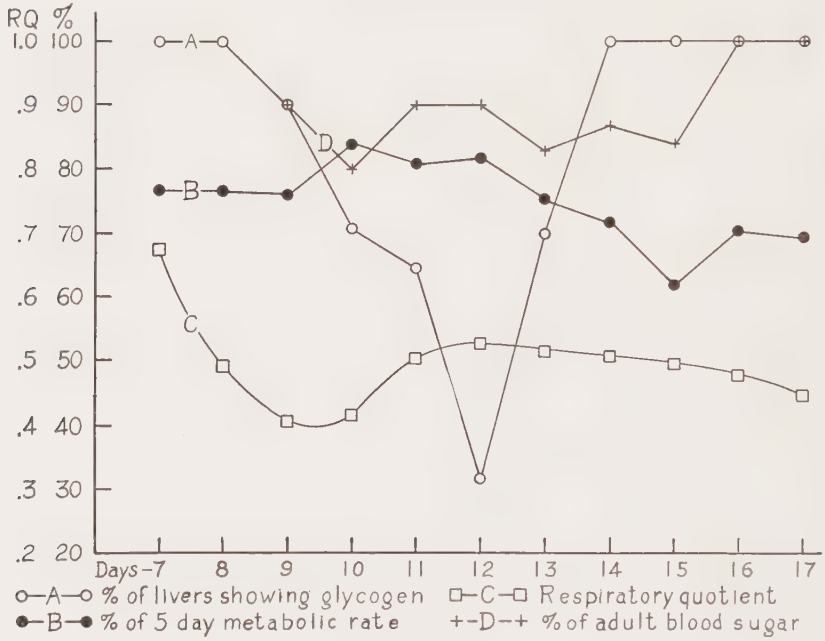

Figure 1

characteristic distribution in livers from embryos of less than 12 days incubation (fig. 2, a and b). After this time, the glycogen present appears to be more evenly distributed throughout the liver (fig. 3).

In many cases, glycogen with a homogeneous, rather than with a granular appearance may be found. This homogeneity seems to be more characteristic of the glycogen in cells of younger than of older livers (compare figs. 3 and 4).

Table 2 shows the results obtained from a study of the grafts of hepatic tissue which were examined for their glycogen content. It will be noted that all of the grafts with a control age of 8 days or less contain no glycogen, while those of more than 8 days contain amounts which, in general, are proportional to the total age of the graft. A careful study of the series indicates that the small variations in glycogen content found to exist between grafts of the same

TABLE 2

Glycogen in grafts of hepatic cells

GRAFT NO.	TOTAL GRAFT AGE IN DAYS	HOST AGE IN DAYS	DAYS OF GRAFT ON MEMBRANE	GLYCOGEN	PARAFFIN OR CELLOIDIN
B-79	6	17	4	None	C
B-94	6	17	4	None	C
B-81	7	17	4	None	C
B-82	7	17	4	None	C
B-91	7	17	4	None	C
B-97	8	18	5	None	C
B-98	$8\frac{1}{3}$	18	5	Marginal tubules (—), central tubules (+)	C
B-64	$8\frac{1}{2}$	17	5	Marginal tubules (—), central tubules (+)	P
B-84	$8\frac{3}{4}$	17	6	Traces in most cells	P
B-56	9	17	6	Present in most cells	C
B-57	$9\frac{1}{3}$	17	6	Present in most cells	P
B-73	$9\frac{3}{4}$	17	7	Present in large amounts	C
B-74	$9\frac{3}{4}$	17	7	Present in large amounts	C
B-75	$9\frac{3}{4}$	17	7	Present in fairly large amounts	C
B-68	$10\frac{3}{4}$	17	7	Present in fairly large amounts	C
B-70	$10\frac{3}{4}$	17	7	Present in large amounts	C

age are due to differences in vascularity and health of the grafts. Figure 5 (a and b) taken from a section of graft B-98, the youngest graft in which glycogen has been identified, shows the small amount present. Figure 6 (a and b) taken from a section of graft B-73 shows the usual amount present in older grafts. Figures 5 and 6 show the characteristic nature of the glycogen in grafts of hepatic tissue. The large, homogeneous masses seen in normal hepatic tissue of approximately the same control age are not seen in grafts.

DISCUSSION

Potvin and Aron ('27) suggested the twelfth day of incubation as the time when glycogen first appears in the hepatic cells of the developing chick. From this time on, they have found it to be regularly present. As has been indicated above, I have found traces of glycogen in the liver of a chick embryo of 6 days incubation. From this time, up to the ninth day, there is evidence of a gradual increase in the glycogen content of the hepatic cells. This increase is followed by a decrease centering about the twelfth day. Although complicated by a wide variation in the amount of glycogen present in livers of the same age, these changes appear to be of considerable significance. Somewhat similar results were found by Aron ('22) in pig and sheep embryos in which he found glycogen in some instances before the appearance of the pancreatic islets.

The failure of Potvin and Aron ('27) to find glycogen in livers from chick embryos of less than 12 days incubation is difficult to understand and is not in accord with the earlier findings of Aron mentioned above. The storage of glycogen in the chick liver previous to the appearance of insulin in the blood stream makes it necessary to reconsider the conclusion of Aron that glycogen synthesis and storage is dependent upon the appearance of insulin.

Although glycogen is unquestionably present as early as the end of the sixth day of incubation, the reason for such great individual variations in the glycogen content of livers of the same age, between the ninth and thirteenth days, is rather obscure. The careful use of celloidin as an embedding medium followed by Best's carmine stain would appear to eliminate the possibility of any great variation in glycogen content resulting from faulty technique. The rather wide differences in physiological age occurring in a group of embryos incubated for the same length of time may explain the variation in part; but the usual divergence of physiological age from incubation age in chick embryos is that represented by an incubation period of about 14 hours. Since it is during a

period of 96 hours in which the great variation in glycogen content occurs, it does not seem possible that the differences in physiological age could be the sole explanation. These variations appear to be more closely associated with the decrease in glycogen content occurring during the same period and centering about the twelfth day.

Referring to graphs A and B, figure 1, one may note that during the period when glycogen is rapidly disappearing from the liver, the metabolic rate shows a distinct rise. Graph B has been expressed in terms of the percentage of the metabolic rate of the 5-day embryo and was determined from the heat measurements of Bohr and Hasselbalch ('03) and the wet weight measurements of Murray ('25). Further, the respiratory quotient (graph C, fig. 1) determined from the CO_2 and O_2 data of Murray ('26 and '27) definitely approaches unity during this period,[1] indicating an increased oxidation of carbohydrate. In addition, the decrease in liver glycogen causes no detectable change in the blood sugar concentration (graph D, fig. 1, data from Zorn and Dalton, '37). All of the evidence—rapid glycolysis, increased metabolic rate, the

[1] Needham ('31) considers in detail only the respiratory quotients given by Bohr and Hasselbalch ('03), Hasselbalch ('00), and those calculated by Needham ('26) from other CO_2 and O_2 data of Bohr and Hasselbalch. Needham finds support in these figures for the hypothesis that carbohydrate, protein, and fat succeed one another as energy sources during the development of the chick since the majority of the high values occur previous to the sixth day of incubation. Fiske and Boyden ('26) have pointed out that since the end product of protein metabolism in birds is uric acid, the respiratory quotient for protein should be 0.71 rather than 0.80 as it is in mammals. During the last 2 weeks of incubation, when it may be safely assumed that considerable amounts of fat are being utilized, respiratory quotients above 0.70 would indicate the utilization of significant amounts of carbohydrate as well. If the incubation period be divided into three parts and for each part we find the percentage of the number of respiratory quotients determined from the experiments of Bohr and Hasselbalch which are above the value of 0.70, we find 60% for the period from the first to the fifth day, 15% from the sixth to the ninth day, 50% from the tenth to the thirteenth day, and 31% from the fourteenth to the twentieth day. Considered in this manner, the results of Bohr and Hasselbalch, although of generally lower values than those of Murray, indicate that carbohydrate, used almost exclusively as the energy source from the first to the fifth day, is also used in relatively large amounts from the tenth to the thirteenth day of incubation.

rise in the respiratory quotient, and the absence of any detectable increase in the blood sugar concentration—suggests that a distinct, relative increase in the utilization of carbohydrate as an energy source occurs during the period from the tenth to the thirteenth day of incubation. The evidence also indicates that the liver is the source of at least a part of this carbohydrate. The fact that the adrenal medulla (Lutz and Case, '25), the pancreatic islets (Potvin and Aron, '27), and the thyroid (Willier, '24) all become active during this period is of interest. Evidence that insulin hypoglycemia may be experimentally induced in the embryo (Hanan, '25) and that a transient rise in the metabolic rate may result from the injection of thyroxin (Hanan, '28) are suggestive of what may happen when these hormones first make their appearance in the embryonic blood stream.

When glycogen is present in livers from embryos of 7 to 11 days incubation, its greatest concentration is found in cells adjacent to certain large veins. Later, it acquires a more even distribution throughout the liver. This change to a more even distribution similar to that of the adult (Kater, '33), coincides approximately with the time when insulin first appears in the blood stream (Pucher and Hanan, '29) and may possibly be associated with its appearance.

The homogeneous character of glycogen in liver cells of young embryos has been noted by Nordmann ('29) and Doljanski ('31) in tissue culture. They attributed their results to the fact that they used iodine vapor to identify glycogen in fresh tissues and considered the usual granular nature of glycogen as seen in sectioned material to be an alcohol fixation-artefact. It is evident from the results reported above that glycogen in livers of young embryos retains its homogeneous nature after alcohol fixation, yet glycogen in grafts of approximately the same total age appears as small, granular particles. The granular appearance of glycogen after alcohol fixation may be associated with the presence of large amounts of other stored substances in older livers and in grafts.

Glycogen is first identifiable in a graft with a total age of $8\frac{1}{3}$ days. Why glycogen should appear earlier in normal development than it does in grafts of hepatic tissue seems difficult to explain, but both Nordmann ('29) and Doljanski ('31) found a lag of 24 hours before glycogen appeared in hepatic cells isolated in tissue culture. It is possible that this lag is evidence of an inhibition resulting from the removal of the hepatic cells from their natural environment. The act of transplantation to tissue culture or to the chorio-allantois appears to cause a temporary but almost complete halt in the processes concerned with functional differentiation. It is conceivable then, that the functional differentiation of hepatic cells in grafts may be retarded to such an extent that their physiological age would be considerably less than that of hepatic cells of a normal liver incubated for the same length of time. Further, this retardation might conceivably vary within certain limits for any one of several reasons, such as differences in the age of the donor at the time of transplantation, the length of time required for transplantation, etc. Thus, when the effect of transplantation is taken into consideration, it appears that the exposure of hepatic cells in grafts to the action of insulin for 4 days neither delays nor accelerates functional differentiation to any appreciable extent.

All grafts with a total age of more than 8 days contain glycogen in varying amounts. The wide variation in glycogen content of livers from embryos of the same age, however, does not occur in grafts of livers of comparable ages. The small variation found appears to be definitely related to the vascularity and health of the graft. This might be expected when it is borne in mind that all grafts were removed from 17- and 18-day hosts. Livers of embryos of these ages contain considerable amounts of glycogen and, in addition, the adult level of blood sugar concentration has been reached by this time (graph A, fig. 1).

Certain observations, other than those of Potvin and Aron ('27), appear to indicate that the eleventh day of development

is of great significance in the process of functional differentiation of the hepatic cell of the chick. Heaton ('26) noted a striking change in the growth characteristics of hepatic cells removed from embryos of more than 11 days incubation, and grown in tissue culture. Sandstrom ('34) has shown that hepatic tissue degenerates rapidly in chorio-allantoic grafts after a total age of 12 days is reached. Further, I have presented evidence pointing to the eleventh day as the time when cholesterol storage first occurs in normal development (Dalton, '34, '37). These observations, although of interest in themselves, do not of necessity indicate that a significant change has occurred in the hepatic cell at this time. The results of Heaton are considered to be due to a secondary change induced by the action of some substance, possibly insulin, on an already functional cell. It has previously been suggested (Dalton, '37) that the degenerative changes noted by Sandstrom may have been due to bile stasis occurring in the liver grafts. And finally, it seems more than a coincidence that cholesterol is first identifiable in the liver on the same day that the concentration of blood cholesterol first approximates adult values (Zorn and Dalton, '37).

The following observations concerning the functional differentiation of the hepatic cell of the chick are considered to be significant. First, cholesterol, not evident in normal livers before the eleventh day, appears in grafts during the latter part of the seventh day of incubation (Dalton, '37). Second, glycogen first becomes noticeable in appreciable amounts in normal hepatic cells by the seventh day of incubation. Third, glycogen appears in tissue cultures of hepatic cells from 9-day embryos (Nordmann, '29; and Doljanski, '31) and first appears in chorio-allantoic grafts when the grafts reach a total age of a little more than 8 days. Correction for the lag in development induced by transplantation suggests the seventh day as the time when the glycogenic function is established. Fourth, the curves for secretion of uric acid (Fiske and Boyden, '26; and Needham, '26) and for the concentration of uric acid in the blood (Zorn and Dalton,

'37) all suggest the presence of an actively functioning liver in 9-day embryos. The exact time when the liver assumes its function with regard to protein metabolism cannot be stated although the data of Fiske and Boyden, and Needham on uric acid excretion appear to suggest the seventh day of incubation as the time when this function becomes established. Fifth, Sandstrom ('34) states that bile secretion is first evident in 6-day embryos. Sixth, in the cytogenesis of the hepatic cell of the chick, the most obvious change occurs during the sixth and seventh days of incubation when the Golgi substance begins to expand and to move nearer the distal pole of the cell (Dalton, '34). The bulk of this evidence obviously points to the latter part of the seventh day of incubation as the time when many of the hepatic cells of the chick embryo become capable of active, mature function.

SUMMARY

1. Glycogen first becomes evident in hepatic cells of 7-day embryos.

2. The appearance of glycogen in the hepatic cell occurs previous to and is not dependent upon the presence of insulin in the blood stream.

3. It is suggested that the variation in the amount of glycogen in livers from embryos of the same incubation age is possibly associated with differences in physiological age and with the presence or absence of adrenin, insulin and thyroxin.

4. Evidence has been presented which suggests that a marked relative increase in the utilization of carbohydrate as an energy source occurs during the period from the tenth to the thirteenth day of incubation.

5. Evidence of glycogen synthesis and storage has not been found in grafts younger than 8⅓ days. This is possibly due to the inhibitory effect of transplantation.

6. Exposure of the hepatic cell to the influence of insulin for 4 days does not appear to accelerate the establishment of its glycogenic function.

7. Several lines of evidence point to the seventh day of incubation as the time when many of the hepatic cells of the chick embryo have become capable of active, mature function.

LITERATURE CITED

Aron, M. 1922 L'évolution morphologique et fonctionnelle des îlots endocrines du pancréas embryonnaire. Arch. d'Anat., d'Histol., et d'Embryol., T. 1, pp. 69–113.

Bohr, C. and K. A. Hasselbalch 1903 Ueber die Wärmeproduction und den Stoffwechsel des Embryos. Skand. Arch. f. Physiol., Bd. 14, S. 398–429.

Dalton, A. J. 1934 The ontogenetic history of the mitochondria and Golgi network of the hepatic cell of the chick. Anat. Rec., vol. 58, pp. 321–347.

——— 1937 Cholesterol storage and bile secretion in chorio-allantoic grafts of liver. Anat. Rec., vol. 67, pp. 431–439.

Doljanski, L. 1931 Sur les cultures pures du foie. Arch. f. exp. Zellf., Bd. 11, S. 261–271.

Fiske, C. H. and E. A. Boyden 1926 Nitrogen metabolism of the chick embryo. J. Biol. Chem., vol. 70, pp. 535–556.

Hanan, E. B. 1925 Experimental hypoglycemia and hyperglycemia in the chick embryo. Proc. Soc. Exp. Biol. and Med., vol. 22, pp. 501–504.

——— 1928 Effect of thyroxin on growth rate and carbon dioxide production of chick embryo. Proc. Soc. Exp. Biol. and Med., vol. 25, pp. 422–425.

Heaton, T. B. 1926 The nutritive requirements of growing cells. J. Path. and Bact., vol. 29, pp. 293–306.

Kater, J. MacA. 1933 Comparative and experimental studies on the cytology of the liver. Zeit. f. Zellf. u. mikr. Anat., Bd. 17, S. 217–246.

Lee, B. 1928 The Microtomist's Vade-Mecum. P. Blakiston's Son and Co.

Lutz, B. R. and M. A. Case 1925 The beginning of adrenal function in the embryo chick. Am. J. Physiol., vol. 73, pp. 670–678.

Murray, H. A., Jr. 1925 Physiological ontogeny. III. Weight and growth rate as functions of age. J. Gen. Physiol., vol. 9, pp. 39–48.

——— 1926 VIII. Accelerations of integration and differentiation during the embryonic period. J. Gen. Physiol., vol. 9, pp. 603–620.

——— 1927 XII. The metabolism as a function of age. J. Gen. Physiol., vol. 10, pp. 337–343.

Needham, J. 1926 The energy-sources in ontogenesis. II. The uric acid content and the general protein metabolism of the developing avian egg. Brit. J. Exp. Biol., vol. 4, pp. 114–144.

——— 1931 Chemical Embryology. Cambridge University Press.

Nordmann, M. 1929 Wachstum und Stoffwechsel der Leberzellen in der Gewebskultur. Arch. f. exp. Zellf., Bd. 8, S. 371–414.

Potvin, R. and M. Aron 1927 Recherches sur l'evolution embryonnaire des îlots pancréatiques endocrines chez le poulet. C. R. Soc. Biol., T. 96, pp. 267–269.

PUCHER, G. U. AND E. B. HANAN 1929 (Private communication to Needham.) Chemical Embryology. 1931.

SANDSTROM, R. H. 1934 The differentiation of hepatic and pancreatic tissues of the chick embryo in chorio-allantoic grafts. Physiol. Zool., vol. 7, pp. 226–246.

WILLIER, B. H. 1924 The endocrine glands and the development of the chick. I. The effects of thyroid grafts. Am. J. Anat., vol. 33, pp. 67–103.

ZORN, C. AND A. J. DALTON 1937 A chemical study of the blood of the developing chick. Am. J. Physiol., vol. 119, pp. 627–634.

DESCRIPTION OF PLATES

All figures are photomicrographs of material fixed in absolute alcohol, embedded in celloidin, sectioned at 12 μ, and stained by Best's carmine method.

PLATE 1

EXPLANATION OF FIGURES

2a Photograph of a region near a large blood vessel in the liver of an 11-day embryo. Glycogen particles appear homogeneous, larger, and more numerous near the blood vessel. $\times$ 440.

2b The same photograph as figure 2a, but with the distribution of the glycogen particles indicated more clearly by means of India ink. $\times$ 440.

3 Photograph of a region similar to that shown in figure 2, but taken from a 17-day embryo. The glycogen in this case has a much more even distribution. $\times$ 440.

4 Photograph of a section of liver from an 8-day embryo showing the large, rather homogeneous masses of glycogen frequently found in young embryos. $\times$ 800.

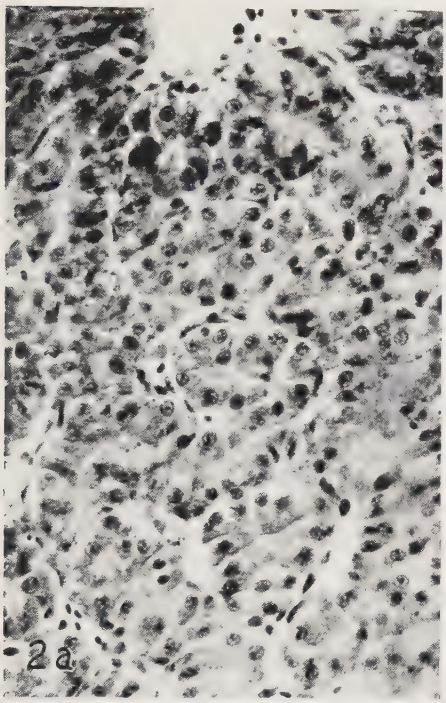
2a

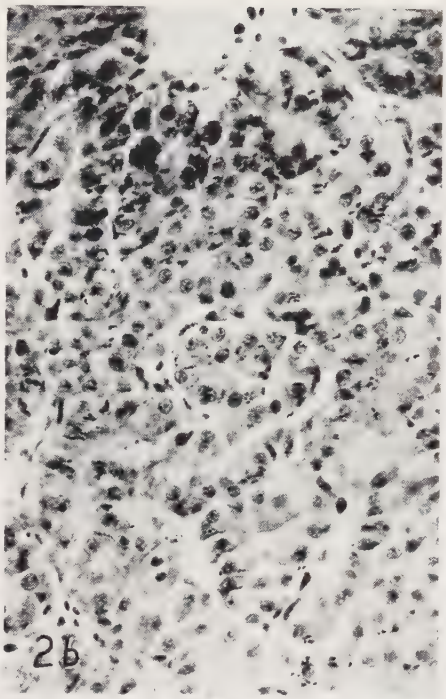
2b

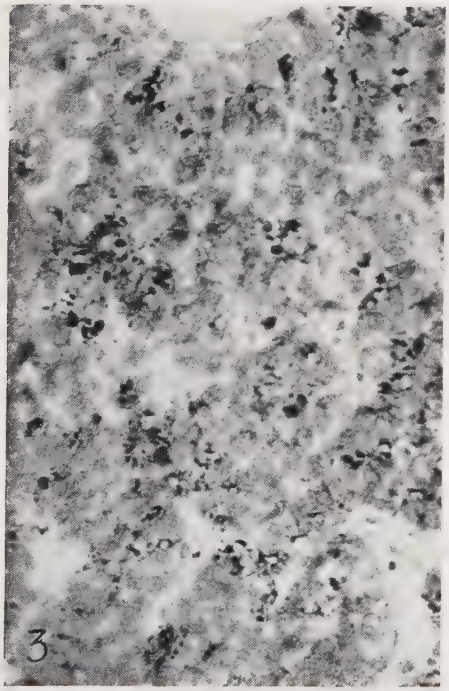
3

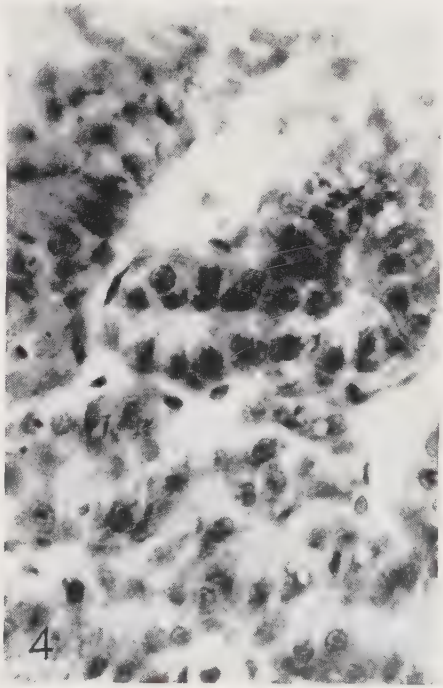
4

PLATE 2

EXPLANATION OF FIGURES

5a Photograph of a section of graft number B-98, total age $8\frac{1}{3}$ days, removed from an 18-day host. Small amounts of glycogen are present. $\times$ 1000.

5b The same photograph as figure 5a, but with the glycogen particles indicated more clearly by means of India ink. Note the granular character of the glycogen. $\times$ 1000.

6a Photograph of a section of graft number B-73, total age $9\frac{3}{4}$ days, removed from a 17-day host. Glycogen present in relatively large amounts. $\times$ 730.

6b The same photograph as figure 6a, but with the glycogen particles indicated more clearly by means of India ink. Note again the granular character of the glycogen. $\times$ 730.

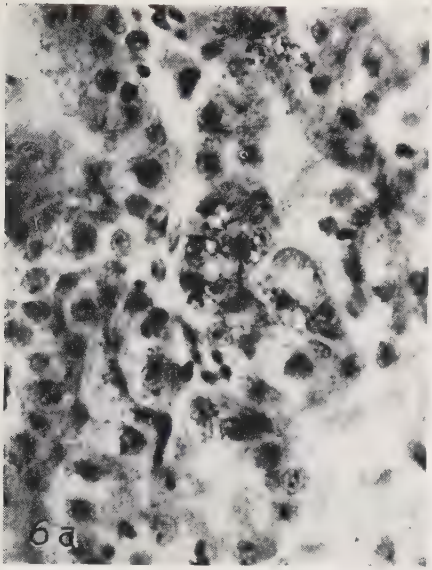
6a

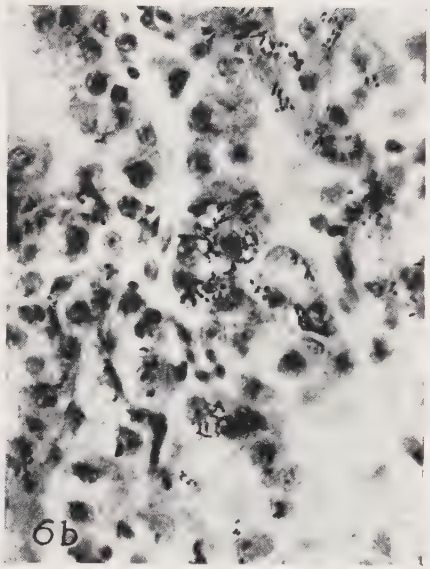
6b

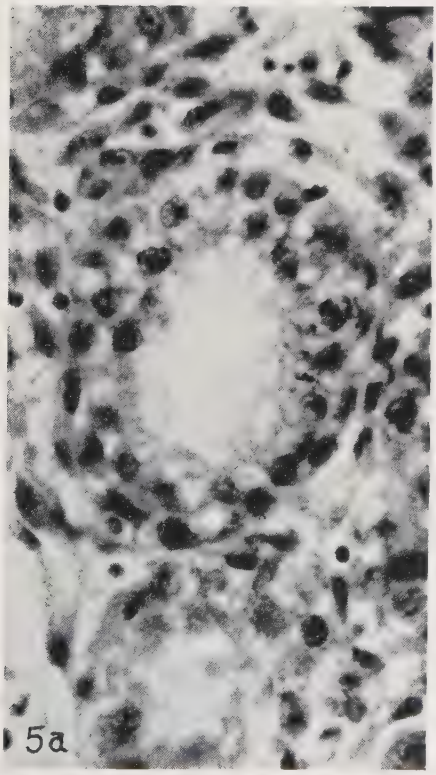
5a

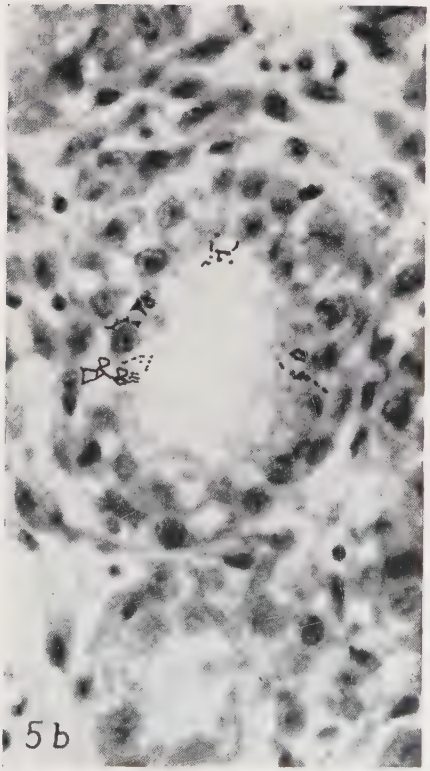
5b

DESCRIPTION OF THE BRAIN OF A HUMAN CYCLOPIAN MONSTER

FRED A. METTLER AND CECILIA C. METTLER
Department of Anatomy, University of Georgia School of Medicine

ONE FIGURE

In 1832 the Medical School of the University of Georgia (then the Medical Institute of Georgia) acquired through the offices of Dr. Louis A. Dugas, at that time traveling in Paris, the monster about to be described. Its exact history is not known, but its was apparently preserved in pyroligneous acid, then a popular solution for such purposes. In appearance it has the aspect of a full-term foetal monstrosity (fig. 1) of the type denoted 'cosmobia' by Wilder and presents a single median symmetrical eye and no sign of external nasal apparatus. In this respect the specimen represents one of the most perfect examples of cyclopia in the literature since, as Stockard points out, specimens of this sort vary from the single median eye type through hour-glass varieties to simply a condition of approximated separate eyes.

MACROSCOPICAL EXAMINATION OF THE BRAIN AND CRANIAL VAULT

Instead of two bilaterally symmetrical hemispheres there was found upon opening the cranial case, a firm continuous mass of nervous tissue which was shaped like a horseshoe and which occupied for the most part the lateral portions of the middle and all of the anterior cranial fossae. The concavity of the mass lay above the corpus sphenoidale. The exact nature of the tissue in the floor of the concavity was obscured by an efflorescence of fibrous tissue of membranous character which rose from the inside rim of the uncinate nervous mass to

Fig. 1 External appearance of the specimen described in the text.

attach rather firmly upon the under side of the calvarium just beneath the vertex. It was later found that this represented the remains of a cyst-like cavity which rose above the diencephalon. The latter lay in the space between the limbs of the uncinate structure which represented what there was of a telencephalon.

Upon removal of the brain from the cranial cavity, care having been taken to leave as much of the nerves behind as possible, it was found that the abnormalities of the vault were restricted to the anterior and middle cranial fossae. In the former, although no definite ethmoid plate could be found, the frontal metopic suture had fused most of the two components of the frontal bone together. Where the ethmoid plates might have been found a bone defect communicated with the single orbital cavity beneath but this defect was covered by dura. The ethmoid spine was absent, but there were present two protuberances situated side by side and almost in the mid-line and directly behind the bone defect noted above. The authors considered them to be the anterior clinoid processes. A single median optic foramen communicated between these with the unpaired orbit. The dorsum sellae swung up sharply behind the fossa hypophyseos at a distance of 1.7 cm. from the ridge between the anterior clinoids. (Although the conventional term 'fossa hypophyseos' is here employed it might perhaps be difficult to substantiate the use of it for the structure designated in this case.) A single optic nerve emerged from the anterior aspect of the fossa and, splitting in two, passed partially to one-half of the base of the brain and partially to the other. Behind the bifurcating nerve a mass of arteries and connective tissue arose. Among this material two very small internal carotid arteries could be found coming from rudimentary foramina lacera. An infundibular stalk blended inferiorly with a mass of tissue which may have been the hypophysis. The latter was separated from a well-defined sphenoid sinus by a dense membrane. The trochlear nerves passed into the lateral aspects of the tissue of the fossa.

Prominent oval and round foramina and the superior orbital fissure contained the three branches of the trigeminus, respectively. The abducens entered the latter opening also. Through the superior orbital fissure the middle cranial cavities communicated with the median orbit. The remaining cranial nerves, all of which were present, had usual relationships.

A definite and well-defined tentorium cerebelli was present but no falx cerebri could be found.

The ventral aspect of the removed brain showed what appeared to be a normal brain stem and infundibulum surrounded by a mass of nervous tissue on its lateral and anterior aspects. The optic nerve divided into two portions which penetrated beneath the mass in what may be designated as the ponto-crural angle. The pons appeared exceptionally small and the pyramids atrophic. The inferior olives seemed unduly prominent. The cerebellum was not unusual.

MICROSCOPIC STUDY

The brain was embedded and cut in celloidin. Nissl and hematoxylin-eosin stains failed to give good 'takes' on the tissue. Unstained and Weil technique sections, however, afforded results suitable for study. The cells in general were poorly preserved, but nuclear accumulations could be clearly made out and the general principles of topography could be followed with ease.

Very few peculiarities were noted in sections taken at levels between the nuclei of the fasciculus gracilis and cuneatus and the aqueduct. The sections corresponded closely with those described by D. Davidson Black for these levels. Professor Black's excellent study of a well-preserved and stained preparation is recommended for reference. The chief feature is the absence of the pyramids at all levels. In the region of the pons, and somewhat above it, the absence of these structures seems to have had a disorganizing effect upon the fiber arrangement of the tegmentum, but below the pons this cannot be said to be true. The absence of the pyramids in the region

of the most caudal part of the inferior olive results in the approximation of the cells of the arcuate and medial accessory olives so that these appear to form a single cellular mass in some regions. Where the decussation of the pyramids normally is found some fibers are noticed to form a ventral decussation such as is present in the cord at lower levels.

The reason for the hydrocephalic condition was found in an almost complete obliteration of the sylvian aqueduct at levels through the region of the inferior colliculus. Above this point the iter was bulged out as though from interior pressure. It should be further pointed out that there was considerable exuberant overgrowth of the pial membranes about the cerebellar hemispheres below this point of occlusion.

The red nuclei when they appeared were separated from the ventral periphery by a thin plate of tissue representing the substantia nigra. Both the superior and inferior colliculi were well represented as prominent nuclear accumulations, but the superior colliculi were more of the nature of an undivided common mound than of two distinct hillocks. From between the inferior colliculi a dorsal extension of membranous tissue sprouted upward and backward being continuous with the generally exuberant pia. Anterior to the red nuclei the brain stem lost all semblance of orderly growth and was represented by a generally shapeless cellular mass. A large portion of the dorsal aspect of the stem was composed of fibrous connective tissue through which ran an abundance of blood vessels. No definite divisions of the common central mass could be discerned and nothing representing an internal capsule was found connecting this structure with the pallial semicircle about it. Such association as existed was in the nature of strands of connective tissue and blood vessels. The pallium consisted of a fairly well-stratified arrangement which was not well enough preserved to be dogmatic about specific characteristics.

Of the ventricular system of the cerebrum the lateral ventricles were present and communicated anteriorly, where the lateral cerebral masses converged, with the open space dorsal to the brain stem.

Histologically the single optic nerve was found to consist of fibrous tissue which became lost in the brain membranes in the region of the thalamic mass. No definite geniculate body could be found. The histologic structures entering the fossa hypophyseos from the ventral aspect of the thalamic mass were likewise composed of strands of fibrous tissue and blood vessels.

For discussion of embryonic factors involved in the formation of an unpaired cerebrum and orbit, see Adelmann ('36).

SUMMARY

A description of the brain of a human cyclopian monster is presented. The findings are less exact and detailed than those presented by Black and confirm his studies in all respects in which conclusions could be drawn.

LITERATURE CITED

Adelmann, Howard B. 1936 The problem of cyclopia. Quart. Rev. Biol., vol. 11, pp. 284–304. (See also J. Exp. Zoöl., 1937, vol. 75, pp. 199–237.)

Black, D. D. 1913 Central nervous system in a case of cyclopia in homo. J. Comp. Neur., vol. 23, pp. 193–257.

Stockard, C. R. 1921 Developmental rate and structural expression. Am. J. Anat., vol. 28, pp. 115–277.

Wilder, H. H. 1908 The morphology of cosmobia. Am. J. Anat., vol. 8, pp. 355–440.

THE INNERVATION OF THE SUPRARENAL GLANDS [1]

C. A. SWINYARD

Departments of Anatomy, University of Minnesota and Tufts Medical School

ONE PLATE (FOUR FIGURES)

INTRODUCTION

A study of the literature, as reviewed by Alpert ('31), reveals many differences of opinion regarding the innervation of the suprarenal glands. Some of the disputed points involve the relative number and location of ganglion cells within the gland, the origin and relative abundance of medullated and non-medullated fibers which supply the gland, the morphology and location (intra- or extracellular) of the various types of nerve endings, the innervation of the blood vessels and particularly the existence of a nerve supply to the cortical cells. In view of the recent paper by Hollingshead ('36), attention need be called to only a few points in the literature.

Elliott ('13), one of the first to study the question of the origin of the nerve fibers to the suprarenals, divided the splanchnic nerves of a cat just below the diaphragm and found a portion of the nerve fibers to be preganglionic. Elliott's work has been misinterpreted in several instances. Rogoff ('28), in Cowdry's Special Cytology, cites Elliott's work as evidence that there are no postganglionic nerves in the suprarenals. Grollman ('36), in his recent monograph, also quotes

[1] This work was begun at the Institute of Anatomy, University of Minnesota, and completed during the author's tenure of a Charlton Research Fellowship in anatomy at Tufts College Medical School.

I wish to express my sincere appreciation to Dr. A. T. Rasmussen of the University of Minnesota for his very helpful suggestions and criticisms as the work progressed.

Elliott as authority for the statement, "The fibers to the adrenals are derived from the adrenal (or suprarenal) plexus and are probably all postganglionic and unmyelinated." Further, Grollman states, "In the rabbit the right adrenal is supplied by both right and left splanchnics while the left gland receives fibers from the right splanchnic only." Although no reference was given for this statement it was probably based on the work of Imamura. According to Hoshi ('27), Imamura's evidence was derived from physiological and pharmacological experiments rather than from morphological data. Jacobi (1892) and Hoshi ('27) studied the suprarenals of the rabbit experimentally by cutting the splanchnic nerves and found that most of the nerve fibers to the rabbit suprarenal were preganglionic and there was no evidence that the glands were innervated by the splanchnic nerves of the opposite side.

When Hollingshead ('36) cut the greater splanchnic nerve only (two cats), he found no degeneration in the suprarenals, but when he cut both greater and lesser splanchnic nerves (five cats), he found 'moderate' degeneration. Hollingshead admits that no comparison is possible between the operations in which he cut the splanchnic nerves and in those in which thoracic nerves were cut, because of the variation in the number of thoracic nerves cut. He found more degeneration in a cat in which the last six thoracic nerves were cut than in one in which the last two plus the upper three lumbar nerves were cut. This is difficult to explain in view of the fact that he found no degeneration when the greater splanchnic nerve alone was cut and he comes to the conclusion that the majority of the fibers do not enter the suprarenal by way of the greater splanchnic nerve. Hollingshead was able to completely eliminate myelinated fibers from the suprarenal only by cutting the greater and lesser splanchnic nerves and completely denuding the gland, or removing the upper three segments of the lumbar sympathetic chain. In some cases he also removed a portion of the coeliac ganglion. In such cases Hollingshead found what he termed 'extensive' degeneration in the suprarenal. This was probably due to destruction of not only preganglionic fibers but also some postganglionic fibers.

OPERATIVE METHODS

Since the suprarenals derive their innervation mainly from the splanchnic nerves and the first few segments of the lumbar sympathetic chain, and inasmuch as occasional ganglion cells may be found along these nerves and at any distance from the glands, it was felt that in order to bring about degeneration of the preganglionic fibers and avoid cutting any postganglionic fibers the more certain approach was that of cutting the ventral roots of spinal nerves.

Successful laminectomies were performed on eighteen cats in which the nerves cut varied from the last three to the last ten thoracic nerves, or the last eight thoracic plus the first two lumbar nerves. In twelve of these animals both dorsal and ventral spinal nerve roots were cut. Both roots could be cut with much less difficulty than could one and the operation time was correspondingly reduced. The point of division was central to the dorsal root ganglia. In six animals, only the ventral roots were cut. In two animals the vagus nerve was cut and in one the dorsal root ganglia of the last seven thoracic nerves were removed. The glands were sectioned serially at 20 μ. The gland on the unoperated side was used as a control and stained at the same time as the gland from the operated side. Most of the sections were stained by the use of Davenport's silver technic, although the Ranson's pyridine silver method was frequently used. The former technic seemed to be better adapted to this tissue and gave more uniform results. Some of the glands were stained by the Pal-Weigert method for the study of myelinated fibers.

The human suprarenals were obtained at autopsy from 2 to 8 hours postmortem, fixed in formalin and cut serially at 20 μ. At first every twelfth section was used, but subsequently other sections were mounted whenever it seemed desirable to trace a given nerve more fully. The sections were stained with the Davenport silver method, Bielschowsky technic, Roger's modification of the Bielschowsky method and the Pal-Weigert method.

RESULTS OF EXPERIMENTS ON THE CAT

A careful study of the suprarenals of the unoperated side and of the glands from unoperated animals indicates that most of the nerve fibers approaching the suprarenal of the cat are myelinated. The bundles of nerves vary in size from those containing only a very few fibers to those containing hundreds of fibers. With respect to the distribution of the nerves in the cat, the writer's findings are in complete accord with those of Hollingshead. No evidence of a cortical innervation could be found. After leaving the capsule the nerves run directly through the cortex without giving off any branches to the cortical cells. Upon reaching the cortico-medullary junction the nerves frequently bend and run parallel to the cortico-medullary junction for some distance before breaking up into the plexus of fibers which end in relation to the medullary cells. The writer corroborates the finding of Hollingshead also with respect to the close association of nerve fiber bundles and blood vessels. Nerve bundles were usually found in close association with blood vessels and the fibers were often seen to end in the wall of the vessels. Ganglion cells were frequently found just outside the capsule or within the capsule but never in the cortex proper and only rarely in the medulla of the cat suprarenal. The largest number of ganglion cells found in the medulla of any gland of the cat was twelve and in most of the glands there were only two or three or they were entirely absent. This individual variability is undoubtedly responsible for much of the disagreement in the literature on this point.

In seven animals in which the last eight thoracic and first two lumbar nerves were cut, it was found that all of the medullated nerves were eliminated from the gland and from 50 to 70% of the nerve bundles which entered the gland were degenerated. The range of degeneration was no different in five animals in which only the last nine or ten thoracic nerves were cut and the lumbar nerves left undisturbed. In the operated animals the remaining postganglionic fibers were distributed to both the medullary cells and the blood vessels.

Although perhaps the majority of the postganglionic fibers ended on blood vessels the medullary plexus was still present but greatly reduced.

End bulbs similar to those described by several previous writers were observed on the postganglionic nerve endings. On numerous occasions postganglionic fibers were seen leaving terminal ganglia which were located some distance away from the glands. As the nerves were followed toward the glands the myelinated fibers appeared to decrease in number while the non-myelinated fibers increased in number. The implication of this is that postganglionic fibers are constantly arising in terminal ganglia located at variable distances from the glands and within the gland itself. In many instances these postganglionic fibers could be traced from the terminal ganglion into the suprarenal. It is therefore very probable that when Hollingshead denuded the gland some of these terminal ganglia were of necessity removed and his so-called 'extensive' degeneration included some postganglionic fibers as well as preganglionic fibers. Although Kure et al. ('32) believe that some of the fine medullated nerve fibers which go to the suprarenal glands are spinal parasympathetic fibers leaving the cord by the dorsal root, no difference in the amount of degeneration could be detected in animals in which both dorsal and ventral roots were cut as compared with those in which only the ventral roots were cut. Removal of the dorsal root ganglia of the thoracic nerves caused no degeneration within the gland, thus giving no support to the idea of Kure et al. nor to the view that there is any significant afferent supply from this source. The animal in which a vagectomy was performed showed no evidence of degeneration in either suprarenal. This is also in complete agreement with the recent work of Hollingshead.

DISTRIBUTION OF THE NERVES IN THE HUMAN SUPRARENAL

Careful study of the human suprarenal with the Davenport silver technic revealed that the nerves of the human gland are distributed in the same manner as in the cat. With the use

of either the Davenport or Ranson's silver method even the finest nerve fibers of the medulla were clearly visible and in no case was there any good evidence of a cortical innervation. This agrees with the observations of Hoshi ('27) and Kolossow ('30). However, if the suprarenal was stained with the Bielschowsky technic or the Roger's modification of the Bielschowsky technic a very different microscopic picture was presented. With these technics the reticular fibers of the suprarenal stain just as black and as readily as do the nerve fibers. Delicate fibrils leave the capsule and surround the cells of the glomerulosa as in Stöhr's ('35) description; but careful comparison indicates that they are reticular fibers. In the literature are found several warnings regarding the possibility of error in misinterpretation of Bielschowsky preparations. The paper by Bartelmez and Hoerr ('33) is particularly emphatic on this point. Methods of suppressing the connective tissue in silver stains have been carefully studied by Beech and Davenport ('33).

A comparison of figures 1 and 2—the former a photomicrograph of the cortical area of the human suprarenal stained with the Bielschowsky technic, the latter a view of a similar area stained with the Davenport silver method—illustrates the difference obtained by the use of these two methods. Indeed, figure 1 bears a striking resemblance to the figures of Alpert ('31). Using the Bielschowsky technique Alpert found an abundant supply of what he thought were non-myelinated nerves which ran from the capsule to the zona glomerulosa and zona fasciculata, eventually forming a basket-like network around each group of cortical cells. These and other details of cortical innervation described by Alpert and also by Stöhr ('35) are not corroborated by this study when the reticular tissue is suppressed. Nerve bundles in the cortex could be traced through to the medullary tissue. Even though the finest nerve fibers in the medulla were sharply brought out by Ranson's or Davenport's methods the nerve bundles did not appear to give off any branches either in the capsule or in the cortex. Stöhr ('35) points out, however, that the

nerve fibers of the cortex are extraordinarily fine, not easily impregnated and difficult to see. His drawing at a magnification of 2400 diameters shows a number of extremely fine fibers, but nowhere are the fibers shown to come in contact with the glomerulosa cells. It is significant that Stöhr was unable to find any specially constructed nerve endings in the cortical portion of the suprarenal.

The zona reticularis was described by Dogiel (1894), Alpert ('31) and Stöhr ('35) as receiving fibers from the medullary plexus as well as from the outer zones of the cortex and capsule. The writer has frequently observed portions of the zona reticularis which were more or less surrounded by medullary tissue and in such places nerve fibers may appear to be closely related to the cells of the zona reticularis. Such a situation is illustrated in Stöhr's paper, but there does not seem to be any evidence that these fibers actually end on the cortical cells. One gains the distinct impression that the nerve fibers were merely passing between the reticular cells on their way to adjacent medullary cells.

With regard to the innervation of the medullary portion of the human suprarenal the writer is, however, in agreement with the findings of Alpert, Stöhr and others. There is an abundant plexus of nerve fibers which end in close relation to the chromaffin cells.

Ganglion cells were frequently encountered in the medulla of the human suprarenal as noted by others. There is considerable variation in the number present in different glands. Ganglion cells were only rarely encountered in the cortex and then they were always within the nerve bundles running through the cortex to the medulla. Ganglia of various sizes were found in the capsule and along the course of nerves in the connective tissue outside the capsule. Bundles of nerve fibers can be traced through the cortex to end directly around ganglion cells of the medulla. Most of the blood vessels passing through the cortex are accompanied by such nerves, but many nerves pass through the cortex independently. A group of nerve fibers approaching a cluster of ganglion cells is

shown in figure 3. These ganglion cells appear to be the same in morphology as other terminal ganglia. The fibers which end on the ganglion cells show the various types of end-knobs described by Stöhr. Although no thin sections were prepared for a special study of the question of the position of the nerve ending with respect to the cell membrane, Alpert and Stöhr and others have reported both extra- and intracellular nerve endings on both the ganglion cells and chromaffin cells. The question of intracellular nerve endings probably needs further investigation.

With reference to the relative number of medullated and non-medullated nerves which enter the human suprarenal, Renner ('14) merely stated that both types were present. Dogiel (1894) reported that they were nearly all non-medullated. Hoshi ('27) found from one-third to one-half to be medullated. Alpert ('31) did not indicate the relative abundance of the two types. Approximate enumeration by the writer indicates that about one-half of the nerve fibers approaching the gland are myelinated. They are probably preganglionic. According to Kure et al. ('32), Kura ('27) found that there were many ganglion cells along these nerves and that the fine medullated fibers diminish in number within the gland and as the gland is approached, while the non-myelinated fibers correspondingly increase in number, as in the case of the cat. As observed by Stöhr the nerve bundles upon reaching the medulla frequently turn and run parallel to the cortico-medullary junction before finally entering the medulla. Relatively large nerve bundles are frequently closely associated with the larger blood vessels of the medulla as shown in figure 4.

SENSORY NERVES

Pines and Narowtschatowa ('31) described what they termed knob-shaped sensory end organs in the adrenal of the cat and Kura ('27) described similar so-called sensory end organs in the human gland. These structures were not found by Stöhr nor by the writer. Neither Hollingshead nor the writer found any degeneration in the suprarenal of the cat

following removal of the dorsal root ganglia of the thoracic nerves. This evidence does not support the presence of sensory nerves in the suprarenal of this species. The writer was also unable to find structures suggestive of sensory nerve endings in the human suprarenal.

CONCLUSIONS

1. The nerves to the suprarenal gland of the cat arise mainly from the last few thoracic spinal nerves.
2. The vagus nerve apparently contributes no fibers to this gland.
3. There are very few if any afferent fibers to this gland.
4. From 50 to 70% of the nerve bundles entering the suprarenal gland of the cat contain small myelinated preganglionic fibers.
5. Postganglionic fibers arise from terminal ganglia located at variable distances along the course of the nerves as well as within the gland; hence, denuding of the suprarenal results in destruction of some of the postganglionic fibers as well as the preganglionic fibers.
6. About one-half of the nerve fibers entering the human suprarenal gland were found to be myelinated.
7. No evidence of a cortical innervation of the suprarenal was found in either man or the cat.
8. The abundant cortical innervation described by several authors appears to be largely reticular tissue rather than nervous tissue. The Bielschowsky technic was shown to be unreliable in situations where reticular tissue is abundant.
9. Ganglion cells were found to be more frequent in the human suprarenal than in the cat, but there is great individual variation in the same species. Some cats contained no ganglion cells within the suprarenal gland and the maximum number was only twelve.
10. The nerves which penetrate the cortex may end around clumps of ganglion cells in the medulla. The ganglia in the medulla and those in the capsule are probably similar to other terminal ganglia located outside of the gland.

LITERATURE CITED

Alpert, L. K. 1931 The innervation of the suprarenal glands. Anat. Rec., vol. 50, pp. 221–234.

Bartelmez, G. W. and N. L. Hoerr 1933 The vestibular club endings in Ameiurus. J. Comp. Neur., vol. 57, pp. 401–428.

Beech, R. H. and H. A. Davenport 1933 The Bielschowsky staining technic. A study of the factors influencing its specificity for nerve fibers. Stain Tech., vol. 8, pp. 11–30.

Dogiel, A. S. 1894 Die Nervenendigungen in den Nebennieren der Saügethiere. Arch. f. Anat. u. Entw., Anat. Abt., Bd. 91, S. 90–104.

Elliott, T. R. 1913 The innervation of the adrenal glands. J. Physiol., vol. 46, pp. 285–290.

Grollman, A. 1936 The Adrenals (monograph), pp. 25–26. Williams and Wilkins Co., Baltimore.

Hollingshead, W. H. 1936 The innervation of the adrenal glands. J. Comp. Neur., vol. 64, pp. 449–468.

Hoshi, T. 1927 Morphologisch-experimentelle Untersuchungen über die Innervation der Nebenniere. Mitt. üb. allg. Path. u. path. Anat., Bd. 3, S. 328–342.

* Imamura Keio-Kgaku (Japanisch), vol. 4, no. 12.

Jacobi, C. 1892 Beiträge zur physiologischen und pharmakologischen Kenntniss der Darmbewegungen mit besonderer Berücksichtigung der Beziehung der Nebenniere zu denselben. Arch. f. Exp. Path. u. Pharm., Bd. 29, S. 171–211.

Kolossow, N. G. 1930 Zur Frage der Innervation der Nebennieren. Ztschr. f. mikr. anat. Forsch., Bd. 20, S. 107–121.

* Kura, N. 1927 Kyoto-Furitsu-Ikadaigaku-Zasshi, i.

Kure, K., Y. Wada and S. Okinaka 1932 The spinal parasympathetic (6th article). The nerve supply of the suprarenal gland. Quart. J. Exp. Physiol., vol. 21, pp. 227–241.

Pines, L. and K. Narowtschatowa 1931 Über die Innervation der Nebennieren. Ztschr. f. mikr. anat. Forsch., Bd. 25, S. 518–538.

Renner, O. 1914 Die Innervation der Nebenniere. Deutsch. Arch. f. klin. Med., Bd. 114, S. 473–483.

Rogoff, J. M. 1928 The suprarenal gland. Cowdry's Special Cytology, vol. 2, pp. 872–873. Paul B. Hoeber, Inc., New York.

Stöhr, P., Jr. 1935 Zur Innervation der menschlichen Nebenniere. Ztschr. f. Anat. u. Entw., Bd. 104, S. 475–490.

* Original paper not examined.

PLATE

PLATE 1

EXPLANATION OF FIGURES

1 Photomicrograph of zona glomerulosa of human suprarenal. Bielschowsky technic. × 130. The fibers entering the cortex from the capsule are apparently reticular fibers rather than nerve fibers.

2 Photomicrograph of zona glomerulosa of human suprarenal. Davenport silver method. × 130. While this technic brings out abundant nerve fibers in the medulla and passing through the cortex, no fibers seem to be related to the cortical cells.

3 Photomicrograph of a cluster of ganglion cells in the medulla of the human suprarenal. Davenport silver method. × 130. To the left is a large bundle of nerve fibers entering the ganglion.

4 Photomicrograph of a nerve bundle in close relation to a blood vessel in the medulla of the human suprarenal. Davenport silver method. × 130.

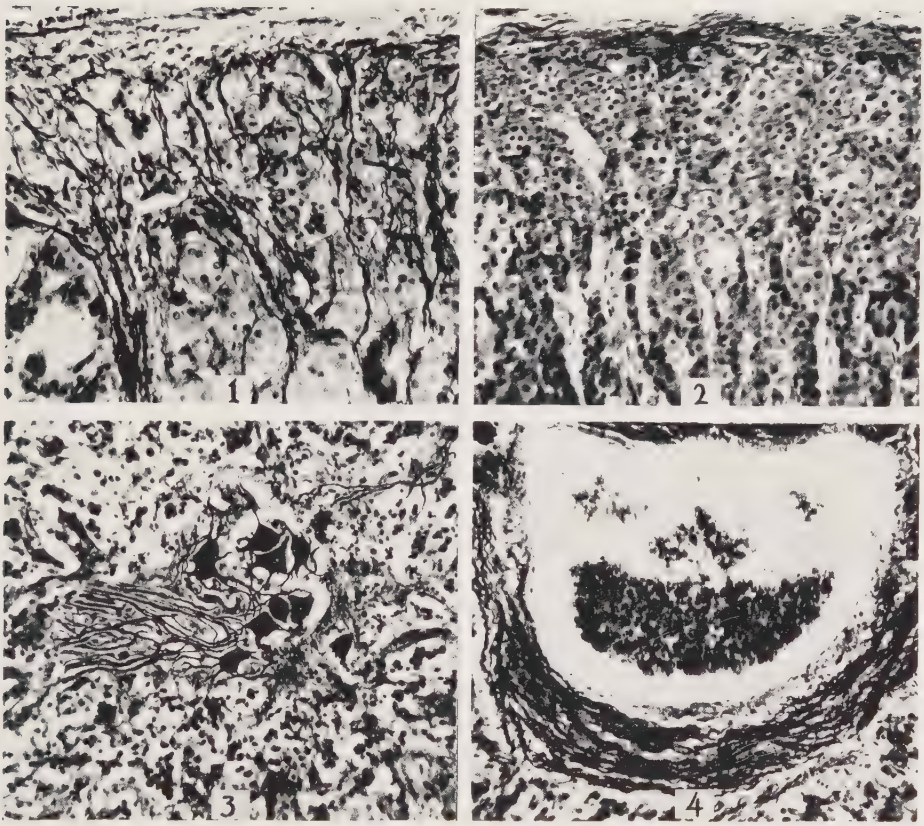
1
2
3
4

FUNCTIONAL TRANSPLANTS OF THE PRIMORDIUM OF THE EPITHELIAL HYPOPHYSIS IN AMPHIBIA

WAYNE J. ATWELL

Department of Anatomy, University of Buffalo

ONE TEXT FIGURE AND TWO PLATES (SIXTEEN FIGURES)

The intimate relation existing between the hypophysis and the brain has made plausible the assumption that such relation is necessary for the functioning of the gland. This also was the conclusion reached by Blount ('30, '32, '35) on the basis of transplantation experiments with Amblystoma punctatum. It was held that the epithelial portion is dependent for its development upon an association with the neural portion.

However, evidence has been accumulating that contact with the brain is not necessary for some of the functions of the hypophysis. The earlier experiments of Allen ('20) and of Swingle ('21) showed that the separate lobes of the adult amphibian hypophysis when transplanted could persist and function. In a preliminary report the writer (Atwell, '35) found that "transplantation of the primordium of the epithelial hypophysis, independent of brain or fore-gut, may be followed by differentiation and function of the transplant in R. sylvatica and R. pipiens."

Etkin ('35) made successful single and multiple transplants in R. sylvatica with a minimum of brain tissue, but he made no attempt to remove all possible adherent brain.

Recently several authors have reported success in transplanting hypophyseal tissue in mammals. Persistence of hypophyseal tissue has been reported when the transplant was placed in the kidney of the rat (Hohlweg and Junkmann,

'32), the testis of the mouse (Gardner and Hill, '35), the anterior chamber of the eye of rabbits and guinea pigs (Haterius, Schweizer and Charipper, '35) and of rats (Buxton, '36) and in the empty sella (Greep, '36). Evidence of function of the transplant has been obtained by Hill and Gardner ('36) (testis and adrenal cortex maintained in normal condition as was also a transplanted ovary in one case); by Greep (growth maintained but at a reduced rate; female sexual cycles, somewhat prolonged; pregnancy); and by Schweizer, Charipper and Haterius ('37) (ovaries maintained in the follicular phase, without cycles, giving rise to a condition of constant estrus). Unfortunately, both of Hill and Gardner's positive cases showed small remnants of the normal hypophysis. May ('35) reported functional intraocular transplants in the rat.

In the present paper functional hypophyseal transplants in two species of frogs and one of the salamander are described and illustrated by means of a series of photographs.

EXPERIMENTAL PROCEDURE

Young larvae of Rana sylvatica, R. pipiens and Amblystoma punctatum were used. At the tail-bud stage of the frogs and at Harrison's stages 30 to 32 in Amblystoma the primodium of the epithelial hypophysis was removed from its orthotopic position and transplanted to a location between the right otic vesicle and the hind-brain. By experiments carried on in three different years the operation was attempted on a total of 93 R. sylvatica, 30 R. pipiens and 145 A. punctatum.

Operated animals and controls were reared in the laboratory, the frog larvae receiving a diet of boiled lettuce and boiled liver, and the salamanders being fed successively a species of white worm, bits of earthworm, frog tadpoles, raw liver and raw beef muscle. The animals were observed as to color, growth and differentiation until metamorphosis occurred or until considerably more than the time normally required for metamorphosis had elapsed. In some cases animals were observed for more than a year. At the time of autopsy, body length, tail length and length of hind and front

legs were recorded for the frogs, and body length and tail length for the salamanders, with notes on the stages of metamorphosis for both.

In frog larvae progress toward metamorphosis is indicated by growth of large hind legs, appearance of front legs, reduction of the tail and characteristic changes in the shape of the body, the head and particularly the mouth. In salamanders the most obvious external changes are the disappearance of external gills and of the tail fin, thickening of the legs and changes in shape of the head and the body.

Sufficient of the cranium and its contents was removed to insure serial sections of the hypophyseal region and the region of the transplant. Due to the transparency of the skull floor the hypophyseal region frequently could be examined prior to fixation and the presence or absence of the hypophysis noted. In a few instances the transplant also was observed at this time.

The thyroid glands were located, observed and removed for fixation. Likewise the adrenal-gonad region was examined and fixed. In order to preserve and color the lipoid material of the adrenal cortex this region was fixed in a chromic-osmic mixture (Fleming's fluid less the acetic acid). After clearing either by chloroform during the process of embedding in paraffin or by glycerine the content of osmiophilic material was noted under the binocular microscope. Then the tissue was cut into serial sections at 7 μ and stained with Babe's saffranin.

The blocks of tissue from the head and the thyroid region were preserved in Bouin's fluid, embedded in paraffin, sectioned serially at 10 μ, and stained with hematoxylin and eosin.

Of the experimental animals sixty-four R. sylvatica, eight R. pipiens and eighteen A. punctatum upon which transplantation had been attempted have been studied by means of serial sections. Others have been examined grossly at autopsy for the condition of the hypophysis region and of the thyroid, but have not been sectioned when examination revealed remnants of the hypophysis in the orthotopic position. For control

study records and serial sections from more than 200 normal, or completely or partially hypophysectomized amphibia were available.

It is a pleasure to acknowledge the assistance rendered by Mr. Paul Zoltowski, student in the School of Medicine.

OBSERVATIONS

For a transplantation experiment to be considered successful a study of serial sections was required to show: 1) entire absence of the epithelial hypophysis from the orthotopic position, 2) characteristic hypophyseal tissue in the region into which the transplant had been placed, and 3) some evidence of function of the transplant as described below. A total of 34 such animals are included in this study, 26 being of R. sylvatica, 4 of R. pipiens and 4 of A. punctatum.

Location and relations of transplant. The transplant was most often found inside the cranium between the floor of the skull and the hind-brain in the vicinity of the right internal ear (figs. 6 and 7). In a few cases the transplant was partially (fig. 8) or completely (fig. 10) embedded in the cartilage of the skull floor, and in one specimen (RS-35-0-7) it was found external to the skull.

In the frogs only one case of contact between transplant and brain was discovered. In this the transplant apparently had been put directly into the wall of the brain (fig. 11). The hind-brain exhibits a pronounced bulging with a separate ventricular cavity. Two distinct parts of the transplant are visible.

Usually the transplant lies outside the meninges (figs. 6 to 10) and the neighboring hind-brain exhibits no outgrowth or other evidence of reaction to the transplant.

Each of the four specimens of A. punctatum shows a peculiar mass of tissue near the transplant. In three cases this is readily identified as having the structure of the central nervous system (figs. 1, 12, 13). In the fourth case, the mass, which is contained in the otic capsule, rather than in the

cranium as are the others, resembles embryonic supporting tissue.

The masses of nervous tissue, though near the brain, are not connected with it except in one case. In this one there is a rather tenuous attachment of the mass to the adjacent side of the infundibular region.

The cyst-like mass of brain tissue is of sufficient size to displace the acoustic ganglion or the internal ear caudally (fig. 1) and to exert a molding effect on the neighboring part of the

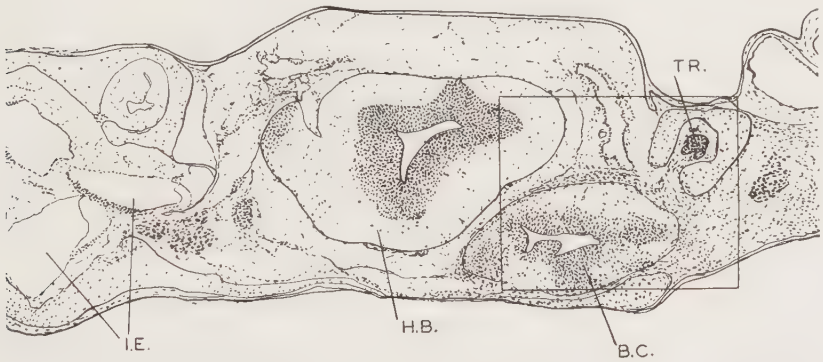

Fig. 1 Transverse section through the head of a specimen of Amblystoma punctatum (AP-36-3-2) showing location of hypophyseal transplant (TR.) and of an isolated mass of brain tissue (B.C.) which forms a cyst-like structure in the neighborhood, and displaces the internal ear caudally. H.B., hind-brain; I.E., internal ear on control side. The outlined rectangular area is reproduced as a photomicrograph in figure 13.

brain. In some cases it was recognized through the floor of the skull at autopsy and in one instance it measured nearly 3 mm. in diameter.

Although the cyst-like mass was always found in the vicinity of the transplant, in no case was there an intimate relation between the two, such as exists between the hypophysis and the infundibulum and neural lobe in the normal animal. A slight connection between the transplant and the brain cyst is usually present, however. The nature and degree of this connection is shown for two animals by figures 12 and 13.

Structure of the transplant. Except for a few cases in which the animal was sacrificed within a week after the operation the transplant was found to be well vascularized. In almost every case the net-like arrangement of cell cords characteristic of the anterior lobe proper (pars distalis) was found, as shown in figures 7 to 10. Although none of the finer cytologic techniques have been employed and no cell counts attempted, it has been possible to identify acidophilic and other types of cells in the transplants.

In only a few cases has it been possible to identify a part exhibiting the characteristic structure of the pars intermedia (fig. 8), and in none has a pars tuberalis been recognized.

Sometimes small masses of cartilage are seen near the transplant (fig. 7) suggesting the possibility that they have developed from fragments of mesoderm included with the transplant. No attempt was made to free the epithelial transplant of mesoderm.

Evidences of function of the transplant. The criteria by which activity of the transplant can be determined are certain of those effects which are produced by the hypophysis in its orthotopic location. The state of function of the pars intermedia can be judged by the pigmentary condition of the animal. If the tadpole is normally dark it seems safe to conclude that its contains functioning pars intermedia, for if the entire epithelial hypophysis or only the pars intermedia is removed (Atwell and Holley, '36) the animal is silvery.

As evidence of function of the anterior lobe proper (pars distalis) the most striking external sign is the metamorphosis of the animal. While metamorphosis is directly under control of the thyroid, normally the stimulus of a thyreotropic influence from the hypophysis is required.

At autopsy the condition of the thyroid glands and the adrenals can be used as indicators of anterior lobe activity.

All of the 'successful' cases showed some evidence of anterior lobe function except three which were sacrificed at a stage before complete differentiation of the thyroid gland had taken place. The attainment of the degree of differentiation shown

in figures 2 to 5 was taken as proof of anterior lobe function and the animal was usually sacrificed at this time. A few frogs were permitted to complete their metamorphosis and lived in air for 2 weeks or more.

Differentiation was often greatly prolonged and the usual larval period of 2 months was extended in a few cases for 8 to 10 months. This retardation of metamorphosis provided a slow motion picture of differentiation. In the frog larvae sometimes one front leg protruded through the skin several weeks before the second one escaped. Usually it was the left front leg which appeared first; probably this is related to the location of the spiracle on this side.

In some cases metamorphosis took place in the usual length of time. In successfully transplanted cases the thyroid glands could not be distinguished from those of a normal animal either when examined grossly at autopsy or in microscopic section (fig. 15). This is in marked contrast to the extreme atrophy shown by the completely hypophysectomized animal not bearing a transplant (fig. 14). As noted by Smith ('20) hypophysectomy at an early stage in the frog tadpole causes a marked reduction in the size and content of osmiophilic material in the cortex of the adrenal gland (fig. 16). In every case examined the transplanted hypophysis had maintained the adrenal cortex in a condition not to be distinguished from the normal (fig. 17).

The following observations are of interest because they throw light on the question as to whether contact with neural tissue (even if not the infundibulum) is necessary for the functioning of the pars intermedia. Of the thirty frogs here reported as successfully transplanted, fourteen were normally dark or intermediate in color. In only one of these did the transplant show a relation to the brain, having been accidentally introduced directly into the brain wall (fig. 11). In six others the transplant was in contact with the acoustic ganglion (figs. 8, 9). On the other hand, the remaining seven frogs which were dark or intermediate in color did not show any relation of the transplant to neural tissue (fig. 6). Four of these seven were fully as dark as the normal animal. Further-

more, in one entirely silvery animal (RS-35-2-13) there was contact of the transplant with the acoustic ganglion.

Observation of the skin of a dark transplanted animal showed the melanophores in an 'expanded' or dispersed state, and the leucophores in a 'contracted' state, as in normal animals.

DISCUSSION

It is apparent from the observations recorded above that in R. sylvatica and R. pipiens the primordium of the epithelial hypophysis is able to differentiate and produce several of its characteristic effects quite independently of the brain.

The results obtained with A. punctatum are not so conclusive. Less than 3% of successful transplants have been obtained in the 145 attempts made. In each of the four positive cases there was present near the transplant a detached cyst-like mass of tissue which in three cases is easily identified as brain substance. Although the mass has no intimate relation with the transplant, its invariable presence in all of the successful cases is suggestive of an importance, the exact nature of which is not clear.

The source of the brain material composing the cyst-like masses has not been determined. Whether they have arisen from hind-brain substance, stimulated and detached by the transplantation, or were carried with the transplant from the infundibular region, in spite of the precautions taken not to include brain tissue, is uncertain. The second explanation seems the more likely.

Why functioning transplants free from neural tissue should have been obtained so readily in two species of Rana and apparently not at all in Amblystoma remains undetermined. It has been noted that the physical consistency of the epithelial hypophysis in Amblystoma is different from that of Rana at the time the operation is performed. The salamander gland is more easily broken up during the manipulations necessary to removal and implantation. Perhaps the inclusion of some brain tissue, even inadvertently, has rendered support which has enabled the hypophyseal transplant to persist.

Another possible explanation is that a transitory contact with the brain is necessary for the differentiation of the epithelial primordium and that in the frogs this contact had already been made before operation, while in the salamander it had not. This might be proved by the persistence and differentiation of epithelial transplants made at a later stage in Amblystoma. The necessary experimental proof for either of these possibilities has not been obtained.

The experiments here recorded furnish evidence that the primordium of the epithelial hypophysis, independent of brain tissue, is able to differentiate and to function normally in stimulating metamorphosis, and in maintaining the normal size and histological appearance of the thyroid and adrenal glands, as well as in maintaining the usual dark color of the animal.

Growth is not a safe criterion of activity of the anterior lobe in larval amphibia since hypophysectomized animals continue to grow in an apparently normal manner for some time. Klatt ('33) states that hypophysectomized Triton larvae even go on and become giants.

Likewise the control of the sex glands is of little value until later stages, it having been observed that the gonads of hypophysectomized frog larvae continue to develop in a normal manner for a considerable period (Atwell, '33).

In addition to transplantation experiments other lines of evidence have appeared recently to show the ability of the pars intermedia to exert its chromatophoric influence even when separated from the brain. One of these is the method of tissue culture as employed by Geiling and Lewis ('35) and Anderson and Haymaker ('35). Cultures of the pars intermedia grew and continued to elaborate melanophore expanding hormone in vitro. Another line of evidence is obtained from the studies of Fisher ('37). After the atrophy of the neural lobe which follows interruption of the supra-optico-hypophyseal tracts in cats, the pars intermedia remained normal in appearance and extracts made from it had melanophore expanding potency.

The prolongation of the process of differentiation which was observed in certain cases undoubtedly indicated a relative insufficiency either in the production or absorption of thyreotropic substances in these individuals.

The failure of the development of a recognizable pars tuberalis in any of the transplants raises the question as to the dependence of this part upon a contact with the brain. Unfortunately no answer can be given. Furthermore, so little is known in regard to the function of the pars tuberalis, particularly in Amphibia, that no criterion is available by which possible pars tuberalis activity, even in the absence of morphological differentiation, can be judged.

SUMMARY AND CONCLUSIONS

1. The primordium of the epithelial hypophysis, independent of neural tissue or entoderm, has been removed at the tail bud stage and transplanted to a location between the otocyst and the hind-brain in R. sylvatica, R. pipiens and Amblystoma punctatum.

2. Transplants which differentiated and gave evidence of function have been studied in 26 R. sylvatica, 4 R. pipiens and 4 A. punctatum. In the two frogs both the anterior lobe proper (pars distalis) and pars intermedia functioned independently of contact with neural tissue. Of the four successful cases found in A. punctatum all showed a detached mass near the transplant which usually could be identified as brain tissue.

3. Evidences of function were: a) stimulation of metamorphosis; b) maintenance of the normal size and histological appearance of the thyroid gland; c) maintenance of the normal size and osmiophilic content of the adrenal glands; d) maintenance of the normal dark color of the animal.

LITERATURE CITED

Allen, B. M. 1920 Experiments in the transplantation of the hypophysis of adult Rana pipiens to tadpoles. Science, N.S., vol. 52, pp. 274–276.

Anderson, E. and W. Haymaker 1935 Elaboration of hormones by pituitary cells growing in vitro. Proc. Soc. Exp. Biol. and Med., vol. 33, pp. 313–316.

Atwell, W. J. 1933 Development of the gonads following early removal of the hypophysis in Rana sylvatica. Anat. Rec., vol. 55, Suppl., p. 45 (abstract).

——— 1935 Differentiation and function of heterotopic autoplastic transplants of the amphibian hypophysis. Proc. Soc. Exp. Biol. and Med., vol. 33, pp. 224–226.

Atwell, W. J. and E. Holley 1936 Extirpation of the pars intermedia of the hypophysis in the young amphibian with subsequent silvery condition and metamorphosis. J. Exp. Zoöl., vol. 73, pp. 23–41.

Blount, R. F. 1930 The implantation of additional hypophyseal rudiments in urodele embryos. Proc. Nat. Acad. Sci., vol. 16, pp. 218–222.

——— 1932 Transplantation and extirpation of the pituitary rudiment and the effects upon pigmentation in the urodele embryo. J. Exp. Zoöl., vol. 63, pp. 113–141.

——— 1935 Size relationships as influenced by pituitary rudiment implantation and extirpation in the urodele embryo. J. Exp. Zoöl., vol. 70, pp. 131–185.

Buxton, C. L. 1936 Transplantation of the hypophysis cerebri to the anterior chamber of the eye. Anat. Rec., vol. 64, pp. 277–283.

Etkin, W. 1935 Effect of multiple pituitary primordia in the tadpole. Proc. Soc. Exp. Biol. and Med., vol. 32, pp. 1653–1655.

Fisher, C. 1937 The site of formation of the posterior lobe hormones. Endocrinology, vol. 21, pp. 19–29.

Gardner, W. U. and R. T. Hill 1935 Persistence of pituitary grafts in the testis of the mouse. Proc. Soc. Exp. Biol. and Med., vol. 32, pp. 1382–1384.

Geiling, E. M. K. and M. R. Lewis 1935 Further information regarding the melanophore hormone of the hypophysis cerebri. Am. J. Physiol., vol. 113, pp. 534–537.

Greep, R. O. 1936 Functional pituitary grafts in rats. Proc. Soc. Exp. Biol. and Med., vol. 34, pp. 754–755.

Haterius, H. O., M. Schweizer and H. A. Charipper 1935 Experimental studies on the anterior pituitary. III. Observations on the persistence of hypophyseal transplants in the anterior eye chamber. Endocrinology, vol. 19, pp. 673–681.

Hill, R. T. and W. U. Gardner 1936 Function of pituitary grafts in mice. Proc. Soc. Exp. Biol. and Med., vol. 34, pp. 78–79.

Hohlweg, W. and K. Junkmann 1932 Die Hormonal-Nervöse Regulierung der Funktion des Hypophysenvorderlappens. Klin. Wchnschr., Bd. 11, S. 321–323.

Klatt, B. 1933 Weitere Versuche (Hypophysenextirpationen und -implantationen) an Tritonlarven. Arch. f. Entwick. Mechan. d. Organ., Bd. 130, S. 79–108.

MAY, R. M. 1935 La greffe bréphoplastique de l'hypophyse chez le rat. Compt. rend. Soc. de biol., vol. 120, pp. 867–870.

SCHWEIZER, M., H. A. CHARIPPER AND H. O. HATERIUS 1937 Experimental studies on the anterior pituitary. IV. The replacement capacity and the non-cyclic behavior of homoplastic anterior pituitary grafts. Endocrinology, vol. 21, pp. 30–39.

SMITH, P. E. 1920 The pigmentary, growth and endocrine disturbances induced in the anuran tadpole by the early ablation of the pars buccalis of the hypophysis. Am. Anat. Mem., no. 11.

SWINGLE, W. W. 1921 The relation of the pars intermedia of the hypophysis to pigmentation changes in anuran larvae. J. Exp. Zoöl., vol. 34, pp. 119–141.

PLATES

PLATE 1

EXPLANATION OF FIGURES

2 to 5 Specimens of Rana sylvatica from which the hypophysis was removed at the tail-bud stage and transplanted to a location between the otocyst and the hind-brain. The progress toward metamorphosis which all exhibit has been due to the activity of the transplant. The animals shown in figure 2 (RS-35-2-11) and figure 3 (RS-35-8-6) also have been maintained in an approximately normal dark pigmentary condition. Those shown in figure 4 (RS-35-10-4) and figure 5 (RS-35-8-5) are silvery. × 1.1.

6 Transverse section through the head of a specimen of R. sylvatica (RS-35-10-3) showing location of the hypophyseal transplant between the hind-brain and the cartilage of the skull floor. On each side of the brain the acoustic ganglion and the internal ear are seen. × 20.

7 Portion of a transverse section of the head of a specimen of R. sylvatica (RS-35-2-12) showing the usual location of the hypophyseal transplant between the hind-brain and the cartilage of the skull floor, near the acoustic ganglion. × 65.

8 Portion of a transverse section of the head of a specimen of R. sylvatica (RS-35-8-9) showing hypophyseal transplant nearly embedded in a depression in the cartilage of the skull floor and showing a tenuous connection with the otic ganglion. The transplant shows a larger portion which exhibits the typical cord-like structure of the anterior lobe and a more compact portion which is probably the pars intermedia. × 65.

9 Portion of transverse section from specimen RS-35-8-6 showing the hypophyseal transplant in contact with the acoustic nerve and ganglion. × 65.

10 Portion of a transverse section from specimen RS-35-6-5 showing the hypophyseal transplant completely embedded in the cartilage of the skull floor. × 65.

11 Portion of a transverse section from a specimen of R. pipiens (RP-35-4-2) in which the transplant apparently had been made into the wall of the brain. The latter shows a large evagination of the hind-brain with two portions of the transplant. × 65.

ABBREVIATIONS

ANT.L., anterior lobe of hypophysis
B.W., wall of hind-brain
G, acoustic ganglion
P.I., pars intermedia of hypophysis
TR., hypophyseal transplant

2


3

4

5

TR.
6

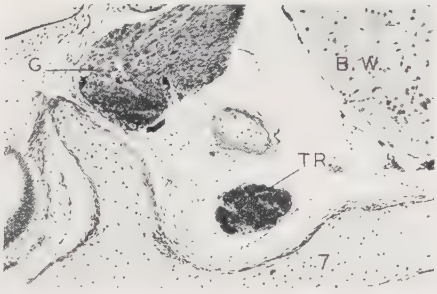
G.
B.W.
TR.
7

B.W.
P.I.
ANT. L.
8

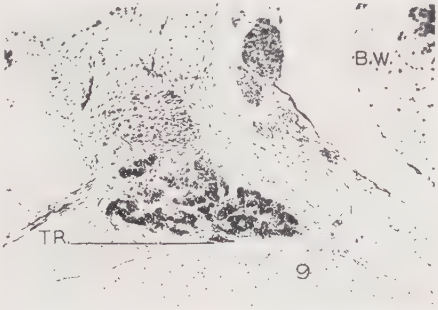
B.W.
TR.
9

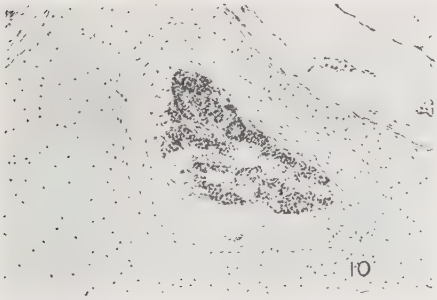
10

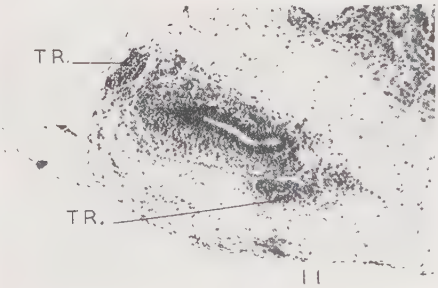
TR.
TR.
11

PLATE 2

EXPLANATION OF FIGURES

12 Portion of a transverse section through the head of a specimen of Amblystoma punctatum (AP-36-4-6) showing hypophyseal transplant and a cyst-like mass of brain tissue near the wall of the hind-brain. × 45.

13 Showing the area outlined in figure 1 at a somewhat higher magnification. × 45.

14 Thyroid glands of an animal (RS-35-8-14) upon which hypophysectomy was done and transplantation attempted. At autopsy and on study of serial sections no transplant could be found. The thyroids show the atrophy which is typical of complete hypophysectomy. × 65.

15 Thyroid glands of an animal (RS-35-8-5) which had been hypophysectomized and successfully transplanted. The thyroids have been maintained in a normal condition. × 65.

16 Largest transverse section of the adrenal glands of an animal (RS-35-8-11) hypophysectomized but without a transplant. The adrenals (which have been outlined) show the atrophy and low content of osmiophilic material which is characteristic of hypophysectomy. × 100.

17 Transverse section showing adrenal glands of an animal (RS-35-8-15) which had been hypophysectomized and successfully transplanted. The size of the glands and the content of osmiophilic material have been maintained in a normal condition. × 100.

ABBREVIATIONS

AD., adrenal glands
B.C., cyst-like mass of brain tissue
B.W., wall of hind-brain
TR., hypophyseal transplant

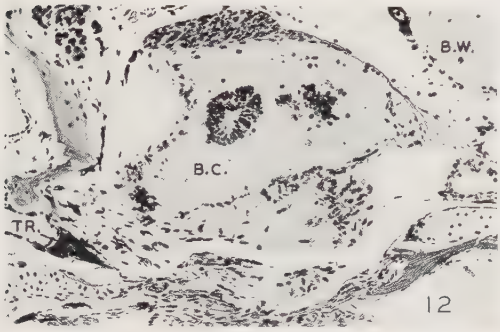

12

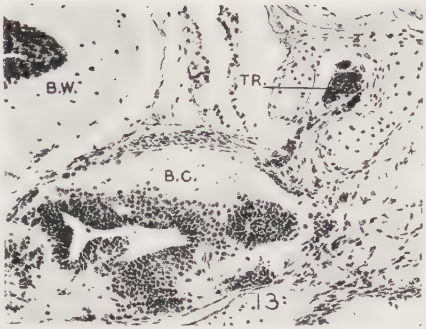

13

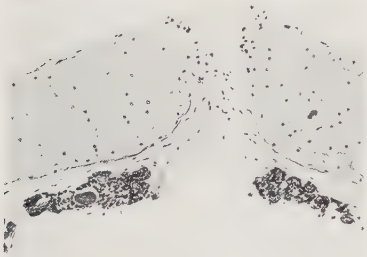
14

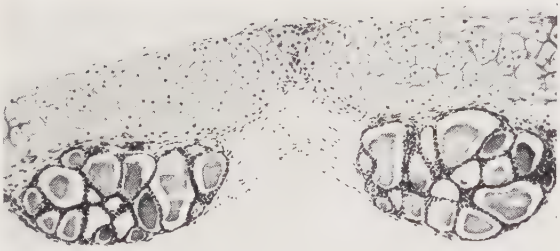
15

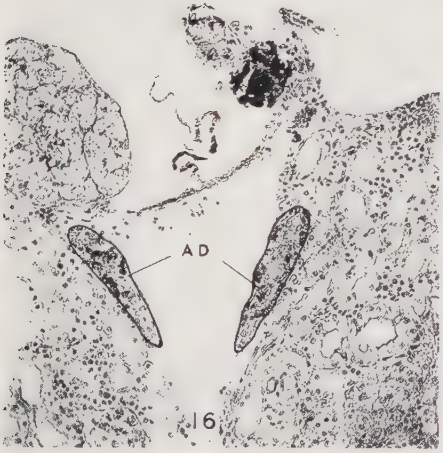

16



17

THE ORIGIN OF ENTODERMAL CELLS FROM THE PRIMITIVE STREAK OF THE CHICK EMBRYO

THOMAS E. HUNT

Department of Anatomy, University of Alabama

ONE PLATE (FOUR FIGURES)

INTRODUCTION

In the preceding paper of this series (Hunt, '37) it was shown that when the mesectoderm of the early chick embryo is grown as a graft, it has the capacity to give rise to digestive tract, whereas the mesentoderm lacks this capacity until the head-process stage. Although these experiments suggested that the definitive entoderm may originate at least partially from the ectoderm of primitive streak stages, they do not prove conclusively that this is the source of gut in normal development; therefore, it has seemed desirable to subject the inference to further investigation. If an interchange of cells between the germ layers could be demonstrated, this idea would rest on a firmer basis. To determine whether such a rearrangement occurs, the vital staining method has been employed.[1]

MATERIAL AND METHODS

The agar plate method of vital staining with Nile blue sulphate, the details of which have been adequately described by Vogt ('25), Wetzel ('29 a) and others, was employed in all experiments. Stained agar sheets were cut into pieces (0.1 to 0.3 mm. $\times$ 0.5 to 1.0 mm.) and one of these was placed for a few seconds on the exposed blastoderm 0.2 to 0.3 mm. lateral and parallel to the center of the streak. Chick blastoderms with streaks 1 to 1.5 mm. in length were used.

[1] A preliminary report of this work (Hunt, '35) was presented before the American Association of Anatomists.

The experimental procedure was modified in three ways in order to see whether any ectodermal cells become incorporated with the entoderm. In the group of experiments performed first, the blastoderm was removed from the yolk several hours after having been stained with the Nile blue sulphate and was prepared for microscopical study by methods designed to retain the dye (Adams, '28; Stone, '32). It was hoped that the distribution of the dye would be such that the migration of the cells and their descendants could be determined. Due either to faulty technique, which was not overcome, or to excessive diffusion of the dye during fixation and embedding, satisfactory preparations were not obtained. Therefore, this group of experiments will not be discussed further.

The second type of procedure was carried out with more success. Embryos were stained as before but instead of fixing the blastoderm, cross sections 0.3 to 0.5 mm. in antero-posterior width were removed from the anterior level of the streak and examined in tyrode solution. It was possible to orient the strip so that one cut surface, which usually passed through the primitive pit, could be observed with the compound microscope. A 16-mm. objective and a 10 × ocular gave a magnification sufficient to see the individual cells of all germ layers and the distribution of the dye. For illumination, light from a 100-watt projection bulb was directed so as to reflect from the surface of the tissue. Temperature of the tyrode solution was maintained at 39°C. by a thermostatically controlled warm stage.

In the third series of experiments an attempt was made to follow the actual migration of the cells. After staining the blastoderm and allowing it to incubate for an additional 2 or 3 hours, transverse sections were obtained as before; however, instead of being placed in tyrode they were oriented in a hanging drop culture medium of embryonic chick extract and adult fowl plasma. When the drop had clotted, the slide was reversed, thus bringing the cut edge of the section into view. The culture, kept at 39°C. in a warm box, was directly and continuously observed for several hours.

OBSERVATIONS

Cross sections in tyrode solution

Inasmuch as the dye sometimes penetrated to deep layers at the region of application, it was necessary to stain an area 0.2 to 0.3 mm. lateral to the streak. Ectodermal cells move medialward to the streak from such a position, as Gräper ('26) and Wetzel ('29 a) have shown; hence, it was presumed that their further distribution could be followed with the assurance that they would not be confused with cells of the other germ layers. Thus, if any stained cells appeared in the entoderm of the streak region, it would indicate that they had migrated from a superficial, lateral position and been invaginated at the streak. In order to be certain that no entodermal cells likewise moved medialward from the region originally stained, sections were examined at different intervals of time after application of the dye. The sections, which are grouped in accordance with the medial progression of the stained area, are described below.

First stage (2 to 3 hours following the application of the dye, four experiments). When the intact blastoderm was observed with the aid of a dissecting microscope, the dye was seen to have almost reached the primitive fold. After removal of the transverse strip, the distribution of the dye was determined more accurately with higher magnification. The region beneath that originally stained contained dye in the ectoderm, mesoderm and in two cases, apparently more heavily stained, in the entoderm. More medially the dye was observed in the ectodermal layer only.

Second stage (2½ to 3½ hours following application of the dye, eleven experiments). Stained cells in this group had reached the primitive fold. As before, the area originally stained showed dye in the ectoderm, mesoderm and, in some cases, the entoderm. However, there was less in the ectoderm of this region than in the ectoderm and intermediate layers of the fold where the dye was becoming more concentrated. In some strips, mesodermal cells containing stain were present in all regions between the streak and the site of application of the stain while in others there was an intervening clear

area. In three cases, stained spherules were observed in the entodermal cells of the streak region and slightly lateral to it toward the side stained. More laterally the entoderm was clear.

Third stage (4 to 6 hours after application of the dye, twenty-three experiments). Stained cells had reached the primitive groove when the sections were removed from the blastoderm. A typical example is shown in figure 3, the photograph having been made while the blastoderm was still on the yolk. It shows that the stain is quite dense in the primitive fold and diffuse more laterally on the side originally stained. In the strips it was seen that the superficial and intermediate cells of the streak and the mesoderm toward the area stained contained most of the blue spherules.

In twelve sections, the dye was observed in some entodermal cells as far lateral as the edge of the primitive fold on the side opposite to that originally stained. It is unlikely that such cells are a part of the primary entoderm, since the entoderm between these cells and those in the area originally stained remained clear. Accordingly, it seems probable that the two streams of ectodermal cells which move medialward from each side and converge at the streak not only are pushed lateralward as mesoderm in the direction from which they came but also are displaced more deeply in the streak so that some eventually take up a position in the definitive entoderm.

Cross sections in culture medium

Blastoderms were stained in the same region as described in the preceding section. The subsequent incubation period was usually long enough to allow the stained cells to reach the primitive fold but not the groove. Sections were obtained as before and were placed immediately in a drop of plasma that had been made ready while the blastoderm was being removed from the yolk. After orienting the strip in the plasma, a drop of embryonic extract was added in order to produce clotting. Eight series of ten to twelve cultures each were prepared. Of these, several were obtained in which the

cut surface of all germ layers could be plainly seen with the microscope. Although a high dry objective could be used, a 16-mm. objective with a 10 × ocular was found to be more satisfactory.

To observe the course of movement of a cell or its descendants, one with a well-stained spherule was located in the area of proliferation of the streak.[2] Subsequently, this cell could be followed for as much as 5 hours provided the dye did not disappear. In most cases the cell passed into the mesoderm, while in others it either was buried deeply in the substance of the streak where it was no longer visible or was lost as the dye faded from view. However, in three cases cells containing a stained spherule were incorporated in the entoderm.

In each instance, the cell under observation moved slowly toward the entoderm, eventually becoming a part of it. During a subsequent 30-minute period of observation it was displaced lateralward for a short distance but did not separate from the entodermal layer. The change in position seemed to be due to displacements by the increasing number of other cells and not to motility of the stained cell. Cellular movement was not only lateralward and ventralward but also in a third direction, i.e., outward through the cut surface. With the piling up of cells in such a position it eventually became impossible to see the entoderm distinctly and as a result the culture became unsuitable for observation after a period of 4 or 5 hours.

[2] Since the interpretation of the culture experiments rests on the assumption that the displacements of cells in these isolated strips are the same as in the intact blastoderm, it is apparent that these observations can only support the evidence presented in the preceding section and do not in themselves afford final proof of the problem.

DISCUSSION

The results of the staining experiments[3] indicate that some of the superficial cells of the primitive streak are incorporated in the entoderm. Since it has not been demonstrated that these cells actually become a part of the digestive epithelium, it might be argued that there is a later reassortment in which such cells return to the mesoderm. There is no evidence to indicate that such a sequence of events takes place. Furthermore, when the present observations are considered in conjunction with those of the preceding paper, the evidence points rather convincingly to the idea that gut arises from the ectoderm in normal development. This infers that the primary entoderm is not the only source of digestive tract epithelium, but that some of the latter—perhaps all, judging from the failure of the early entoderm to differentiate gut in the grafts—arises by invagination at the streak.

It does not seem illogical to suggest that the definitive entoderm of birds is formed by invagination of a region corresponding to the amphibian blastopore of which the streak is certainly a homologue. Wetzel ('31), who has discussed the similarity of the blastopore and the primitive streak, believes that part of the entoderm forms from the streak and that at least the roof of the gut tube entoderm arises from the node. Although his experimental proof ('29 b) is not entirely convincing, the idea is worthy of note. According to Waddington ('32), the induction by the roof of the archenteron of Amphibia "corresponds more nearly to the induction by the mesoderm arising from the primitive streak in the birds," whereas the induction by the early entoderm brings about the form-building movements which lead to the development of

[3] The reliability of the vital staining method in following the presumptive fate of cells is discussed by Wetzel ('29 a) in some detail. Two observations may be added to support his conclusions. First, the dye can be seen to stop abruptly at the groove of the primitive streak after movement from a lateral to a medial position (fig. 3). If diffusion occurs to any great extent, it seems likely that it would continue in the ectoderm past the mid-line. Secondly, in the cultures the stain is often seen to be held by the cells for as much as 5 hours and to remain unchanged after several cell divisions.

the streak. Hence, it seems probable that the products of the streak are similar physiologically to the products of the blastopore and that both provide cells for definitive gut entoderm.

A study of normal embryos does not preclude the possibility that definitive gut entoderm comes from the streak. Although many textbooks of embryology have illustrations that show the entoderm as a discrete, simple, flat epithelium, the representation is incorrect. Hertwig ('01) presented the true picture by stating, "that for a certain distance underneath the primitive groove the middle germ layer is as little to be distinguished as a separate structure from the lower as it is from the upper germ layer." Thus, the relationship of mesoderm and entoderm is more than one of simple contact. There is such a complete fusion and blending that no boundary is discernible (fig. 4) and only an arbitrary separation between them can be made. Furthermore, the cells of the two layers are often identical in appearance and frequently they seem to form a syncytium similar in character to the mesenchyma of the later embryo. Consequently, it would be plausible to assume, without resorting to experimental methods, that a movement of cells might occur from one layer to the other. In fact, Streeter ('27) in discussing the development of the mesoblast and notochord in pig embryos has stated that, "Hensen's node, as with the chorda derived from it, immediately blends with the entoderm—there is clearly some interchange occurring between the two." However, it is impossible to determine from a study of sections of fixed embryos the direction in which such an interchange occurs. The vital staining method has afforded a new approach to the problem and the evidence at hand points to the conclusion that there not only is an interchange of cells but that this interchange, insofar as has been determined, occurs from mesoderm to entoderm.

SUMMARY

1. By means of Nile blue sulphate applied by the agar plate method the distribution of cells from the superficial to the deep layers of the early chick embryo was followed.

2. After staining a limited region lateral to the primitive streak and allowing incubation to proceed, sections of the area pellucida of the living blastoderm were examined microscopically either in tyrode solution or in a culture medium.

3. Examination of the germ layers in the tyrode solution showed that superficially and laterally placed cells of the ectoderm were distributed to the area of proliferation of the streak, to the mesoderm lateral to it and to the entoderm. In general, the mesodermal and entodermal cells that contained dye were on the side originally stained, but in some instances a few were on the opposite side. Ectoderm of the opposite side contained none.

4. Continuous observation for 4 or 5 hours of sections in a culture medium showed that superficial cells containing stain were sometimes displaced to a deep position in the streak region and occasionally entered the entoderm.

LITERATURE CITED

Adams, A. E. 1928 Paraffin sections of tissue supravitally stained. Science, vol. 68, p. 303.

Gräper, L. 1926 Die frühe Entwicklung des Hühnchens nach Kinoaufnahmen des lebendan Embryo. Verh. d. Anat. Ges. Freiburg., S. 54.

Hertwig, O. 1901 Textbook of the Embryology of Man and Mammals. English translation of the 3rd edition by E. L. Mark. Macmillan Co., New York.

Hunt, T. E. 1935 The possible origin of entoderm from the ectoderm-mesoderm of the chick embryo as shown by vital dye experiments. Anat. Rec., vol. 61, no. 4, Suppl., p. 26.

——— 1937 The development of gut and its derivatives from the mesectoderm and mesentoderm of early chick blastoderms. Anat. Rec., vol. 68, p. 349.

Stone, L. S. 1932 Selective staining of the neural crest and its preservation for microscopic study. Anat. Rec., vol. 51, p. 267.

Streeter, G. L. 1927 Development of the mesoblast and notochord in pig embryos. Contrib. to Embryol., Carnegie Inst., Wash., vol. 19, no. 380, p. 73.

VOGT, W. 1925 Gestaltungsanalyse am Amphibienkeim mit ortlicher Vitalfärbung. Arch. f. Entwick. d. Org., Bd. 106, S. 542.

WADDINGTON, C. H. 1932 Experiments on the development of chick and duck embryos cultivated in vitro. Phil. Trans. Roy. Soc., B, vol. 221, p. 179.

WETZEL, R. 1929 a Untersuchungen am Hühnchen. Die Entwicklung des Keims während der ersten beiden Bruttage. Arch. f. Entwick. d. Org., Bd. 119, S. 188.

——— 1929 b Neue Experimente zur Frühentwicklung des Huhnes. Verh. d. Anat. Ges., Tübingen, S. 76.

——— 1931 Urmund und Primitivstreifen. Erg. d. Anat. u. Entwick., Bd. 29, S. 1.

PLATE 1

EXPLANATION OF FIGURES

1 Blastoderm with streak 1.5 mm. in length with stain 0.2 mm. lateral to the center of the streak. × 6.4.

2 Same blastoderm $2\frac{1}{2}$ hours later with the stain at the primitive fold. × 7.2.

3 Same blastoderm 6 hours after application of the stain. The stain is concentrated at the streak and sharply delimited to the left in the primitive groove. × 7.2.

4 Section through the anterior end of a primitive streak 1.5 mm. in length to show the similarity of mesodermal and entodermal cells and the absence of any barrier between the germ layers. × 360.



1

2

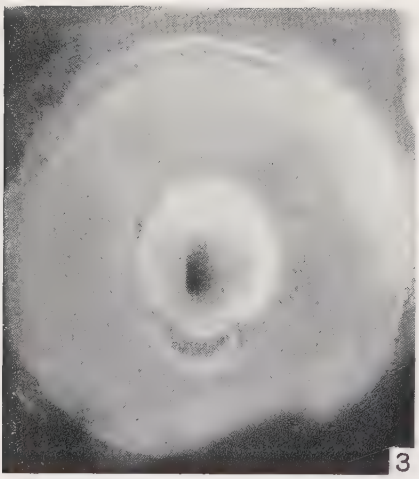

3

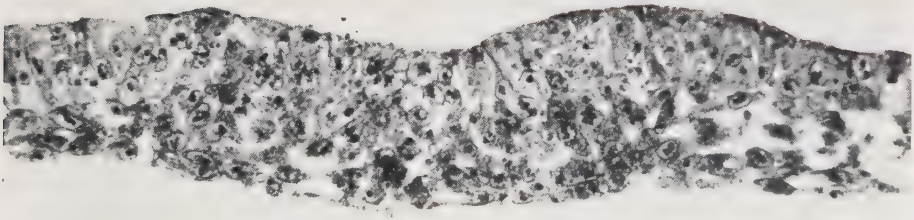

4

PIGMENT CELLS IN HETEROGENOUS FEATHERS[1]

C. H. DANFORTH
Department of Anatomy, Stanford University

TWO FIGURES

There are at least three respects in which the occurrence of graft hybrids in feathers is of interest. 1) By bringing into juxtaposition cells of different genotypes the mosaic feathers might be expected to give some indication as to whether or not genes produce substances that can cross cell boundaries to be effective on the protoplasm of adjacent cells. 2) Cells of the same histological type but with recognizable genetic differences should afford a clue to cellular distributions in the organogenesis of successive feathers. 3) The behavior of tissues known to contain different genotypes may furnish a base of reference for instances of suspected non-disjunction or altered hormonal responses. Since these three aspects of the matter are closely interrelated they may be considered together.

The appearance of occasional mosaic feathers following skin transplantation between birds of different genotypes has been reported in earlier papers (Danforth, '29, '35) in which, however, the histological picture was not considered. It may be recalled that these mosaics are obtained by exchanging pieces of skin between newly hatched chicks that are genetically different in color. If the transplants are sewed in place with the cut margins of host and grafted tissues closely approximated, there sometimes appear along the line of union a few feathers which reveal color characters of both donor and host. The follicles from which these feathers grow produce similar, but usually not identical, mosaics following

[1] With assistance from the Rockefeller Fluid Research Fund of Stanford University School of Medicine.

natural or induced moults. In one specimen the output of several such follicles was observed over a period of 5 years.

Two successive feathers from the same follicle are shown in figure 1. These represent mosaic combinations of the breeds called Buff Leghorn and Jersey Black Giant. Figure 2 is from transverse sections through the papilla of a developing feather which, had it been allowed to grow, would have been similar to those shown in figure 1. In sections of such papillae at the stage indicated and earlier, there are

Fig. 1 Two feathers which were produced in succession by the same follicle, located at the margin of a piece of Buff Leghorn skin transplanted to a Jersey Black Giant host.

found two distinct types of branched pigment cells, with no intergradations between them. One, characteristic of the Jersey Black Giant, contains pigment granules which are rod-shaped, very dark brown, and little if at all soluble in ordinary fixing and preserving fluids. The other, characteristic of the Buff Leghorn, has pigment granules that are smaller, more nearly spherical, light yellow, and somewhat soluble. The latter property often causes these yellow granules to agglutinate at fixation and appear blurred in ordinary mounts.

In the anlagen of mosaic feathers each chromatophore is clearly and unequivocably of one or the other type in respect to its pigment granules and no intermediate, or different, forms have been observed, even when two contrasted cells were in close proximity or in actual contact. Nevertheless, the two kinds of granules are often found mixed together in single epidermal cells of future barbs and barbules (fig. 2, C and D), indicating that two different chromatophores may

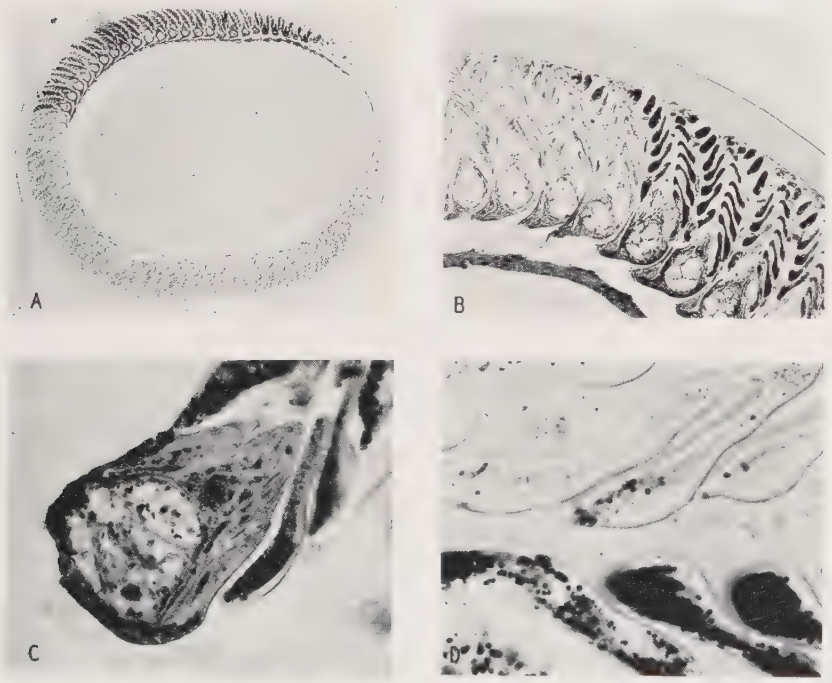

Fig. 2 Sections of a developing mosaic feather, from unstained preparations. A, cross section near the middle of the shaft. The pigmentation is yellow below and mixed black and yellow above. B, a series of barbs in the region of transition from pure yellow to mixed pigmentation. C, cross section of a barb in the medulla of which may be seen indication of cell boundaries, a number of rod-shaped black pigment granules, and some blurred yellow pigment. D, parts of several barbules in which both black and yellow granules are present in the same cells. In this section the black granules are oriented with their long axes perpendicular to the plane of section. Their transverse diameter is greater than that of the less distinct yellow granules. Approximate magnification: × 32, × 120, × 435, × 700.

feed their products into the same recipient cell. No bi-pigmented cells were found except where both kinds of chromatophores were present within a range to have supplied the respective granules. To this extent there seems to be no indication of any influence of the genes of one cell upon the reaction of another, but it does sometimes happen that after black pigment granules have been transferred to an epidermal cell and oriented in their definitive position with long axes parallel to the surface some of them appear to be shorter, and possibly lighter in color, than those in the parent chromatophore. The appearance of granules of varying length and in moniliform arrangement might suggest both a secondary multiplication of pigment particles and a possible influence of the new cytoplasmic environment. Whether or not the transferred granules—which might now be considered as foreign bodies within the ectodermal cells—are actually affected by a new and different cytoplasm can probably be answered only by direct observations on living cells. No effect of the differences in genotype has been detected at any earlier stage in the histogenesis of these mosaic feathers, and even at this final stage the existence of such an effect is doubtful.

The developing mosaic feathers contain chromatophores each of which may be presumed to be homozygous for one or the other of two sets of genes. By crossing birds of these two genotypes it is possible to bring both chromosomal sets together in the same chromatophore. To this end Black Minorcas (which have the same kind of black as the Giants) were crossed with Buff Leghorns. Chromatophores of the hybrid feathers differ from those of the graft mosaics in showing a range of intermediate forms. In this respect the hybrids correspond in their pigmentophores to the Japanese quail described by Kawamura ('33). In the hybrid, as in the quail, each individual melanophore seems to produce but one type of granule. These may be black rods, much like those of the homozygous black, shorter elliptical forms which are brown in color, or nearly spherical granules which are brownish yellow simulating, but not matching, those of homozygous

yellows. Macroscopically, feathers that are genetically hybrid are black, or black marked with reddish brown or bay, but not yellow, while the graft mosaics show black and yellow, but no bay. This in itself indicates that if there is any modification of black pigment in genetically yellow cells, it is too slight or too infrequent to become macroscopically apparent.

There is as yet no obvious reason why in the hybrid some chromatophores should produce one kind of pigment granules and others a different kind. Genic and cytoplasmic factors both suggest themselves. Simple non-disjunction, or suppression of one allel, seems to be ruled out by the fact that genetic hybrids do not behave as do graft hybrids, which should serve as controls since the same genes are involved and definitely segregated in different cells. The possibility of varying degrees of incomplete dominance is less easily eliminated and may figure in the final interpretation.

Certain variations in 'endocrine tension,' such as different concentrations of theelin, are shown by both histological methods and gross manifestations to result in a sudden and marked shift in the ratio between different types of chromatophores in the hybrids but, as might have been expected, not in the homozygotes where the potentiality of each strain is limited to only a single kind. Fixed sections do not reveal whether the hormones act selectively on developing chromatophores whose potentialities have already been determined or regulate the direction in which most of the undifferentiated ones will specialize. The promptness and completeness with which color responses are elicited rather suggests the latter, but evidence on this point is still inconclusive.

In contrast to the endocrine regulation of pattern, which is transient in its effects, is another phenomenon of rather frequent occurrence in hybrids. This is the appearance of feathers which combine, in mosaic, the two parental phenotypes. An apparently analogous situation also occurs in some homozygotes when a hyperstatic trait fails to appear in part or all of a feather. A considerable number of such feathers have been examined in this study and many of them were found to

show a close parallel to graft hybrids, which they also resemble in being repeatedly produced, with variations, by the same follicle. Montalenti ('34) has especially emphasized this point. Serebrovsky ('25) considered them to be due to non-disjunction of chromosomes while Fraps and Juhn ('36) have sought a more direct cytoplasmic causation.

Whatever their real origin, both these and graft mosaics throw an interesting light on the process of histogenesis of feathers. Since mosaic feathers are repeatedly produced by the same follicle, which is generally surrounded by others that never produce any mosaics, it would seem to follow that a residuum of undifferentiated, but predetermined, chromatophores is carried over in the base of the follicle from one cycle to the next and, since successive mosaics often vary somewhat in pattern, there must be a certain latitude in the distribution of chromatophores during organization of successive anlagen. This aspect of feather organogenesis might not have been suspected in the absence of such mosaics, particularly in view of the general emphasis on well-known hormonal effects. It may be added that mosaics produced by the same follicle are for the most part essentially alike, but with occasional striking contrasts, as when a follicle representing a Plymouth Rock-Rhode Island Red graft hybrid produced an otherwise typical Plymouth Rock feather with a red tip, followed by a similar one with a red base.

From the parallelism between graft hybrid mosaics and certain of the genetic hybrid mosaics it seems probable that the two are in effect the same, but whether the latter are due to non-disjunction, to local and persistent alteration in dominance, or to an unsuspectedly early predetermination of potentialities, remains uncertain. That the graft hybrids themselves are indeed such, and not merely chance mosaics of the other types is shown, as pointed out in the earlier papers, by the fact that the critical cases combine colors that would not occur in natural mosaics or 'break-down' patterns of either donor or host and, moreover, appear only at the junction of graft and host tissues. They are best explained by

following Champy's ('35) views on the distribution of the precursors of pigment cells along vascular channels, on the basis of which the follicle of a mosaic feather may be presumed to be composed for the most part of cells of a single genotype, but with chromatophores that are of two types. In the spontaneous mosaics of genetic hybrids it is possible that other classes of cells may also be of different types. The cause of spontaneous mosaics may be a precocious and irreversible differentiation in some of the chromatophore mother cells rather than, as normally, in the chromatophores themselves.

In conclusion, no evidence was found that in pigmentogenesis genes of one cell have any direct effect on the cytoplasm of other cells. The range of color in hybrids is due primarily to contrasted tendencies of endogenous factors within the future chromatophores and secondarily to exogenous factors, among which may be included certain hormones. Rather late in development of each feather the exogenous factors fix irreversibly the subsequent reactions at a point somewhere within the limits set by the opposing genes. Presumably the established strains which have modifiable plumage owe this peculiarity to the presence of interacting genes which are not allelomorphic and therefore capable of establishing a balance in the homozygous condition. From a study of graft hybrids having two types of chromatophores both with potentialities predetermined by endogenous factors, it is apparent that there is considerable variation in the relative number of cells of contrasted types contributing to the organogenesis of the morphologically similar feathers successively produced by a single follicle.

LITERATURE CITED

CHAMPY, CH. 1935 Recherches sur l'action des glandes génitales sur le plumage des oiseaux. Arch. d'Anat. micr., T. 31, pp. 145–270.

DANFORTH, C. H. 1929 The effect of foreign skin on feather pattern in the common fowl (Gallus domesticus). Arch. Entwicklungsmech., Bd. 116, S. 242–252.

——— 1935 Genetic mosaics in feathers of the common fowl. Trans. Dynam. Develop., vol. 10, pp. 339–344.

FRAPS, RICHARD M. AND MARY JUHN 1936 Developmental analysis of plumage. III. Field functions in the breast tracts. Physiol. Zoöl., vol. 9, pp. 378–406.

KAWAMURA, T. 1933 Über die Pigmentbildung in der Erstlingsfeder von Coturnix coturnix japonica Temminck et Schlegel. J. Sci. Hiroshima Univ., ser. B, div. 1, vol. 2, pp. 171–191.

MONTALENTI, G. 1934 A physiological analysis of the barred pattern in Plymouth Rock feathers. J. Exp. Zoöl., vol. 69, pp. 269–345.

SEREBROVSKY, A. S. 1925 'Somatic segregation' in domestic fowl. J. Genetics, vol. 16, pp. 33–34

THE WEIGHTS AND LINEAR MEASUREMENTS OF THE DIGESTIVE SYSTEM OF THE ADULT CAT

HOMER B. LATIMER
Department of Anatomy, University of Kansas

Since the publication of the studies on the prenatal growth of the digestive tube (Latimer, '34 a) and the liver and pancreas (Latimer, '34 b), similar measurements have been made upon a series of adult cats and this paper will present this additional data on the digestive system of the adult cat. The data will include the average weights and lengths of the digestive system and of its parts, their variability and the sex differences in weights and lengths. Next the correlations between the weights and the lengths of the digestive system and of its parts and the body weight and the body length will be presented and lastly, the relative proportions of the digestive system and of its parts in the adult cat will be compared with the same proportions at the beginning of the fetal period and at the end of the fetal period or in the newborn. Unfortunately there are no data on the changes taking place in postnatal life but this will at least give some idea of the total change in postnatal as well as in the prenatal life of the cat.

MATERIALS AND METHODS

This study is based upon the measurements of the digestive system of 104 adult cats, equally divided as to sex. The only requirements in collecting the cats were that they must be apparently healthy and mature. The details of the methods used have been given in an earlier paper (Latimer, '36).

The term 'digestive tube' in this paper will mean the esophagus, stomach, small and large intestine, and the term 'digestive system' will include in addition to the above, or the digestive tube, the two major glands; the liver and the pancreas. In dissecting these cats, the digestive tube was removed from its pharyngeal opening to its termination at the anus. The entire tube was carefully separated from its mesenteries and, with the contents still enclosed, its entire length was measured with a steel tape graduated in millimeters The tube was held vertically by an assistant with its only support at the upper end of the esophagus. Then the stomach was separated from the esophagus and the small intestine at the constrictions of the cardiac and pyloric sphincters, respectively. The small intestine was cut close to its entrance into the large intestine. Thus there was a rather definite landmark for making each of the incisions separating the tube into its parts. The lengths of each of the divisions of the tube, with the exception of the stomach, were then measured with the steel tape before the contents were removed.

The stomach was opened by a longitudinal incision and the contents removed. The upper end of the esophagus was held in one hand and the thumb and fore finger of the other hand was passed slowly but rather firmly along the length of the esophagus thus removing any contents which might be within. The esophagus usually contained nothing but a little mucus. The same procedure was followed in removing the contents of the small, and the large intestines. The divisions of the digestive tube were kept in a moist chamber until weighed in glass stoppered weighing bottles. The sum of the weights of the empty divisions of the digestive tube was taken as the weight of the empty digestive tube. The liver and pancreas were dissected out and freed of all mesenteries and blood vessels. Their ducts were cut close to the gland. The gall bladder and contents were weighed with the liver. All weights were made on a chemical balance sensitive to $\frac{1}{10}$ mg. and all of the lengths made with the steel tape to the nearest millimeter.

The formulae used in computing the various statistical values are those given by Dunn ('29). In all the computations the figures were carried to more decimal places than are given in the tables and all of the computations were checked.

I wish to express my gratitude to Dr. Evert Larson and to Dr. Frank C. Melone who assisted with the dissections and to Miss Ethel J. Melone who assisted in working up the data.

PONDERAL AND LINEAR MEASUREMENTS

Table 1 gives the average weights and lengths and the coefficients of variability of the digestive system and of its parts for both the male and female cats. The average coefficient of variation for the weights of the digestive tube and its parts is 2.83% greater in the females, but the liver and pancreas, average 20.5% more in the males. The lengths are less variable, especially the length of the esophagus and the length of the entire digestive tube. The length of the large intestine is the most variable part in both sexes. The average of the coefficients is slightly greater (1.86%) in the females.

Welcker and Brandt ('03) give the weights of the digestive tube, liver and pancreas from three male and seven female cats. They find an average of 4.71% for the weight of the digestive tube in three females and one male, but the one male had the lowest percentage weight. The percentage weights for the pancreas are lighter than in my series, being 0.15% for two males and 0.22% for four females. They find both pancreas and liver relatively lighter in the males as they are in this series. They give percentage weights of 3.43 for the male livers and 4.16 for the females.

Table 1, especially the linear dimensions, would appear to favor the theory of compensatory variability more than the data presented in the earlier paper (Latimer, '36) on the external measurements of the cat. There is still the probability of a greater variability of the segments due to methods of dissecting, the elimination of error in the sum of the individual measurements, and also the inherent variability in

each part, which has its own specific task in the process of digestion.

The last column in table 1, giving the significant ratios, or the difference between the averages in the male and the female divided by the probable error of the difference, shows that all

TABLE 1

Weights and lengths of the digestive system and of its parts

	FIFTY-TWO MALE CATS		FIFTY-TWO FEMALE CATS		Difference / P.E. difference
	Average weight	Coefficient of variation	Average weight	Coefficient of variation	
	gm.		*gm.*		
Esophagus weight	5.90 ± 0.11	20.50 ± 1.41	5.32 ± 0.09	17.36 ± 1.18	4.06
Stomach weight	23.01 ± 0.43	19.96 ± 1.37	21.17 ± 0.40	20.27 ± 1.40	3.14
Small intestine weight	81.65 ± 1.59	20.77 ± 1.43	74.87 ± 1.61	22.99 ± 1.60	3.00
Large intestine weight	20.58 ± 0.37	19.35 ± 1.33	19.11 ± 0.40	22.12 ± 1.53	2.72
Digestive tube weight	131.15 ± 2.32	18.94 ± 1.30	120.47 ± 2.21	19.60 ± 1.35	3.33
Liver weight	101.50 ± 2.20	23.15 ± 1.61	88.61 ± 1.58	19.09 ± 1.31	4.76
Pancreas weight	6.75 ± 0.16	25.68 ± 1.81	6.52 ± 0.13	21.42 ± 1.48	1.08
	Average length		Average length		
	mm.		*mm.*		
Esophagus length	190.98 ± 1.66	9.31 ± 0.62	189.12 ± 1.48	8.30 ± 0.56	0.84
Small intestine length	1439.00 ± 14.00	10.40 ± 0.70	1332.17 ± 16.05	12.76 ± 0.87	5.02
Large intestine length	264.98 ± 5.20	20.98 ± 1.45	250.57 ± 4.50	19.00 ± 1.32	2.10
Digestive tube length	2031.15 ± 15.63	8.23 ± 0.55	1924.59 ± 17.59	9.77 ± 0.65	4.53

of the weights except that of the large intestine and pancreas are significantly heavier in the males. It is interesting to note that the pancreas with the largest coefficient of variability has the lowest significant ratio of any of the weights. Only two lengths, or the small intestine and the digestive tube are significantly longer in the male. The small intestine forms

about 70% of the total length of the digestive tube (table 3) and has a significant ratio of 5.02, hence the ratio for the entire digestive tube is naturally significant. Jackson ('33) reports no sex difference in the length of the human small intestine.

In general, the weights of the male liver and pancreas are much more variable than any of the other weights or lengths. The digestive tube and its parts are slightly more variable in average weight and length in the females. Of the parts of the tube, the small intestine is most variable in its weight in both sexes, and the female esophagus and male large intestine are the least variable. All of the weights except that of the large intestine and the pancreas are significantly heavier in the males. Only two of the lengths, small intestine and total length of the tube, are significantly greater in the males. The lengths of the large intestine are the most variable of the linear dimensions in both sexes and the female esophagus and the length of the entire tube in the male are the least variable.

CORRELATIONS

The correlations between the weight and length of the body and the weights and lengths of the digestive system and of its parts are given in parts A and B of table 2. As is to be expected all of these correlations are positive although some are so low that they are not significant. All of the weights correlated with body weight, with the exception of the pancreas, are higher in the males. The averages of these correlations are + 0.67 for the males and + 0.55 for the females. All of the linear measurements correlated with body weight, with the exception of the length of the large intestine are higher in the females but the average of these four correlations is slightly greater in the males, due to the very low correlation of the large intestine length and body weight in the females. The averages are respectively, + 0.38 and + 0.35.

Part B of table 2 gives the correlations between the same measurements and the body length. The first seven, or the weights correlated against body length, are a little lower than

the same weights correlated with body weight. The average for the males is + 0.59 and for the females, + 0.50%. In this group all of the male correlations are again higher than the females except the pancreas and esophagus. The lower division of part B of this table gives an average correlation of + 0.39 for the linear dimensions correlated with body

TABLE 2

	MALE CATS	FEMALE CATS
A. Correlations with body weight		
Digestive tube weight	+ 0.734 ± 0.043	+ 0.507 ± 0.070
Esophagus weight	+ 0.710 ± 0.046	+ 0.603 ± 0.059
Stomach weight	+ 0.694 ± 0.048	+ 0.463 ± 0.073
Small intestine weight	+ 0.670 ± 0.052	+ 0.455 ± 0.074
Large intestine weight	+ 0.686 ± 0.049	+ 0.563 ± 0.064
Liver weight	+ 0.662 ± 0.053	+ 0.591 ± 0.061
Pancreas weight	+ 0.498 ± 0.070	+ 0.660 ± 0.053
Digestive tube length	+ 0.429 ± 0.076	+ 0.459 ± 0.074
Esophagus length	+ 0.319 ± 0.084	+ 0.338 ± 0.084
Small intestine length	+ 0.293 ± 0.085	+ 0.443 ± 0.076
Large intestine length	+ 0.461 ± 0.074	+ 0.166 ± 0.092
B. Correlations with body length		
Digestive tube weight	+ 0.692 ± 0.049	+ 0.477 ± 0.073
Esophagus weight	+ 0.652 ± 0.054	+ 0.696 ± 0.048
Stomach weight	+ 0.564 ± 0.064	+ 0.511 ± 0.069
Small intestine weight	+ 0.663 ± 0.052	+ 0.423 ± 0.077
Large intestine weight	+ 0.639 ± 0.055	+ 0.379 ± 0.080
Liver weight	+ 0.580 ± 0.062	+ 0.474 ± 0.073
Pancreas weight	+ 0.364 ± 0.081	+ 0.561 ± 0.064
Digestive tube length	+ 0.465 ± 0.073	+ 0.386 ± 0.080
Esophagus length	+ 0.436 ± 0.076	+ 0.524 ± 0.068
Small intestine length	+ 0.386 ± 0.080	+ 0.442 ± 0.076
Large intestine length	+ 0.266 ± 0.087	+ 0.133 ± 0.093
C. Correlations with length of the large intestine		
Esophagus length	— 0.145 ± 0.092	— 0.001 ± 0.094
Small intestine length	+ 0.153 ± 0.091	+ 0.432 ± 0.077
Digestive tube length	+ 0.322 ± 0.084	+ 0.582 ± 0.062
D. Correlations with the length of the entire digestive tube		
Esophagus length	+ 0.431 ± 0.076	+ 0.503 ± 0.071
Small intestine length	+ 0.915 ± 0.015	+ 0.936 ± 0.012
Large intestine length	+ 0.322 ± 0.084	+ 0.582 ± 0.062

length for the males and + 0.37 for the females which is slightly higher than the averages for these lengths correlated with body weight. The lengths of the digestive tube and the large intestine correlated with body length are higher in the males. The highest correlations are between body weight and the various weights; next between the body length and the same weights and the two lower groups are the correlations between the linear dimensions and body weight and body length. In all four groups, the average of the correlations is higher in the males. All of the correlations of both body length and body weight correlated with the weights in the males are above + 0.5 except the pancreas. The two lowest correlations are found in the females and both are for the length of the large intestine with body weight and body length. The correlations of the external dimensions of the cat also averaged higher in the males (Latimer, '36).

The low correlations of the length of the large intestine in both sexes with both body length and body weight, suggested that there might be some factor governing its length and the length of the other parts of the digestive tube. Hence the length of the large intestine in both sexes was correlated with the length of the other parts of the digestive tube with the results shown in part C of table 2. These correlations show that there is no significant relationship between the lengths of the large intestine and the lengths of the other parts of the digestive tube, except possibly between the large intestine and the length of the entire tube in the female. This raised the question as to the relationship of the lengths of the parts of the tube to the entire digestive tube length and so these correlations were determined, with the results given in the last part of table 2. The highest correlations found in this group, and in the entire table, are between the length of the digestive tube and the length of the small intestine, but the small intestine later on will be shown to form about 70% of the total length of the digestive tube and consequently it should have a high correlation with the total length. All of the other correlations are low and especially so in the males. Hence we

are justified in concluding that there is no constant relationship between the length of the large intestine and the lengths of the other divisions of the tube, and the length of the entire tube is not significantly correlated with either the lengths of the esophagus or the large intestine.

RELATIVE PROPORTIONS

To compare the total change in the fetal period with that in the postnatal period, the relative proportions given in table 3 have been assembled. The first column gives the averages for the earliest fetuses studied, which in all probability represent the beginning of the fetal period. The second column gives the averages for the late fetuses and newborn cats, and the last two columns give the data for the adult male and female cats. These data give no idea of the character of the changes during the periods except for the maximum for the liver which is given in brackets. The changes in these data during the fetal period have been described in the two earlier papers and will not be repeated here. So far as is known, there are no data of this sort for the postnatal growth of the cat. The percentages for the fetal period are taken from the earlier papers and the data for the adult measurements from table 1. Throughout this table, the initial weight of the pancreas was taken much later than that of the other parts, for it was so small and so diffuse in the smaller specimens that it could not be removed and weighed accurately. The lengths of the fetal intestines were measured after formalin preservation, while the similar lengths of the adults were taken from the fresh material. According to Jackson ('33) there is an appreciable difference in the lengths of the fresh and the formalin hardened adult human intestines.

The weights of the pancreas and the digestive tube increase in percentage of the body weight during the fetal period but both have about reached their adult proportions by the time of birth. The liver decreases in the fetal period following an early maximum. The maximum percentage weight of the liver in the fetal period is 7.3% (shown in parentheses) and it is

TABLE 3

Changes in relative weights and lengths of the digestive system and of its parts in the early fetus, late fetus or newborn and in the adult male and female

	EARLY FETUS	LATE FETUS	ADULTS	
			Male	Female
Digestive tube weight as per cent of body weight	1.0	5.1	4.65	4.95
Liver weight as per cent of body weight	5.2 (7.3)	3.8	3.60	3.62
Pancreas weight as per cent of body weight	0.10[1]	0.24	0.239	0.267
Grams per centimeter of body length:				
Digestive tube	0.0014	0.456	2.52	2.38
Liver	0.0120	0.403	1.95	1.74
Pancreas	0.0011[1]	0.024	0.130	0.128
Esophagus weight as per cent of weight of digestive tube	15.0	4.3	4.50	4.42
Stomach weight as per cent of weight of digestive tube	52.5	15.0	17.54	17.57
Small intestine weight as per cent of weight of digestive tube	20.5	63.0	62.26	62.15
Large intestine weight as per cent of weight of digestive tube	12.0	18.0	15.69	15.86
Digestive tube weight as per cent of weight of digestive system	18.0	53.5	54.78	55.88
Liver weight as per cent of weight of digestive system	82.0	44.0	42.40	41.10
Pancreas weight as per cent of weight of digestive system	1.2[1]	3.0	2.82	3.02
Digestive tube length times body length	0.53	3.75	3.90	3.78
Esophagus length as per cent of length of digestive tube	33.0	9.5	9.40	9.83
Small intestine length as per cent of length of digestive tube	32.0	75.0	70.85	69.22
Large intestine length as per cent of length of digestive tube	21.0	13.0	13.05	13.02

[1] Pancreas was not weighed until a body weight of 8 gm. or a body length of 80 mm. was attained.

found at a body weight of about 8 gm. The cat liver is relatively a little heavier at all periods, except birth, than the human liver (Scammon, '33). The weights of the digestive tube, liver and pancreas compared to the weight of the entire digestive system, undergo the same relative changes as do these parts compared to the body weight. The weights of the digestive tube, the liver and the pancreas compared to the body length (second group, table 3) all become relatively heavier per unit of body length in both the prenatal and the postnatal periods. The weights of the four parts of the digestive tube compared to the weight of the entire tube show the most marked changes in the prenatal period with only slight changes in the relative weights of the stomach, and the large intestine in the postnatal period. The maximum percentage weight of the large intestine is found at birth and this is due, doubtless to the accumulation of meconium during the latter part of the fetal period, as has been suggested by Scammon ('33) for the human large intestine. During the prenatal period the esophagus and the stomach decrease and the other two parts increase in their percentages of the weight of the entire tube.

The last section of this table gives similar data for the lengths of the parts of the digestive tube as percentages of the total length of the digestive tube. The length of the stomach was not measured. The esophagus decreases not only in relative weight but also in relative length in the fetal period. The adult proportions in both weight and length of the esophagus are approximately attained by the time of birth. Both intestines increase in relative weight during the fetal period, but only the small intestine increases in relative length. The length of the large intestine relative to the length of the entire tube changes but little in postnatal life, but the relative length of the small intestine decreases from its maximum at time of birth. The small intestine increases in the fetal period from 1.6 to 6.6 times the length of the large intestine. This ratio drops to 5.4 in the adult male. The large intestine is relatively short in the cat, as suggested by Mitchell ('16) for all carnivores. In the adult cat it forms 13% of the total

length of the digestive tube compared to 20% in man. In the smallest fetuses the digestive tube was almost a straight tube from pharynx to anus, while the body length, measured along the mid-dorsal line, was a very markedly curved line connecting nearly the same two points and hence the length of the digestive tube was only about half the body length. This increases during the fetal period to 3.75 times the noseanus length and but slightly more in the postnatal period, with the ratio 12% greater in the adult male.

In general, the esophagus is relatively a much heavier and longer part of the digestive tube in the early fetal stage. The large intestine is likewise relatively longest in the early fetus, but its maximum percentage weight is found at birth. The most marked increase in percentage weight and in percentage length is found in the small intestine. The liver decreases in percentage of the body weight from a maximum in the early fetal period. The entire digestive tube weight rises to its maximum percentage at birth and decreases slightly thereafter. The pancreas has attained practically its adult relative weight by the time of birth.

SUMMARY

The esophagus is significantly heavier in the male but there is no sex difference in the length. The weights form significant correlations with both body weight and body length. Its relative weight and length decrease in the prenatal period and remain practically constant after birth.

The stomach is significantly heavier in the males. The only significant correlation is with the male body weight. It decreases in relative weight to a minimum at birth with a slight rise in the mature cats.

The small intestine is significantly heavier and longer in the male cats. Its weight is better correlated with both the body weight and body length in the males. The length is better correlated in the females, but the correlations are not significant. It increases in relative weight and length up to birth, with a very slight decrease in relative length in the mature cats.

Only the weight of the male large intestine is significantly correlated with body weight and body length. The relative weight of the large intestine rises to its maximum at birth and then decreases slightly in the adult. The relative length decreases in the prenatal period and then remains constant.

The entire digestive tube is significantly heavier and longer in the males. The only significant correlations are its weight with body weight and body length in the male cats. It increases in relative weight and length in the prenatal period. Following birth it decreases slightly in weight but increases slightly in relative length.

The liver is significantly heavier and is better correlated with body weight and body length in the males. It increases in relative weight to its maximum in early fetal life and then decreases to birth, with slightly lower percentages in the adult.

The pancreas shows no sex difference in weight and its only significant correlation is with the body weight in the female. It increases in relative weight during the prenatal period and at birth it has attained its relative adult size.

LITERATURE CITED

Dunn, Halbert L. 1929 Application of statistical methods in physiology. Physiol. Revs., vol. 9, pp. 275–398.

Jackson, C. M. 1933 Chapter on the digestive system. Morris' Human Anatomy.

Latimer, H. B. 1934 a The prenatal growth of the cat. IV. Growth in length and weight of the digestive tube. Anat. Rec., vol. 60, pp. 23–41.

——— 1934 b The prenatal growth of the cat. V. The ponderal growth of the liver and pancreas. Scritti Biologici, vol. 9, pp. 313–322.

——— 1936 Weights and linear measurements of the adult cat. Am. J. Anat., vol. 58, pp. 329–347.

Mitchell, P. Chalmers 1916 Further observations on the intestinal tract of mammals. Proc. Zool. Soc. London, pp. 183–251.

Scammon, R. E. 1933 Chapter on developmental anatomy. Morris' Human Anatomy.

Welcker, Hermann and Alexander Brandt 1903 Gewichtswerthe der Körperorgane bei dem Menschen und den Thieren. Arch. f. Anthropol., Bd. 28, S. 1–89.

THE EFFECT OF PROGESTIN ON THE GROWTH RESPONSE OF THE UTERUS TO CHRONIC DISTENTION [1]

SAMUEL R. M. REYNOLDS [2] AND WILLARD M. ALLEN

Department of Physiology, Long Island College of Medicine, Brooklyn, New York, and Department of Obstetrics and Gynecology, University of Rochester School of Medicine and Dentistry, Rochester, New York

TWO FIGURES

The form of the uterine growth curve resulting from chronic uterine distention in untreated, ovariectomized rabbits provides a means by which the effects of oestrin and progestin on uterine growth attributable to distention may be measured with exactness (Reynolds and Kaminester, '36). Oestrin has been found to reduce the distention-growth response, probably owing to the heightened tonicity of the myometrium and the consequent effects of this upon the local vascularity of the tissues about the pellets (Reynolds, '37).

The present report deals with the effects of progestin in suitable ovariectomized rabbits in which paraffin pellets of known size were inserted per vaginam into the uterus for a period of 2 weeks. The experiments involved comparison of the size of the chronically distended parts with the size of the undistended, untouched parts of the same uterus. The degree of growth, related to the degree of distention in each case, furnished the data with which the distention-growth curve of the uterus in progestin-treated rabbits was obtained.

[1] Aided by a grant from the Committee for Research in Problems of Sex, National Research Council. Acknowledgment to that Committee is gratefully made.

[2] Fellow of the John Simon Guggenheim Memroial Foundation.

PROCEDURES

Paraffin pellets were inserted into the uterus per vaginam in rabbits ovariectomized for 1 week. At the same time, 200 rat units of oestradiol were given subcutaneously. Two days later, daily injections of progestin were commenced. A total of 6.6 rb.u. was given in the next 10 days. On the thirteenth day of uterine distention, tissues were taken, prepared and studied in the manner described before (Reynolds and Kaminester, '36). The dosage of progestin used was about liminal for maintenance of endometrial proliferation for a period of 10 days (Allen and Heckel, '36).

Two groups of rabbits were used. One consisted of seven rabbits in which thirteen different distention sites were available for study. This group was characterized by the fact that they were all mature, non-pregnant rabbits having hyperemic uteri and large ovaries bearing macroscopic and usually bulging graafian follicles. The other group consisted of nine rabbits from which fourteen distention sites were available. These rabbits were immature, and possessed flat ovaries without macroscopic follicles, and had infantile uteri. In addition, two recently pregnant rabbits and one recently pseudopregnant rabbit were used.

The distention ratios (the determination of which has been discussed before, Reynolds and Kaminester, '36) in this work varied from 2.89 at one extreme to 0.26 at the other. This means that an undistended portion of a uterus at one extreme had a diameter nearly three times that of the distending pellet, and at the other, an undistended uterus had a diameter about one-fourth that of the distending pellet. Figures 1 and 2 show the amount of growth at each distention site related to the degree of distention in each case, in mature and immature rabbits, respectively.

RESULTS

Mature rabbits. In this group of rabbits, chronic uterine distention in the presence of progestin regularly elicited growth of the uterus. Minimum growth was observed (curve A, fig. 1) when the uterus to pellet ratio was 1.34, or that point where the diameter of the undistended portion of uterine tissue exceeded the diameter of the distending pellet by about 34%. At the other extreme of the curve a point of no growth was approached when the diameter of the pellet was about

four times that of the non-distended uterus. Optimal growth responses were obtained as the distention ratio approached a 1:2 uterus to pellet ratio.

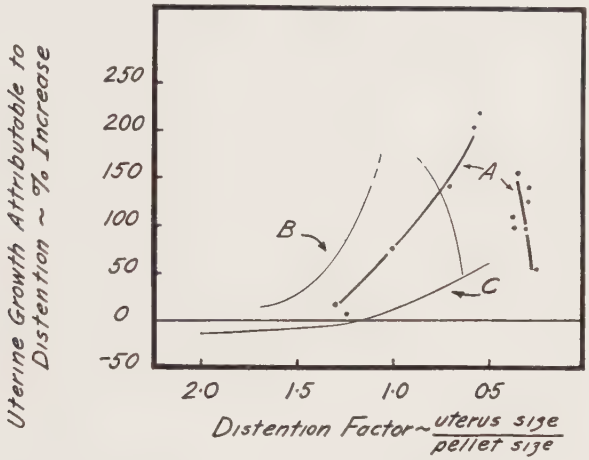

Fig. 1 Curves showing the amount of uterine growth attributable to distention for a period of 2 weeks. A, mature rabbits treated with 6.6 rb.u. of progestin; B, untreated, ovariectomized rabbits; C, rabbits treated with oestrin for 2 weeks prior to insertion of the pellets. Distention ratios indicate increasing degrees of stretching from left to right.

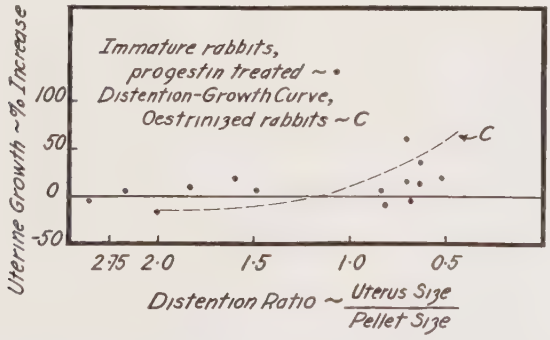

Fig. 2 Uterine growth attributable to distention in immature rabbits treated with 6.6 rb.u. of progestin during 2 weeks of distention. Curve C, the distention-growth curve of oestrinized rabbits. See figure 1.

The characteristics of this curve may be compared in figure 1 with those of the distention-growth curve in untreated, ovariectomized rabbits (curve B). The contours of the two curves are similar, and on the basis of the few data presented cannot be said to be of significantly different characters. The limits of the two curves are very dissimilar, however. In curve B, the optimum distention ratio is at a uterus to pellet ratio of about 1:1, in contrast to the 1:2 ratio as the point of optimum growth in progestin-treated rabbits. The extremes of the two curves, insofar as they go, show a similar relationship to each other. In curve A, therefore, the distention growth curve is shifted to the right, signifying that greater degrees of distention (i.e., stimulation) are required to do what lesser degrees do in untreated, ovariectomized rabbits. Clearly, increase in the length of the tissues by distention does not evoke a larger growth response. Nevertheless, some condition requiring increased length of the tissues in mature progestin-treated rabbits is essential to elicit degrees of growth comparable to those obtained by less distention in untreated rabbits; thus, progestin serves to raise the threshold for the growth response to chronic uterine distention.

Endometrial and myometrial growth. In each of the cases in the group of mature rabbits, both the endometrium and the myometrium contributed to the local enlargement of the tissues which took place about the pellets. Moreover, the percentage increase of the two tissues paralleled each other although the myometrium tended to show a distinctly greater percentage increase than did the endometrium, particularly with the larger degrees of distention. This is indicated in table 1.

The failure of the endometrium to grow as much as the myometrium in progestin-treated rabbits differs from the situation observed in untreated, ovariectomized rabbits, described before (Reynolds and Kaminester, '36) in which a closer parallelism exists between the percentage increases of the parallelism exists between the percentage increases of the endometrium and myometrium throughout the whole of curve B.

Although the histological features of these tissues will not be described, mention should be made of one of the structural features. In all the rabbits studied (immature as well as mature) typical and marked endometrial proliferation occurred, with the exception of two rabbits in each of which two distention sites were available for study. These two rabbits yielded the greatest growth responses (204.8% and 219.0%) of all the distention experiments thus far carried out. One of the two rabbits showed little endometrial proliferation and the other, an intermediate degree of prolifera-

TABLE 1

DISTENTION RATIO	ENDOMETRIUM	MYOMETRIUM
	per cent increase	*per cent increase*
1.30	10.2	18.2
1.24	4.4	6.7
1.09	76.9	75.5
0.71	83.2	163.0
0.63	75.4	256.5
0.60	87.0	321.0
0.38	26.3	200.4
0.37	15.3	147.0
0.36	271.2	142.8
0.31	17.7	179.5
0.30	64.3	163.0
0.28	353.2	40.0
0.26	42.8	68.0

tion of the secretory epithelium. The nuclei were pyknotic. In these two instances, therefore, the amount of progestin was inadequate to maintain the endometrium in as well developed a state as in the other tissues in which the amount and rate of growth were less pronounced. The data do not show whether or not the liminal doses of progestin used were in any way a limiting factor in the distention-growth responses obtained in this work.

Immature rabbits. The responses to chronic uterine distention in this group of rabbits stand in marked contrast to those of the former group. At none of the distention ratios studied (fig. 2) was a growth response attributable to disten-

tion obtained comparable to the responses indicated by curves A and B in figure 1; rather, the growth responses resembled those obtained in oestrin-treated rabbits (Reynolds, '37). This is clear when the positions of these points are compared with the distention-growth curve for oestrinized rabbits, shown by curve C in figures 1 and 2.

In addition to the distribution of these points about the oestrin curve, the responses obtained in these immature rabbits resembled those obtained in oestrinized rabbits in another respect. The endometrium at the distention sites was found

TABLE 2

DISTENTION RATIO	ENDOMETRIUM	MYOMETRIUM
	per cent of undistended site	*per cent of undistended site*
2.89	— 4.6	1.4
2.69	— 4.6	19.0
2.15	—24.8	— 6.1
1.85	— 1.3	21.6
1.61	25.3	18.9
1.49	50.8	0.0
0.82	—15.7	29.7
0.79	—31.4	9.8
0.71	—21.7	58.0
0.71	31.8	87.7
0.68	—16.8	11.7
0.66	— 6.9	57.5
0.66	6.2	21.1
0.52	— 2.2	45.2

to be smaller in size than it was in undistended areas of the same uteri. In contrast, the myometrium usually showed growth. This is indicated in table 2.

These data show that the reduced growth response in immature rabbits is partly attributable to a decrease in size of the endometrium, sufficient in some instances to offset appreciably the growth which takes place in the myometrium. Even so, the growth of the myometrium is not great when compared to that found at certain distention ratios in curves A and B of figure 1; instead, it is comparable in extent to the distention-growth responses of the myometrium in oestrinized rab-

bits. Histological examination of these tissues shows that the endometria were proliferated to about the same degree as the tissues obtained in the mature rabbits described above. Thus, the effectiveness of the progestin in the two groups was approximately the same as regards the endometrial proliferation response but not as regards the growth response of the uterus to distention. The present results show, therefore, that the distention-growth response in immature rabbits treated with progestin is not entirely inhibited although it is reduced by factors which seem to operate also in oestrinized rabbits. These factors have been discussed before (Reynolds, '37).

The data from the two pregnant rabbits and the one pseudopregnant rabbit may be noted in passing. One of these, about 4 weeks pregnant at the time of ovariectomy, showed marked growth of the endometrium and myometrium as a result of distention. The responses at both distention sites fall along curve A of figure 1. The second rabbit, 10 days pseudopregnant at the time of ovariectomy, showed no appreciable growth of the uterus at the distention sites, and is classed with the immature rabbits on the basis of the distention-growth response obtained. The third rabbit, about 10 days pregnant at the time of ovariectomy, gave one response that may be classed with those obtained in mature, non-pregnant rabbits and one response at a second distention site that is classed with the responses obtained in immature rabbits. At the time the pellets were inserted the macerated fetuses were still in place undergoing lysis and absorption. The data from these three rabbits are too few to allow conclusions to be drawn, although they do suggest that the immediately previous reproductive history of the animals may affect the growth capacity of the chronically distended uterus under the influence of progestin.

DISCUSSION

Only a word need be said in discussion of the results described in this paper. Figure 1 shows that progestin (administered to mature rabbits) does not significantly augment the

growth capacity of the uterus when it is chronically distended; rather, it raises the threshold of the tissues to the stimulus of distention. Since progestin has the property of reducing myometrial tonicity, it seems plausible to conclude that the action of progestin is to reduce the tension of the tissues about the pellets to such an extent that greater degrees of stretching are required to produce a degree of tension comparable to that obtained by less distention in untreated, ovariectomized rabbits.

In striking contrast to both curves A and B of figure 1 is curve C, the growth curve of the distended uterus in oestrinized rabbits. The conclusion has been drawn before that this curve is best explained on the basis of the augmenting action which oestrin has upon the tonicity of the myometrium, and the consequent adverse effects of this upon the local circulation at the site of uterine distention (Reynolds, '37).

It seems clear, therefore, from the foregoing considerations that a pellet, in order to be an adequate stimulus for uterine growth must produce an appropriate increase in intrauterine tension, but not to such an extent that impairment of the augmented nutritive requirements of the tissues takes place. Such an explanation may also be used to account for the sharp drop at the right of both curves A and B of figure 1. In each of the experiments upon the data of which these parts of curves A and B are based, the uterus was stretched initially nearly to the limits of its distensibility.

LITERATURE CITED

Allen, W. M. and G. P. Heckel 1936 The effect of continued injections of progestin and combinations of oestrin and progestin on the endometrium of the castrated rabbit. Anat. Rec., vol. 64, suppl. 3, p. 2.

Reynolds, S. R. M. 1937 Chronic uterine distention in oestrin-treated rabbits. Proc. Soc. Exp. Biol. and Med., vol. 36. (In press.)

Reynolds, S. R. M. and S. Kaminester 1936 Distention, a stimulus for uterine growth in untreated, ovariectomized rabbits. Am. J. Physiol., vol. 116, pp. 510–515.

TABLES FOR THE NORMAL DEVELOPMENT OF RANA SYLVATICA

ARTHUR W. POLLISTER AND JOHN A. MOORE
Department of Zoölogy, Columbia University

INTRODUCTION

To any student of anuran embryology it is probably unnecessary to point out the need for a description of a series of normal stages in the development. The usefulness of such data is shown by the frequency of references to the widely known, though unpublished, series of Amblystoma punctatum by Harrison. The need for a similar 'common language' for anuran development has been keenly felt in this laboratory and in others for some time, and the present study is an attempt to meet this demand.

It has been found most useful to define all stages in the series by at least two characteristics: the external morphology and the age at a constant temperature (hours after fertilization at 18°C.). The changes in external form are relatively simple up to the beginning of the growth of the tail. Accordingly no additional data, beyond age and form, are needed on stages 1 to 17, which comprise the successive phenomena of cleavage, gastrulation and neurula formation. In the later period of embryology, however, there are many simultaneous processes that are readily identifiable externally. The most obvious are the following: growth of tail; elongation of the body; growth of external gills, development of operculum; development of transparency of epidermis; coiling of gut. Furthermore, there are physiological features of development that appear as the embryo approaches larval condition, e.g., beginning of muscular movement and of swimming ability, onset of heart beat, of gill circulation, and of tail fin circula-

tion, and spontaneous hatching of the embryo. There are interspecific differences in the time of occurrence of these various features of later development. For example, the operculum is nearly completed in a Rana pipiens embryo which, as classified by other features, is at a stage when it is just beginning to grow backward over the gills in Rana sylvatica. Because of such differences one cannot describe a series of stages for even these two species of Rana, which will be strictly alike in every one of the features mentioned above. Hence it has been found more widely useful to define each of stages 18 to 23 by a group of characteristics.

The total length of the embryo is widely used as an exclusive basis for definition of stages in later development of Anura. In wide practice this is not very reliable because of variability of egg size, both intraspecifically and interspecifically. A much more useful criterion, likewise based on measurements, is the ratio of tail length (measured from the anus) to the length of the remainder of the embryo, the body. Data on total length are, nevertheless, included in the tables. They are based on measurements of eggs of approximately average size.

The study has been made partly from eggs collected in nature and partly from those artificially fertilized after ovulation had been induced by pituitary administration. There are no differences in the development of eggs obtained by the two methods. In the vicinity of New York, Rana sylvatica usually lays its eggs about the middle of March in water at a temperature of about 11°. In the laboratory eggs will develop normally at from 2 to 22°. At the lower limit development is extremely slow, yet when eggs are removed to higher temperatures they develop normally in every respect. This unusual tolerance of such a low temperature is of practical advantage in that one can place eggs collected in the field in heat-insulated containers with ice cubes and thus bring the embryos to the laboratory in very nearly the stage in which they were collected. Data on the time for development at different temperatures between stages 3 and 20 are given

in table 4. Such data are very accurately reproducible for the early stages, but from stage 18 onward differences between embryos become increasingly significant. The total elapsed time for development to stage 23 may vary as much as 10% among embryos from a single batch of eggs.

DESCRIPTION OF STAGES[1]

Stages 1 to 17 (table 1)

1. Egg at fertilization.
2. Establishment of gray crescent area as first external evidence of development, sharply defined at 1 hour.

3 to 6. Age given is time of appearance of cleavage furrow that establishes the number of cells drawn for the stage.

7 to 9. Later stages in cell multiplication, best determined by comparison of size of cells at vegetal pole.

10. Appearance of dorsal lip.
11. Blastopore approximately a semicircle.
12. Complete blastopore (yolk-plug) stage.
13. Slit blastopore or neural plate stage.
14. Neural fold stage.
15. Beginning of closure of neural folds, beginning of elongation. Cilia begin to rotate the embryo at about this stage.
16. Closure of neural folds completed.
17. Beginning of development of tail bud, marked off from body by ventral notch when embryo is viewed laterally.

Stages 18 to 23 (tables 2 and 3)

The figures are ventral and lateral views of all but stage 22, which shows dorsal instead of ventral aspect.

18. Stage begins with development of capacity for muscular movement, i.e., simple unilateral flexure in response to mechanical stimulation. This is very suddenly acquired and is closely correlated with attainment of the external form figured.

[1] The stages illustrated and defined by age are of course essentially an arbitrary series of readily identifiable points in the continuous process of development. Defined in terms of these points, the total development is comprised in a series of periods, each extending from one stage until the next. In practice the points and the periods are not sharply distinguished and it is convenient to describe each period in terms of the stage that initiates it. Thus the development from onset of the heart beat to the beginning of gill circulation would be the period of stage 19.

19. Time given indicates onset of heart beat which appears very suddenly and is accordingly a most useful marker for this stage. (Use of strong reflected light is necessary for identification of this early pulse.) Tail equals one-third the length of the body.

20. Beginning of circulation of blood corpuscles through a capillary loop of anterior gill is closely correlated with gill morphology, and is the best indication of the beginning of this stage. Shaking will hatch embryos early in this stage; they hatch spontaneously late in 20. Swimming ability is acquired in the latter part of this stage. Tail equals one-half the body length.

TABLE 4

Hours from first cleavage required to reach various stages at different temperatures

STAGE	10.4°C.	15.4°C.	18.5°C.
3	0	0	0
4	2+	1.3	1.0
5	5	2.2	2.0
6		3.0+	3.0
7	11	4.7	3.5
8	24	14.0	9.5
9	36	19.5	13.5
10	45	24.0	16.5
11	60	32.0	21.0
12	72	37.0	25.0
13	96	52.0	33.0
14	112	56.0	37.0
15	124	63.0	42.0
16	141	72.0	47.0
17	168	83.0	55.0
18	180	90.0	62.0
19	216	108.0	72.0
20	275	130.0	87.0

21. Cornea becoming transparent so lens is visible as light spot. Body and tail nearly equal in length.

22. Development of posterior bend in gut makes trunk appear asymmetrical from dorsal aspect. A few capillary loops are functional in the tail fin. Epidermis rapidly becoming transparent.

23. Trunk and head have rounded out and embryo assumes true larval or 'tadpole' shape. Horny larval teeth developed. Posterior limb bud identifiable. Opercular fold beginning to develop. Active spontaneous swimming begins.

TABLE 1

ST. NO.	AGE HRS. 18°	EXTERNAL FORM	ST. NO.	AGE HRS. 18°	EXTERNAL FORM	ST. NO.	AGE HRS. 18°	EXTERNAL FORM
1	0		7	6		13	36	
2	1		8	12		14	40	
3	2.5		9	16		15	45	
4	3+		10	19		16	50	
5	4.5		11	24		17	58	
6	5+		12	28				

TABLE 2

ST. NO.	AGE HRS 18°	length mm.	EXTERNAL FORM
18	65	5	MUSCULAR MOVEMENT
19	75	6	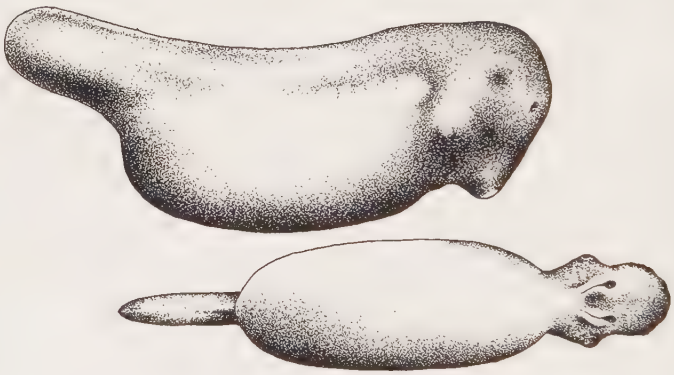 HEART BEAT
20	90	7	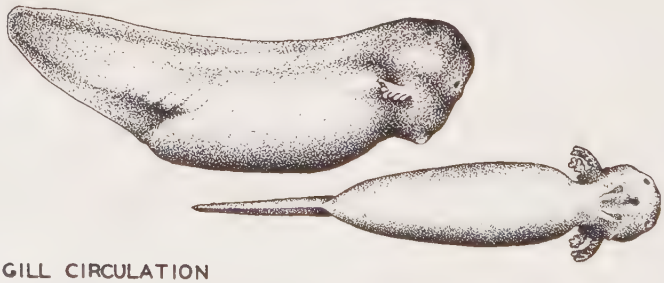 GILL CIRCULATION SWIMMING — HATCHING

TABLE 3

ST. NO.	AGE HRS 18°	length mm.	EXTERNAL FORM
21	112	8	CORNEA TRANSPARENT
22	142	10	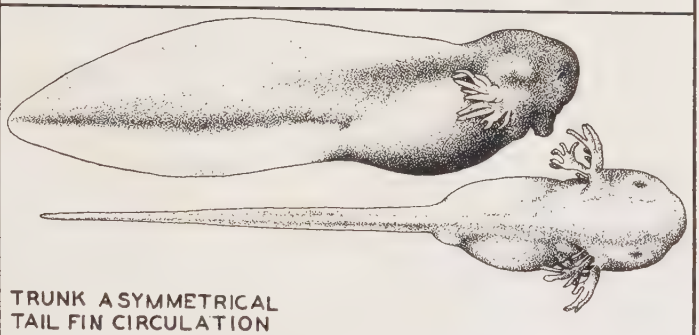 TRUNK ASYMMETRICAL TAIL FIN CIRCULATION
23	164	11	TADPOLE FORM TEETH LIMB BUD

Internal anatomy

It has been found useful to have some means of readily identifying sectioned material in terms of the series of stages described above. There are, of course, no difficulties in doing this with embryos up to the time of closure of the neural folds

TABLE 5

STAGE NUMBER	NUMBER OF SOMITES	EYE	EAR	STAGE NUMBER	NUMBER OF SOMITES	EYE	EAR
16	6			19	20		
17	12			20			
18	18			21			

(stage 15). For recognition of stages 16 to 21 table 5 was constructed. The number of somites was counted from frontal or sagittal sections. The development of the eye and ear, as seen in cross sections, are shown by the series of drawings made at a common magnification by a projection method.

COMPARISON AND RATE OF TESTICULAR DEGENERATION IN RATS AFTER CRYPTORCHIDISM AND HYPOPHYSECTOMY [1]

SAMUEL L. LEONARD AND JAMES B. HAMILTON

Biology Department and Departments of Physiology and Anatomy, Albany Medical College, Union University, Schenectady and Albany

ONE FIGURE

It is known that in mammals whose testes are normally residual in a scrotal sac, degeneration of the testes occurs when they are maintained in the abdomen or at a temperature equal to or higher than the normal body temperature (see Moore, '32, for a discussion of the literature). Degeneration of the testes also follows removal of the hypophysis, and the gonads assume an abdominal position which is said to be "the result rather than the cause of the atrophy" (Smith, '30). The present experiments were designed to determine the comparative rate of testicular degeneration in rats after hypophysectomy and cryptorchidism.

METHODS

Sixty-two male rats of 70 to 120 gm. were divided into groups of twenty-five hypophysectomized and thirty-seven non-hypophysectomized animals. In all rats, one testis was placed in the abdominal cavity and was prevented from returning to the scrotum by partial closure of the inguinal canal with a ligature; the other testis was maintained in the scrotum by ligating the right inguinal canal so that the testis could not be forced into the abdomen even with gentle pressure. In all animals, care was taken not to interfere with the blood

[1] Aided by a grant from the Rockefeller Foundation and a fund supplied by Dr. George Walker.

supply of the testes or to constrict the vas deferens. In the hypophysectomized group the narrowing of the inguinal canals was performed at the time of hypophysectomy.

The animals were killed at intervals from 3 to 60 days, each testis weighed separately and prepared for microscopic study. Partially hypophysectomized rats and those whose testes were damaged by pressure or surrounded by oedematous tissue were not included in the data. The percentage difference in weight of the scrotal and cryptorchid testes was plotted against various postoperative intervals. Thus it was possible to determine 1) the effect of cryptorchidism as compared to hypophysectomy, 2) the additive effects of cryptorchidism in hypophysectomy, and 3) whether or not cryptorchidism normally plays a part in the post-hypophysectomy rate of degeneration of the testes. To determine the last point, four rats were hypophysectomized and one testis was confined to the scrotum, the other testis left free for post-hypophysectomy withdrawal from the scrotum.

RESULTS

Figure 1 summarizes the rate of degeneration of the testis in normal and hypophysectomized rats expressed as percentage difference in weight between the scrotal and cryptorchid testes.

Normal rats. In this group the destructive action of the higher body temperature resulted in damage to the abdominal testes while the control testes in the scrota remained unchanged. The rate of degeneration of the cryptorchid testes increased rapidly until reaching a plateau at about 10 days. The graph indicates the percentage difference up to 25 days only. At 60 days the average differences in three rats was 63%.

The variation in the percentage differences which occurred among different animals at any autopsy date was about 10%, which was thought to be partially related to the position of the cryptorchid testes in the abdomen. Those which were close to the body wall exhibited a smaller degree of degenera-

tion, probably correlated with the lower body temperature of the body wall (Hamilton, '37).

With the progressive decrease in size of the cryptorchid testes, there occurred corresponding degenerative histological changes in the abdominal testes such as have been previously described. In agreement with previous work (Heller, '29), it was found that motility of the sperm in the epididymis decreased with the duration of the cryptorchid state.

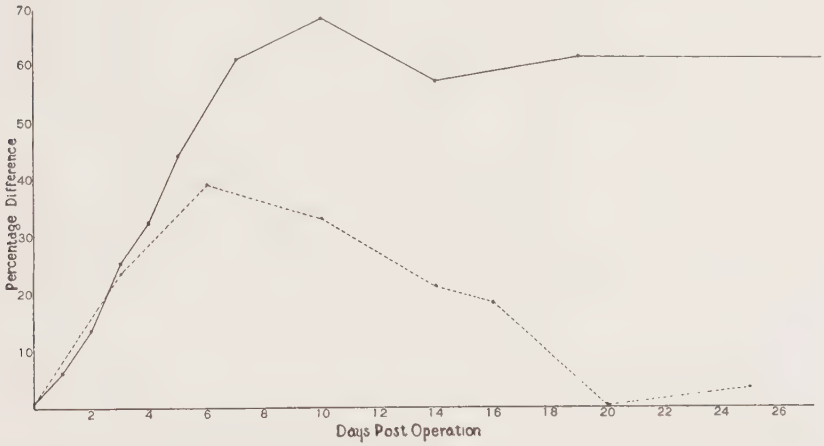

Fig. 1 Rate of testicular degeneration of scrotal versus abdominal testes of normal and hypophysectomized rats, expressed as percentage differences in weight. ———, normal rats. – – – –, hypophysectomized rats. Each point represents the average result of two or more rats.

Hypophysectomized rats. In this group the rate of degeneration of scrotal and cryptorchid testes paralleled that of the normal rats for about 6 days, after which the degeneration of the scrotal testes began to approach that of the cryptorchid testes and thereafter the percentage difference decreased. When older rats were used, the initial testicular weight was greater and the percentage difference higher. The slope of the curve was similar, however.

The degenerative changes as indicated by testicular weights were confirmed by microscopic examination. The occurrence of cellular debris in the lumina of the tubules, the decrease in the size of the tubules and the thinning of the germinal epi-

thelium coincided with the weight changes. Microscopically, scrotal and abdominal testes were practically indistinguishable on the twentieth day and could be differentiated only with difficulty on the sixteenth day.

The four hypophysectomized rats, each with one testis confined to the scrotum and the other left free to move about, were autopsied 8 days after the operation. It was previously noted that the greatest difference between the abdominal and scrotal testes occurred about this time. The differences in weight between the testes confined permanently to the scrotum and those freely movable (control) expressed as a percentage were 0, 3, — 8 and 14.6%. Three normal littermates, in which one testis was also scrotally confined, the other left untouched, differed by — 7, 2.5 and — 1%.

DISCUSSION

These results show the remarkable rapidity with which cryptorchidism causes degeneration of the testes in the normal rat, reaching a peak in about 10 days. From 10 to 60 days the weight difference in percent between the scrotal and abdominal testes remains fairly constant.

In the hypophysectomized rats of the weight used the greatest difference between the abdominal and the scrotal testes occurs at about 6 days; the difference between the abdominal and scrotal testes later decreases as post-hypophysectomy atrophy of the scrotal testis approaches the degree produced earlier in the other testis by cryptorchidism. The cryptorchid testis shows an effect as great at 10 days as the scrotal testis at 20 days. This demonstrates that cryptorchidism can augment the rate of degeneration beyond that which follows hypophysectomy alone.

The percentage difference between the abdominal and scrotal testes in normal and hypophysectomized rats of this weight is the same for the first 3 days (fig. 1). After 3 days, the curve for the hypophysectomized rats differs from that of the normal rats, which signifies that degenerative changes in the scrotal testes result in a lower percentage difference at succeeding days.

The movement of the testes into the abdominal cavity in the rat, following hypophysectomy has been reported by Smith ('30). However, this cryptorchid condition does not seem to contribute greatly to the post-hypophysectomy degeneration of the testes, for 8 days after removal of the hypophysis there was no significant difference between the scrotally-retained and the freely movable testes although both testes had atrophied to half the size of those of their normal littermate controls. When these animals were kept sufficiently warm, the testes of the hypophysectomized rat were palpable in the scrotum as late as 16 days but not after 20 days.

It should be pointed out that male hormone can induce the return of the degenerate testes of the hypophysectomized rat to the scrotum without any apparent influence on their structure. The position of the testes and the condition of the scrotum are controlled by the male hormone (Hamilton, '36; Hamilton and Leonard, unpublished).

SUMMARY

1. The percentage difference in weight between the cryptorchid and scrotal testes of normal rats is shown graphically to increase rapidly to a maximum in about 10 days after which there is practically no further increase in difference (up to 60 days). In hypophysectomized rats the difference between the scrotal and the abdominal testes is pronounced at about 6 days, later decreasing as the post-hypophysectomy atrophy of the scrotal testis approaches the degree produced earlier in the other testis by cryptorchidism.

2. The cryptorchid testis in the hypophysectomized rat atrophies more rapidly than the scrotal testis. Since in the hypophysectomized rat, however, the movement of the testes into the abdominal cavity follows rather than produces the post-hypophysectomy degeneration of the testicle, it appears that cryptorchidism does not play a large part in post-hypophysectomy atrophy.

LITERATURE CITED

HAMILTON, J. B. 1936 Endocrine control of the scrotum and a 'sexual skin' in the male rat. Proc. Soc. Exp. Biol. and Med., vol. 35, p. 386.

——— 1937 Visceral temperatures in the intact and unanaesthetized animal. J. Lab. and Clin. Med., vol. 22, p. 466.

HAMILTON, J. B. AND S. L. LEONARD Unpublished data.

HELLER, R. E. 1929 New evidence for the function of the scrotum. Physiol. Zoöl., vol. 2, p. 9.

MOORE, C. R. 1932 Sex and Internal Secretions. Edited by E. Allen. The Williams and Wilkins Company, Baltimore.

SMITH, P. E. 1930 Hypophysectomy and a replacement therapy. Am. J. Anat., vol. 45, p. 205.

INDEX

ALIMENTARY canal of urodele larvae, changes in the, associated with an excess or absence of hypophyseal tissue 169
ALLEN, WILLARD M. See Reynolds, Samuel R. M. 481
AMERICAN ASSOCIATION OF ANATOMISTS. Fifty-third session. Proceedings, officers and list of members . . . . . Sup. 1
Amphibia. Functional transplants of the primordium of the epithelial hypophysis in 431
Ampulla of Vater and sphincter of Oddi. The origin of, in the human fetus 17, 193
ANDREWS, FREDERIC N. See Phillips, Ralph W. 127
Ascorbic acid. Histological study of renal elimination of 113
ATWELL, WAYNE J. Functional transplants of the primordium of the epithelial hypophysis in Amphibia 431

BAST, T. H. The utriculo-endolymphatic valve and duct and its relation to the endolymphatic and saccular ducts in man and guinea pig 75
Bile duct in the human fetus. The development of the common . . 17, 193
BLOUNT, RAYMOND F See Schofield, Norman D. 169
Bone marrow of the turkey. Relation of lymphoid nodules to blood production in the 253
BOYDEN, E. A. See Schwegler, R. A., Jr. 17, 193
Brain of a human cyclopian monster. Description of 411
BREMER, J. L. Two reconstructions explaining the development of the veins of the liver 165

CAT. The weights and linear measurements of the digestive system of the adult 469
Chick blastoderms. The development of gut and its derivatives from the mesectoderm and mesentoderm of early 349
Chick embryo. The functional differentiation of the hepatic cells of the 393
Chick embryo. The origin of entodermal cells from the primitive streak of the 449
CLAUSEN, FRED W See Freudenberger, Clay B. 133
CORBIN, KENDALL B., AND ERNEST D. GARDNER. Decrease in number of myelinated fibers in human spinal roots with age 63
Cryptorchidism. Comparison and rate of testicular degeneration in rats after 497
Cyclopian monster. Description of the brain of a human 411

DALTON, A. J. The functional differentiation of the hepatic cells of the chick embryo 393
DANFORTH, C. H. Pigment cells in heterogenous feathers 461
Differential staining 267
Dog. Observations on the nature of the parafollicular cells in the thyroid gland of the 281
Dog. The development of the parathyroids in the dog 305
DONALDSON, H. H. Editorial. Milton Jay Greenman 263
DOWNEY, HALL. See Kirschbaum, A. 227

ENDOLYMPHATIC and saccular ducts in man and guinea pig. The utriculo-endolymphatic valve and duct and its relation to 75
Endometrial and myometrial changes including fibromyomatous nodules, induced in the uterus of the guinea pig by the prolonged administration of oestrogenic hormone 99
Entodermal cells from the primitive streak of the chick embryo. The origin of 449

FEATHERS. Pigment cells in heterogenous 461
Fetus. Monographs for estimating the age and major external dimensions of the human 221
Fetus. Morphologic comparison of the parietal and the visceral peritoneal epithelium in 327
FREUDENBERGER, CLAY B., AND FRED W. CLAUSEN. The effect of continued theelin injections on the body growth and organ weights of young female rats 133
Fundulus heteroclitus. The normal stages of 1

GARDNER, ERNEST D. See Corbin, Kendall B. 63
GARDNER, W. U. Hypertrophy of interstitial cells in the testes of mice receiving estrogenic hormones 339
GIROUD, A., AND C. P. LEBLOND. Histological study of renal elimination of ascorbic acid 113
Glisson's capsule. A definition of 383
GODWIN, MELVIN CRAWFORD. The development of the parathyroids in the dog with emphasis upon the origin of accessory glands 305
GRAFFLIN, ALLAN L. The structure of the nephron in the sculpin, Myoxocephalus octodecimspinosus 145
GRAFFLIN, ALLAN L. The structure of the nephron in fishes. Representative types of nephron encountered; the problem of homologies among the differentiated portions of the proximal convoluted segment 287
Greenman, Milton Jay. Editorial . . . 263

Guinea pig Endometrial and myometrial changes including fibromyomatous nodules, induced in the uterus of the 99
Guinea pig The structure of the secreting and retrogressing mammary gland in the 103
Guinea pig. The utriculo-endolymphatic valve and duct and its relation to endolymphatic and saccular ducts in 75
Gut and its derivatives from the mesectoderm and mesentoderm of early chick blastoderms. The development of 349

HAMILTON, JAMES B. See Leonard, Samuel L. 497
Hemopoietic tissues. A comparison of some of the methods used in studies of 227
Hepatic cells of the chick embryo. The functional differentiation of the . . 393
HESSELBERG, CORA, AND LEO LOEB. The structure of the secreting and retrogressing mammary gland in the guinea pig 103
Hormone. Endometrial and myometrial changes including fibromyomatous nodules, induced in the uterus of the guinea pig by the prolonged administration of oestrogenic 99
Hormones. Hypertrophy of interstitial cells in the testes of mice receiving estrogenic 339
HUNT, THOMAS E. The development of gut and its derivatives from the early chick blastoderms 349
HUNT, THOMAS E. The origin of entodermal cells from the primitive streak of the chick embryo 449
Hypophyseal tissue. Changes in the alimentary canal of urodele larvae, associated with an excess or absence of 169
Hypophysectomy. Comparison and rate of testicular degeneration in rats after 497
Hypophysis. Comparative action of injections of oestrin and a combination of oestrin and anterior-like substance on the anterior 237
Hypophysis in amphibia. Functional transplants of the primordium of the epithelial 431

INTERSTITIAL cells in the testes of mice receiving estrogenic hormones. Hypertrophy of 339

JACKSON, C. M. Recovery of rats upon refeeding after prolonged suppression of growth by underfeeding 371
JORDAN, H. E. The relation of lymphoid nodules to blood production in the bone marrow of the turkey 253

KIRSCHBAUM, A., AND HAL DOWNEY. A comparison of some of the methods used in studies of hemopoietic tissues 227

LATIMER, HOMER B. The weights and linear measurements of the digestive system of the adult cat 469
LEBLOND, C. P. See Giroud, A. 113
LEONARD, OLVE L., AND SAMUEL L. LEONARD. Failure of thyroidectomy to influence the follicular components of the immature rat ovary 249
LEONARD, SAMUEL L., AND JAMES B. HAMILTON. Comparison and rate of testicular degeneration in rats after cryptorchidism and hypophysectomy 497
LEONARD, SAMUEL L. See Leonard, Olive L. 249
Liver, veins of the. Two reconstructions explaining the development of 165
LOEB, LEO. See Hesselberg, Cora 103

MACACUS rhesus. The innervation of the reproductive organs in . . . 43
Mammary gland in the guinea pig. The structure of the 103
Man. The utriculo-endolymphatic valve and duct and its relation to endolymphatic and saccular ducts in . . 75
METTLER, C. C. See Mettler, Fred A. 411
METTLER, FRED A., AND C. C. METTLER. Description of the brain of a human cyclopian monster 411
Mice receiving estrogenic hormones. Hypertrophy of interstitial cells in the testes of 339
MOORE, JOHN A. See Pollister, Arthur W. 489
Musculus proprius. The composition of the 193
Musculus proprius. The early development of the 17
Myelinated fibers in human spinal roots with age Decrease in number of 63
Myoxocephalus octodecimspinosus. The structure of the nephron in 145

NELSON, WARREN O. Endometrial and myometrial changes including fibromyomatous nodules, induced in the uterus of the guinea pig by the prolonged administration of oestrogenic hormone 99
Nephron in fishes, the structure of the 287
Nephron, structure of, in the sculpin 145
Nodules, fibromyomatous, induced in the uterus of the guinea pig . . 99
Nodules, lymphoid, relation to blood production in the bone marrow of the turkey 253

OESTRIN and a combination of oestrin and anterior pituitary-like substance on the anterior hypophysis. Comparative action of injections of 237
OPPENHEIMER, JANE M. The normal stages of Fundulus heteroclitus 1
Ovary. Failure of thyroidectomy to influence the follicular components of the immature rat 249

PARAFOLLICULAR cells in the thyroid gland of the dog. Observations on the nature of 281
Parathyroids in the dog. The development of the 305
Parietal and visceral peritoneal epithelium in fetus and adult. Morphologic comparison of the 327
Pars intestinalis of the common bile duct in the human fetus. The development of the 17, 193
PETRUNKEVITCH, ALEXANDER. On differential staining 267
PHILLIPS, RALPH W., AND FREDERIC N. ANDREWS. The speed of travel of ram spermatozoa 127
Pigment cells in heterogenous feathers 461
POLLISTER, ARTHUR W., AND JOHN A. MOORE. Tables for the normal development of Rana sylvatica 489

Primitive streak of the chick embryo. The origin of entodermal cells from the 449
Progestin, effect of, on growth response of the uterus 481
Proximal convoluted segment. Problem of homologies among the differentiated portions of the 287
PUUMALA, REINO H. Morphologic comparison of the parietal and the visceral peritoneal epithelium in fetus and adult 327

RAM spermatozoa. The speed of travel of 127
Rana sylvatica. Tables for the normal development of 489
Rat ovary. Failure of thyroidectomy to influence the follicular components of the immature 249
Rats, recovery of, upon refeeding after prolonged supression of growth by underfeeding 371
Rats. Testicular degeneration after cryptorchidism and hypopsysectomy 497
Rats. The effect of continued injections of theelin on the body growth and organ weights of 133
Renal elimination of ascorbic acid. Histological study of 113
Reproductive organs of Macacus rhesus. The innervation of 43
REYNOLDS, SAMUEL R. M., AND WILLARD M. ALLEN. The effect of progestin on the growth response of the uterus to chronic distention 481

SCAMMON, RICHARD E. Two simple monographs for estimating the age and some of the major external dimensions of the human fetus . . . 221
SCHOFIELD, NORMAN D., AND RAYMOND F. BLOUNT. Changes in the alimentary canal of urodele larvae associated with an excess or absence or hypophyseal tissue . . 169
SCHWEGLER, R. A., JR., AND E. A. BOYDEN. The development of the pars intestinalis of the common bile duct in the human fetus, with special reference to the origin of the ampulla of Vater and the sphincter of Oddi. II. The early development of the musculus proprius 17
SCHWEGLER, R. A., JR., AND E. A. BOYDEN. The development of the pars intestinalis of the common bile duct in the human fetus, with special reference to the origin of the ampulla of Vater and the sphincter of Oddi. III. The composition of the musculus proprius 193
Sculpin, the structure of the nephron in the 145
Spermatozoa. The speed of travel of ram 127
Sphincter of Oddi. The origin of, in the human fetus 17, 193
Spinal roots, with age. Decrease in number of myelinated fibers in human 63
Suprarenal glands. The innervation of 417
SWINYARD, C. A. The innervation of the suprarenal glands 417

TESTES of mice receiving estrogenic hormones. Hypertrophy of interstitial cells in the 339
Testicular degeneration in rats after cryptorchidism and hypophysectomy. Comparison and rate of 497
Theelin, the effect of continued injections, on the body growth and organ weights of rats 133
Thyroid gland of the dog. Observations on the nature of parafollicular cells in the 281
Thyroidectomy, failure of, to influence the follicular components of the immature rat ovary 249
Turkey. Relation of lymphoid nodules to blood production in the bone marrow of the 253

URETER. A case of retrocaval . . 389
Urodele larvae, changes in the alimentary canal of 169
Uterus of the guinea pig. Endometrial and myometrial changes including fibromyomatous nodules, induced in the 99
Uterus. The effect of progestin on the growth response of the 481
Utriculo-endolymphatic valve and duct and its relation to the endolymphatic and saccular ducts in man and guinea pig. The 75

VICARI, EMELIA M. Observations on the nature of the parafollicular cells in the thyroid gland of the dog 281

WHARTON, LAWRENCE R. Studies on the innervation of the reproductive organs of Macacus rhesus 43
WHITNEY, GEORGE C. A note on the definition of Glisson's capsule . . . 383
WOLFE, J. M. Comparative action of injections of oestrin and a combination of oestrin and anterior pituitary-like substance on the anterior hypophysis 237
WREN, JAMES C. A case of retrocaval ureter 389

COUNTWAY LIBRARY
HC 6DZ2

41A
857